



3 1761 06704918 9

# TUMORS OF THE CEREBRUM

CHARLES K. MILLS, M. D.

CHARLES H. FRAZIER, M. D.

WILLIAM G. SPILLER, M. D.

GEORGE E. DE SCHWEINITZ, M. D.

THEODORE H. WEISENBURG, M. D.



Presented to the Library  
OF THE

University of Toronto.


BY

*P. Charles K. Mills*

*Philadelphica*

*A. D. 1907 B.*





Digitized by the Internet Archive  
in 2007 with funding from  
Microsoft Corporation

MA  
M

TUMORS OF THE CEREBRUM

THEIR FOCAL DIAGNOSIS  
AND SURGICAL TREATMENT

BY

CHARLES K. MILLS, M.D.

CHARLES H. FRAZIER, M.D.

WILLIAM G. SPILLER, M.D.

GEORGE E. De SCHWEINITZ, M.D.

THEODORE H. WEISENBURG, M.D.

81329  

---

28/1/07

ON SALE BY  
EDWARD PENNOCK,  
3609 WOODLAND AVE., PHILA.  
1906.



TO  
WILLIAM WILLIAMS KEEN, M.D., LL.D.,  
AND  
SIR VICTOR HORSLEY, F.R.S., F.R.C.S.,  
IN RECOGNITION OF THEIR GREAT WORK  
IN CEREBRAL LOCALIZATION AND CEREBRAL SURGERY  
AND  
AS A MARK OF PERSONAL REGARD AND ESTEEM,  
THIS LITTLE BOOK IS DEDICATED  
BY  
THE AUTHORS.





## TABLE OF CONTENTS.

1. The Focal Diagnosis of Operable Tumors of the Cerebrum. By CHARLES K. MILLS, M.D.
2. Remarks Upon the Surgical Aspects of Operable Tumors of the Cerebrum. By CHARLES H. FRAZIER, M.D.
3. Cerebral Decompression. By WILLIAM G. SPILLER, M.D., and CHARLES H. FRAZIER, M.D.
4. The Ocular Symptoms of Tumor of the Cerebrum. By GEORGE E. DESCHWEINITZ, M.D.
5. Conjugate Deviation of the Eyes and Head and Disorders of the Associated Ocular Movements. By THEODORE H. WEISENBURG, M.D.
6. The Significance of Jacksonian Epilepsy in Focal Diagnosis, with Some Discussion of the Site and Nature of the Lesions and Disorders Causing This Form of Spasm. By CHARLES K. MILLS, M.D.
7. The Motor Area of the Human Cerebrum, its Position and Subdivisions, with Some Discussion of the Surgery of This Area. By CHARLES K. MILLS, M.D., and CHARLES H. FRAZIER, M.D.



Reprinted from the University of Pennsylvania Medical Bulletin,  
April-May, 1906.

---

THE  
FOCAL DIAGNOSIS OF OPERABLE TUMORS  
OF THE CEREBRUM.<sup>1</sup>

BY CHARLES K. MILLS, M.D.,  
*Professor of Neurology in the University of Pennsylvania ;  
Neurologist to the Philadelphia General Hospital, and  
Consultant to the Philadelphia Orthopædic Hospital  
and Infirmary for Nervous Diseases.*

(From the Department of Neurology, University of Pennsylvania.)

---

INTRODUCTION.

IN 1888, before the Congress of American Physicians and Surgeons, I presented a paper on cerebral localization in its practical relations, in which the status of focal brain surgery was discussed, the article including a consideration of the removal of brain tumors, and also of cortical excision and the operative treatment of hemorrhage, abscess and other lesions amenable to surgical procedure.<sup>2</sup> About this time and during a few succeeding years, the application of the principles of cerebral physiology to practical surgery attracted the attention and excited the enthusiasm of the profession in Europe and this country. Enthusiasm was dulled and attention relaxed by frequent failures in the attempts to exactly localize lesions, and by the difficulties which beset the surgeon in his efforts to remove these lesions with the trephine and rongeur.

---

<sup>1</sup> Read before the meeting of the Medical Society of the State of Pennsylvania, held at Scranton, Pa., September 26, 27 and 28, 1905.

<sup>2</sup> Transactions of the Congress of American Physicians and Surgeons, vol. i., 1888 ; also Brain, vol. xii., 1889.

Since the introduction of the osteoplastic operation and the newer researches into cerebral localization which have more clearly defined the motor and sensory regions of the cortex and the subdivisions of the association areas, the surgery of the brain has received a new impetus, the effects of which are seen in the increasing number of successful cases of operative interference reported in the last five or six years.

In a series of papers on localization and the neurology and surgery of brain tumors published during the last five or six years, I have given the results of many personal investigations.<sup>1</sup> This article is intended to summarize the

---

<sup>1</sup> Tumor of the Superior Parietal Convolution, Accurately Localized and Removed by Operation. *Journ. of Nerv. and Ment. Disease*, May, 1900. (With Dr. W. W. Keen and Dr. Wm. G. Spiller.)

The Localization of Brain Tumors, Especially with Reference to the Parietal and Prefrontal Regions. *Phila. Med. Journ.*, April 20, 1901.

The Separate Localization in the Cortex and Subcortex of the Cerebrum of the Representation of Movements and of Muscular and Cutaneous Sensibility. *Journ. of Nerv. and Ment. Disease*, November, 1901.

Tumor of the Brain Localized Clinically and by the Roentgen Rays, with Some Observations and Investigations Relating to the Use of the Roentgen Rays in the Diagnosis of Lesions of the Brain. *Phila. Med. Journ.*, February 8, 1902. (With Dr. G. E. Pfahler.)

An Additional Case of Tumor of the Brain Localized Clinically and by the Roentgen Rays. *Phila. Med. Journ.*, September 27, 1902. (With Dr. G. E. Pfahler, and Dr. J. B. Deaver.)

A New Scheme of the Zones and Centres of the Human Cerebrum, with Remarks on Cerebral Localization, Especially with Reference to Osteoplastic Operations for Brain Tumor. *Journ. of the Amer. Med. Association*, October 4, 1902.

The Surgery of Brain Tumors from the Point of View of the Neurologist, with Notes of a Recent Case. *Phila. Med. Journ.*, Nov. 29, 1902.

The Physiological Areas and Centres of the Cerebral Cortex of Man, with New Diagrammatic Schemes, UNIVERSITY OF PENNSYLVANIA MEDICAL BULLETIN, May, 1904.

A Glance at the History of Cerebral Localization, with Some Considerations Regarding the Subdivisions of the Areas of Representation of Cutaneous and Muscular Sensibility and of Concrete Concepts. *Proceedings of the Phila. Co. Med. Soc.*, September 30, 1904.

Subdivisions of the Concrete Concept Area of the Human Cerebrum. *The Med. News*, November 5, 1904.

The Diagnosis of Tumors of the Cerebellum and the Cerebello-Pontile

more detailed studies of the papers referred to, presenting at the same time some new views and observations. It has been found necessary in several instances to change the positions and extensions of centres and areas as formerly given in accordance with newly obtained data. This is more particularly true with regard to the position and subdivisions of the motor area, a subject which has received full consideration at the hands of Dr. Frazier and the writer in a recent paper in the UNIVERSITY OF PENNSYLVANIA MEDICAL BULLETIN.

#### GENERAL SYMPTOMS.

The general symptoms of brain tumor, which for completeness should receive brief preliminary consideration, are, as is well known, headache, vertigo, nausea or vomiting and optic neuritis. All of these may be present at one time or at some period during the progress of the case. In rare instances all of them may be absent, or one, two or any number of them may be present or absent. Their absence, severally or together, is therefore not conclusive against the existence of an intracranial growth.

The localization of headache cannot be depended upon as an indication of the site of a tumor. While the pain in the head caused by the presence of a brain tumor is often severe and may be agonizing, the complete or almost complete absence of headache is at times remarkable. This absence of headache is not always to be explained by the tumor being soft or deep-seated. In a recently observed

---

Angle, Especially with Reference to their Surgical Removal. New York Med. Journ. and the Philadelphia Med. Journ., February 11 and February 18, 1905; also Philadelphia Hospital Reports, vol. vi., 1905.

The Motor Area of the Human Cerebrum; its Position and Subdivisions, with Some Discussion of the Surgery of the Motor Region. UNIVERSITY OF PENNSYLVANIA MEDICAL BULLETIN, July-August, 1905. (With Dr. Chas. H. Frazier.)

case of tumor of large size and moderate firmness, the growth being adherent to the membranes, pain in the head was never suffered. Most frequently headache is absent in those cases of tumor which are subcortical and infiltrating, and of a consistency not much different from that of the brain itself. It follows that while the presence of severe pain in the head is strongly confirmative of the diagnosis of brain tumor, its absence cannot be regarded as excluding this diagnosis.

The same statement might be made with regard to optic neuritis, although it is more frequently absent than headache, at least this has been my own experience. It is probable that optic neuritis would almost always be found if the patient remained under observation until death, especially if operation was not performed. The reader is referred to Dr. G. E. de Schweinitz's paper on the "Ocular Symptoms of Tumor of the Cerebrum," published in the UNIVERSITY OF PENNSYLVANIA MEDICAL BULLETIN for April-May, 1906, for a full discussion of this subject. Vertigo is rarely absent, but is often so little expressed or so little taken account of by the patient as to not attract the attention which it deserves. Nausea and vomiting, although often present and frequently presenting typical features, as for instance, their occurrence without accompanying signs of gastrointestinal irritation, are, on the whole, at least for long periods, as often absent as present.

When headache, optic neuritis, vertigo and nausea and vomiting are all present and persistent in the same case, the tumor is likely to be connected with the dura, and therefore accessible if situated anywhere on the brain convexity, the exceptions being cases of subcortical tumor of large size and great density.

A word might be said about the comparative importance of general and focal symptoms. The latter may, on the whole, be regarded as the more important of the two, although the presence of a general symptom, such as optic

neuritis, may be the firmest link in the chain of evidence. Vertigo and nausea and vomiting are never absolutely conclusive, although they are not infrequently the symptoms which first suggest the existence of a tumor.

#### BRAIN TUMORS, PHYSIOLOGICAL AREAS AND SURGICAL OPENINGS.

Tumors and vascular lesions, such as hemorrhage, thrombosis, and embolism, tend to focus in special physiological areas. A tumor nearly always starts in what might be termed the heart of such an area, and largely occupies one such physiological region to the exclusion of others, although of course it may invade in any direction from its initial focus.

Following the old anatomical subdivisions of the brain into frontal, parietal, occipital and temporal lobes, these lobes can be conveniently subdivided for the purpose of diagnostic study and operative procedure into six areas, as follows: (1) the prefrontal or higher psychic; (2) the midfrontal or intermediate psychic-motor; (3) the post-frontal or motor; (4) the parietal or sensori-stereognostic; (5) the parieto-temporal or visuo-auditory; and (6) the occipital or visual. Each of these operable regions has its special symptom complex. It has also, from the surgical side, the special opening which will uncover it to best advantage.

With regard to the designation intermediate psychic-motor which has been applied by me to the second or midfrontal area, while this term is not altogether unobjectionable, it serves to express the idea that the functions of this region are intermediate between those of the purely motor zone and the region of higher psychic activity. Skilled movements of the upper and the lower extremity and of the musculature concerned with speech which are represented in this midfrontal zone, require constant guidance of purely

motor stimuli by higher mental faculties as attention, comparison and reasoning, which are represented in the pre-frontal lobe.

THE DIFFERENCE BETWEEN THE FUNCTIONS OF THE RIGHT  
AND LEFT CEREBRAL HEMISPHERES.

In the consideration of focal cerebral diagnosis some attention must be paid to the subject of the difference between the left and the right hemispheres. In the human race the left hemicerebrum, with rare exceptions, is the leading half of the brain, and as a rule the higher the individual development, the greater will be the disparity between the two hemispheres in favor of the left. In children this difference is not so marked as in those of more mature years, and in the laboring classes not so decided as in those who pursue mechanical arts requiring special skill, while in the latter it is not so pronounced as in those of high intellectual capacity and acquirements. With regard to the last two classes, however, it must be remarked that in those who pursue mechanical arts or other vocations chiefly concerned with the concrete, the concrete memory field of the cerebrum may proportionately have a higher development than in those whose pursuits are esthetic, philosophical or ethical. In the latter the prefrontal or higher psychic region has its highest evolution.

It is scarcely necessary to do more than allude to the preponderant part played by the left hemisphere in the faculty of speech, and to call attention to the corollary that while lesions of this hemisphere, according to their location, may destroy respectively or conjointly the forms of sensory, conceptual or motor speech, those of the right hemisphere may leave these functions untouched or only transiently affected. The exceptions in the left-handed, or even in extremely rare cases in others, must of course be borne in mind.



In the case of speech and writing, the conclusions in the pages which follow are largely for the left hemisphere alone. Motor aphasia, motor agraphia, word blindness, word deafness, paraphasia, paragraphia, dyslexia, alexia, anomia and other disorders of speech and writing constituting parts of the focal syndromes which will be presently considered are to be referred entirely to disease of the left hemisphere. It is for this reason that tumors and other lesions of the right hemisphere are sometimes not so easy of focal diagnosis as those of the left. While destructive lesions of the left temporal lobe give symptoms readily traced to their anatomical seat, the right temporal lobe is one of the most latent regions of the brain.

The remarks here made, with regard to the difference between the functioning of the left and the right hemispheres, have their least application in a study of the local symptoms resulting from tumors situated in the primordial zones. Symptoms referable to the motor zone as now defined by the writer, namely, that region chiefly represented by the precentral gyre and the precentral portion of the paracentral lobule, have for the purposes of focal diagnosis almost equal value for either the right or the left side; in other words, a lesion of either the right or the left precentral gyre will give contralateral symptoms of definite type. In like manner a lesion of the primary or lower visual area, that is, of the calcarine fissure and cuneus of either side, will give almost identical contralateral symptoms. The same is true of lesions of the primary auditory olfactory and gustatory centres, remembering with regard to the primary auditory centre that word hearing is not a function of this centre, but of the higher auditory area contiguous to it, this being a part of the concrete concept area. The cortical representation of cutaneous sensibility and the muscular sense may be somewhat more highly evolved on the left than on the right side, but in the main it is true of the areas supplied with projection fibres that their cortical centres are equally

developed in each hemisphere. Some facts seem to indicate that in the case of common sensibility one hemisphere has a larger power of representing both sides of the body than in the case of other functions.

Object recognition has a higher evolution in the left hemisphere than in the right, although both hemispheres take large part in this function. It follows that destruction of both occipital lobes or of parts connecting them is necessary for the production of complete and permanent mind blindness, and yet transient mind blindness may occur from a large lesion in the left occipital region.

Both prefrontal regions take part in higher psychic activities, but carefully collected data regarding lesions of the prefrontal lobes indicate that the left prefrontal region plays a more important role in intellection than the right.

I have closely studied the symptomatology of special cases of lesion of the left and the right parietal lobes, and in a previous paper have stated my belief that stereognostic conception probably has a higher evolution in the left hemisphere. A lesion of the posterior and superior portion of the right parietal lobe may therefore not give astereognosis of so decided a character as one in a corresponding position in the left parietal lobe, although the stereognostic function must have considerable development in both hemispheres.

From what has just been said about the difference between the functional power of the two hemicerebrums, this must be taken into most account when considering tumors or other lesions presumably present in the lower, intermediate and higher association areas of the cerebrum.

#### GENERAL REMARKS ON THE DIFFERENTIATION OF CORTICAL AND SUBCORTICAL TUMORS.

A brain tumor, like most massive lesions of the brain, is rarely strictly limited either to cortex or subcortex. If the neoplasm begins in the subcortex as a rule it spreads

eventually to the surface; if, on the other hand, it originates in the dura or in the pia arachnoid it first compresses and then destroys the cortex and sooner or later destructively invades the subcortex. The clinical consequence of this joint involvement is that usually a sharp line of demarcation cannot be made between the symptoms of cortical and subcortical tumors at the time when the cases are under observation; nevertheless, a tumor springing from the membranes gives early and predominating cortical symptoms, while one arising in the centrum ovale gives early and predominating subcortical symptoms. The localizing symptoms of each subcortical region are correlated with those of the physiological cortical area to or from which the fibres of the subcortex come or go.

The question of the diagnosis of subcortical growths is one of great importance. Of course, speaking generally the term subcortical is applicable to all growths situated below the cortical cinerea, and in this sense might include not only tumors of the corona radiata and internal capsule, but also those of the basal ganglia, crura, pons and oblongata. These subcortical regions must, however, be separated, in order to come to any practical conclusions in differential diagnosis.

It is necessary therefore to distinguish two classes of coronal tumors—those which grow from within outward and those which invade from the cortex inward. The latter include entirely accessible tumors and will later be fully considered. As the subcortex is destructively invaded, the symptoms at first transient and recurring, such as agraphia, aphasia, paresis, astereognosis, word blindness or word deafness, become more and more persistent and permanent. As each separate cerebral area is discussed, some attention will be paid to the differentiation of tumors predominatingly cortical or subcortical.

It may be said that tumors, like other lesions of the corona radiata, will present variations in their symp-

tomatology according to the relative number and particular value of projection, association, and commissural fibres in the part of the subcortex which is the seat of disease—a point to which some consideration will necessarily be given in the remarks on differentiation. Where projection fibres predominate, as in the subcortex of the motor and of the visual auditory and other regions of the special senses, the symptoms referable to irritation or destruction of these fibres will overshadow in importance in the study of the case those referable to implication of the fibres of association, and the focal diagnosis will chiefly depend upon the interpretation of the former. In the great association areas, posterior and anterior, the sensorial and motor symptoms will be more or less relegated to the background, although in the case of a tumor, this not infrequently involves some part of the projection system, as for instance the optic radiations, because of the manner in which they pass from the basal centres to their primary cortical destinations. Peculiar variations in symptomatology, no doubt, arise because of the disruption of the commissural connections between the two hemispheres, through the callosum and commissures; but the symptoms of such lesions rarely play an important part in practical focal diagnosis, although some exceptions to this statement need to be noted, as when considering such symptoms as cortical and subcortical word blindness, or such a question as that of object blindness being due to a lesion of one or both hemispheres or of the tracts uniting these hemispheres.

#### TUMORS OF THE PREFRONTAL LOBE, THE HIGHER PSYCHIC REGION.

Beginning at the anterior pole of the cerebrum, the first physiological region of diagnostic and surgical importance is one concerned with the highest functions of the brain. On the lateral aspect of the hemicerebrum it reaches from the

anterior tip to a line drawn from a point about half an inch in front of the anterior branch of the Sylvian fissure (the pre-Sylvian fissure) nearly vertically to the mesal edge of the hemisphere. Its posterior boundary is therefore the midfrontal or intermediate psychic motor region, occupying the posterior portions of the first, second and third frontal gyres. Tumors if destructive, or other destructive lesions of the prefrontal lobe, and especially of the left prefrontal, will cause symptoms indicative of interference with the highest psychic functions. One of the chief difficulties in determining the exact functions of this region has resulted from inaccurate or imperfect observation of mental symptoms due to lesions situated in various portions of the brain.

It has occurred to me several times to examine patients suffering from brain tumor, in whose cases psychic symptoms have been noted, and in a few instances have been given localizing value, but without due consideration. The pain, distress, irritability, inattention, and mental confusion so commonly caused by a brain tumor wherever situated are set down as symptoms due to disturbance of the higher psychic functions, while in fact they are simply the expression of exhaustion and physical suffering, or of these together with impairment of concrete memories and powers of expression. The symptoms which are really referable to destructive lesions of the prefrontal portions of the cerebrum are best expressed by stating them to be evidences of higher psychic dissolution, which is shown in loss of memory and of powers of attention, abstract conception, comparison, judgment and higher imagination.

As in this contribution I am concerned almost exclusively with the focal diagnosis of brain tumor with the view of fixing the site of operation, I shall not go at any length into a discussion of disputed points in cerebral localization. Recently, in a paper with Dr. T. H. Weisenburg,<sup>1</sup> the

---

<sup>1</sup> Chas. K. Mills and T. H. Weisenburg, *Journal of the American Medical Association*, vol. xlvii., Feb. 3, 1906.

question of the localization of the higher psychic functions with especial reference to the prefrontal lobe is discussed with the report of a case of brain tumor with necropsy, the record of which favors the view of the existence of a higher prefrontal psychic area. This subject has also been discussed by me in other publications.

The morphological and anatomical observations show that the cephalic extremity of the cerebrum in the human being is concerned with functions of higher psychic valuation than that of any other cerebral region. Embryological investigations show the absence of projection cells and fibres in a region structurally rich in cellular association systems of an unusual order.

Many clinico-pathological investigations apparently contradictory to the view here expressed regarding the functions of the prefrontal lobe have been adduced, from the famous American crow-bar case to the most recent so-called digests of cases of brain lesion showing psychic symptoms. These can be passed by for the present with the assertion that they are not conclusive, which appears the more evident the more closely the compilations are examined. Cases confirmative of the view that the prefrontal region and especially the left prefrontal is concerned with the highest psychic functions have been collected in large number.

In order that any decided effect upon the mentality of the individual shall result, the lesion of the prefrontal lobe must be destructive and must be of some extent. A tumor growing from the dura may produce no psychic symptoms of importance except those which are the result of irritation or tension until it has destructively invaded the brain substance.

Such destructive invasion occurs as soon as occluded or obliterated vessels cause necrosis of brain tissue. The victim of such a destructive prefrontal lesion begins to show failure of memory which becomes more and more decided as the disease advances. This failure of memory relates more

to matters abstract, general and distant than to those connected with his immediate surroundings. The power of attention, and especially of sustained attention, may be decidedly impaired from an early period. Problems formerly easy to solve become impossible. Inhibition is impaired. Hesitation, uncertainty, lack of force, slowness in apprehending and in communicating ideas, and motor disquietude due to loss of control, may be present.

Tumors of the orbital surface of the frontal lobe give especially psychic, olfactory and optic tract symptoms.

Some attention should be paid in this connection to the not infrequent occurrence of indirect and distant symptoms of a pronounced character. A frontal or prefrontal tumor may give severe occipital pain or the reverse may happen—a cerebellar growth causing frontal pain. Cerebellar or cerebellopontile symptoms have been noted in a few cases of prefrontal tumor, these being of large size and of such density as to exert considerable pressure. Collier,<sup>1</sup> for instance, has called attention to such a case of prefrontal tumor in which the only bulbar lesion present was degeneration of the eighth nerve. The patient's main symptoms after the disease had existed for seventeen months were paralysis of the left external rectus, marked nystagmus with a slow movement to the left, complete left nerve deafness, left peripheral facial paralysis, left cerebellar position of the head (head inclined to left shoulder and face rotated to the right), marked head retraction during paroxysms of pain, bilateral ataxia with lurching to the left, and diminished right knee-jerk. Necropsy revealed glioma of the right prefrontal lobe. The cerebellum especially the left lateral lobe was much indented into the edge of the foramen magnum.

While attention is called to the extraordinary symptomatology of this case, and while the possibility of the occurrence

---

<sup>1</sup> James Collier, *The False Localizing Signs of Intracranial Tumor, Brain*, 1904, part iv.

of a similar case with a like symptomatology should be borne in mind, too much stress should not be laid upon it in the study of focal diagnosis.

I have never seen a well-marked case of a so-called frontal ataxia, although it doubtless exists and may be due, as has been suggested, to involvement of the fronto-cerebellar tracts. Cases of agenesis and of lesions of the prefrontal lobe with some ataxia have been recorded. When present, it may be a symptom of inattention or of lack of judgment with regard to the movements rather than a true ataxia such as is seen in cerebellar or in postparietal disease. At a late period in the history of the case of prefrontal tumor which I reported with Dr. Weisenburg, the patient had a shuffling gait and was unable to convey food to his mouth with any certainty. Soon after he began to have muscular tremors in his hands and legs much like those seen in paralysis agitans.

On several occasions at periods separated by months, I saw in consultation a case which seemed to have some points in common with the one recorded by Collier, and which was eventually proved by operation and necropsy to be one of tumor of the right prefrontal and midfrontal region; it was situated so that its posterior limits grazed or merged into the motor region. The cerebellar and cranial nerve symptoms may have been due in part to counterpressure and traction.

The most important symptoms in this case were: (1) general enfeeblement; (2) what appeared to be bulbar and other cranial nerve symptoms, including dilated left pupil, sluggish iritic reflexes, left ptosis, and other third nerve palsies, nasal voice, some difficulty in swallowing, facial paresis on the left, drooling, and partial atrophy of the tongue; (3) ataxia with paresis of left upper extremity, paresis of right lower extremity, probable ataxia of left lower extremity, and inability to walk or even stand without support; (4) marked Babinski reflex on the right and normal, although not overprompt, plantar reflex on the left; and (5) impairment or



loss of control over bladder and bowels. This patient on several occasions at long intervals had attacks of Jacksonian epilepsy, the spasm being usually most marked in the left side of the face and in the left upper extremity.

With regard to the prefrontal lobe, as this terminal zone contains no projection fibres, the symptomatology of tumors of the cortex and subcortex will not differ sufficiently to allow marked clinical distinctions to be made. Tumors of the membranes, as already indicated, simply compress the prefrontal lobe and may not exhibit a symptomatology of sufficient distinctness to allow them to be diagnosticated. The more and more the prefrontal subcortex is destructively invaded the more and more serious will be the symptoms of higher psychic dissolution.

#### TUMORS OF THE MIDFRONTAL OR INTERMEDIATE PSYCHIC-MOTOR REGION.

A tumor occasionally develops with its initial nidus in some part of what has been designated in our scheme as the midfrontal or intermediate psychic-motor region. The physiological centres and areas included in this region are the speech centre of the hinder part of the third frontal convolution, the graphic centre in the posterior part of the second frontal convolution, and the centres for movements of the head and eyes, intermediate between the speech and writing centres. A case of tumor involving this region was recorded by McConnell.<sup>1</sup> The symptom complex in such a case, if the left hemisphere be involved, usually has for its central phenomena motor aphasia, motor agraphia, and Jacksonian epilepsy, with movements of the head or of the head and eyes as a salient feature of the local spasm. The Jacksonian epilepsy includes spasm of the facial musculature and movements of the upper extremity. Some psychic

---

<sup>1</sup> J. W. McConnell, UNIVERSITY OF PENNSYLVANIA MEDICAL BULLETIN, July-August, 1905.

symptoms of a special sort may be present, these being attributable to involvement of the prefrontal region. In McConnell's case, the patient's power of sustained attention and his memory were transiently affected. If the motor region is not directly involved, paralysis of the face and of the extremities is not present, or only to a slight extent. In McConnell's case some facial paralysis was detectable, but the arm, although decidedly affected in the spasmodic attacks, showed scarcely any impairment of motility. In this case the growth was successfully removed by Dr. Chas. H. Frazier, the patient recovering from his agraphia and his moderate facial articulatory paresis. His mental symptoms also cleared up entirely.

The difference of opinion and the disputes which have arisen regarding the existence of a separate motor graphic centre probably have their origin in part in misapprehensions of exactly what is meant by such a centre. Agraphia like aphasia may arise from lesions situated in different functional regions of the cerebrum. A cortical visual agraphia may, for instance, be due to a lesion of the centres for word seeing and letter seeing in the angulo-occipital cortex. An imperfect agraphia or paragrafia may be dependent upon destruction of tracts connecting the visual with the auditory centres, or connecting both of these centres with Broca's convolution. A form of agraphia results from a lesion of Broca's convolution. An aphasic who cannot arrange language for expression cannot write what he is unable to say, or can only do this very imperfectly. He may, however, be able to copy if sufficient time and care are taken. In one of my cases, the patient who had, as shown by necropsy, a lesion of the hinder part of the third frontal convolution and of the insula, could only write to a limited extent, but what he wrote was correctly spelled and expressed. If the posterior portion of the second frontal convolution is destroyed, the form of agraphia which results differs from that which is observed in the

other instances just recited. The patient who may retain full powers of movement in his arm, forearm, hand and fingers, supposing his precentral convolution to be undestroyed, is not able to use these parts skilfully for the purpose of writing, and usually for other graphic purposes, as for drawing. The cerebral centre which controls the arrangement and coördination of these movements no longer exists, although the centre for the coarse movements, out of which they have been developed, may still be intact, as may also the centres for the arrangement and coördination of articulate speech.

In a case of midfrontal and postfrontal tumor seen by me in consultation with Drs. Weir Mitchell and John K. Mitchell, and operated on by Dr. Keen, agraphia was one of the most interesting symptoms. Other symptoms present were attacks of temporary aphasia, some evidences of psychic loss or change, twitchings, first of the right and then of the left side of the face, a few convulsive attacks and slight enfeeblement of the right arm. All the forms of visual and auditory aphasia, hemianopsia and disorders of sensibility were absent. Operation revealed a tumor which was of large size. The patient died of shock and hemorrhage, and a subsequent careful examination was made of the position and extensions of the tumor by Dr. William G. Spiller. The tumor was an endothelioma measuring 7 by 8 cm. The upper part of the precentral and the highest part of the first frontal convolutions were not compressed by the tumor. The lower posterior portion of the first frontal and the whole of the posterior portions of the second and third frontal convolutions and the lower two-thirds of the precentral except the extreme lowest part were all compressed beneath the growth. The tumor did not extend behind the central fissure and did not invade the brain tissue, but started apparently from the dura, pressing upon and causing thinning of the cortex and localized atrophy of the cerebrum.

In this case the agraphia present was peculiar and was briefly described by me in a letter to the doctors Mitchell, as follows: "The agraphia is certainly the most interesting clinical feature. In general terms it belongs under the head of motor agraphia, and a study of his writing gives some support to the view of those who have said that the so-called motor graphic centre might, perhaps, be better called an orthographic centre. He tends to repeat letters, syllables and words in writing, misspelling both common and proper names, evidently at times recognizing his errors and attempting by erasures and rewriting to correct them."

This case has been reported by Gordinier<sup>1</sup> from notes furnished by Dr. John K. Mitchell.

Tumors strictly limited to the hinder portion of the left third frontal convolution are rare, but such cases have been recorded. A tumor may originate in the preinsular portion of the Sylvian fossa, involving in its progress the third frontal and, perhaps, other contiguous regions. Such a case, while comparatively easy of diagnosis and accessible, may be difficult or impossible to remove. The effort should, however, be made and may be rewarded with success if the neoplasm should prove to be an enucleable dural growth. If the primary effects of the growth should be in the third frontal gyre the chances of success would be greater.

While tumors strictly limited to Broca's convolution are rare, this cerebral region is frequently involved by invasion. A growth beginning in the motor region may advance cephalad so as to involve both the second and third frontal gyres, or a prefrontal tumor may gradually encroach upon the posterior portions of the third, second and first frontal convolutions or either of these. The initial and the invasion symptoms must always be carefully studied in such cases.

Presuming the rare case of a tumor confined almost entirely to the third frontal gyre and preinsula, the symp-

<sup>1</sup> H. C. Gordinier, *American Journal of the Medical Sciences*, September, 1903.

toms will be those long described under the name of motor aphasia. The patient according to the destructive extent of the lesion will be unable to recall and arrange for use words, phrases and sentences. He may retain a few words or expressions, or have only a single recurring utterance; he may be able to write in proportion to the degree of his ability to arrange language for emission or projection. If the growth is strictly limited to the third frontal and insula he will not have agraphia of the form which is observed from destructive lesion of the graphic centre in the posterior portion of the second frontal. Even when the growth is somewhat closely confined to Broca's convolution some pressure symptoms may be present, and these will usually be in the form of paresis of the face or upper extremity. Jacksonian epilepsy of the aphasic-motor type may appear, and in this case the spasm will usually be ushered in by some repetitive speech disorder followed by facial or faciobrachial spasm, or even by hemispasm.

A few words might be said here about the effect of the involvement in a tumor or other lesion of the centres for movements of the eyes or of the head and eyes which lie between the graphic and motor speech areas, and to some extent in advance of them. Destruction of these centres interferes with the performance of skilled movements of all sorts. The part usually played by movements of the eyes and head in reading, speaking, writing, drawing, engraving, painting and similar pursuits will be disturbed. The guidance of skilled movements of the lower extremity such as are used in dancing, and of both the lower and upper extremities, as for instance those employed in fencing, will be impaired or lost.

The midfrontal region containing the centres for skilled and highly evolved movements of the upper extremity, of the head and eyes, and movements concerned with speech, probably is not furnished with projection fibres, although this question is not entirely settled. The centres for writing

and speech probably have short neuronal associations on the one hand with the precentral motor centres, and on the other with the higher psychic centres of the prefrontal lobe; also of course they are associated with the sensory and concept centres of the cerebral zone of speech. The connections of these regions with the articulatory, phonatory and motor centres at the base of the brain and in the spinal cord are probably indirect through the centres of the motor zone.

The symptoms produced by midfrontal subcortical tumors can, it will be seen, scarcely be differentiated from cortical growths. Both will give clinical phenomena largely dependent upon the disruption of associations with other regions—psychic, motor and sensory. Aphasia, agraphia and disorders of the movements of the eyes and head will be present both in cortical and subcortical growths if these are of considerable dimensions. A tumor of the membranes invading the midfrontal cortex will however exhibit agraphic and aphasic symptoms of irregular and oscillating development, the patient retaining his powers of speech and writing later than in a case of destructive midfrontal subcortical tumor.

#### TUMORS OF THE POSTFRONTAL OR MOTOR REGION.

In the article by Dr. Frazier and the writer, already referred to, giving the results of faradization of the human cerebrum, the position is taken that the motor area is situated entirely cephalad of the central fissure, and is largely confined to the precentral convolution, its only extension beyond being an area for movements of the eyes and head in contiguous portions of the posterior extremities of the second and third frontal gyres. A large percentage of cerebral tumors originate in this region. It is scarcely necessary to discuss in much detail their focal diagnosis. The main symptoms are paresis, deepening into paralysis of the face,

arm and leg, or of two or more of these portions of the body. The upper extremity is most frequently and most profoundly affected, movements of the leg, face, jaw and of the head and eyes being impaired in extent and degree in the order of the parts named.

At an early stage of the disease monospasm usually appears, and in most cases this has a distinct initial or signal symptom. A spasm may at first be confined to the part in which it begins, as to one side of the face, to the thumb, to the thumb and fingers, or to the thumb, fingers and wrist. Occasionally the initial symptom is in the lower extremity, showing itself, for instance, in a movement of the great toe or in an extensor or flexor movement of the foot. Almost invariably, as the tumor grows and the case develops, the spasm spreads. Facial spasm may for example have added to it spasm of all parts of the upper extremity; or convulsive movements beginning in this extremity may extend so as to involve either the leg, the face, or the eyes and head, or even all of these parts. The convulsion in the further progress of the case may become general, radiating to the other side.

Agraphia and aphasia on the one hand, or cutaneous and muscular paræsthesia and anæsthesia on the other, may be invasion symptoms.

Tumors strictly confined to the centrum ovale of the motor region are rare. A tumor beginning in the motor sub-cortex and up to the time of observation limited to it, will in the first place give symptoms of paresis or paralysis early, and these will be associated with tonic spasticity, Jacksonian spasms usually not being present. The tendency seems to be for spasms of the Jacksonian type to show themselves as soon as the motor cortex is invaded, either from within or from without, but this rule is not absolute, and a subcortical motor growth may give paroxysmal monospasm or hemispasm. When the tumor simply irritates the cortex, Jacksonian spasm may be present, although well-defined paralysis

and tonic spasticity are absent; when the lesion is largely subcortical both paralysis and spasticity are marked clinical phenomena. A motor subcortical tumor is more likely than a cortical growth to have sensory symptoms associated with the disorders of motility, because the further the growth is removed from the surface of the brain the closer becomes the relations of motor and sensory tracts entering and emerging from the internal capsule. Reflexes in subcortical motor growths, as in cortical lesions, are exaggerated, but the ankle clonus and the Babinski response are if anything more persisting and striking phenomena in subcortical than in cortical lesions.

A tumor strictly confined to the motor region does not give objective sensory phenomena of a persisting character; the localizing symptoms of a growth so situated are motor, chiefly, as just described—paresis, paralysis and monospasm. Both the superficial and the deep reflexes on the side opposite to the lesion are abnormally exaggerated, much increased knee jerk, persistent ankle clonus and the Babinski reflex being commonly present. Hemianopsia, object blindness, speech disorders and true psychic symptoms are absent unless the tumor has greatly extended beyond the motor region.

In-fixing the site of a tumor of the motor zone Jacksonian epilepsy plays an important diagnostic role, scarcely second in importance to monoplegia or hemiplegia. The significance of this form of spasm in focal diagnosis and the site and nature of the lesions causing it have been made by me the subject of another paper, to which the reader is referred.<sup>1</sup>

I shall summarize here a few of the most important points of this contribution. The term Jacksonian epilepsy is used in a broad sense as indicating monospasm or hemispasm due to cortical or subcortical discharge. It is by no means always

---

<sup>1</sup> Chas. K. Mills, *The Significance of Jacksonian Epilepsy in Focal Diagnosis, with Some Discussion of the Site and Nature of the Lesions Causing this Form of Spasm.* The Boston Medical and Surgical Journal, April 26, 1906.



due to gross lesion of the motor zone, although often an important sign of such lesion.

In hemiplegias due either to softening or hemorrhage, the cortex surrounding the gross lesion is often the seat of congestion and small extravasations, which irritating the brain substance and rendering it unstable, cause epileptiform attacks. These may take the form either of monospasm or of hemiepilepsy, and may be improperly regarded as caused by a tumor.

Many cases have been recorded in which Jacksonian epilepsy has been used in fixing the site of a tumor. Some of these cases reported by others or myself have been operated on successfully by Dr. Chas. H. Fraizer, Dr. W. W. Keen, Dr. W. J. Hearn, and other Philadelphia surgeons. In all of these cases, in addition to the Jacksonian spasm, other symptoms of tumor of the motor zone, such as monoplegia, exaggerated deep reflexes and the Babinski response were present; and if the cases were strictly localized to the motor area, sensory and psychic phenomena, and speech, visual and auditory disturbances were absent. The general symptoms of brain tumor have usually been present, although I have seen cases of tumor of the motor zone in which headache and optic neuritis were not among the symptoms.

With regard to the seat and nature of the lesions and disturbances causing Jacksonian epilepsy, it must be borne in mind (1) that tumors situated in other parts of the brain than the motor cortex may cause Jacksonian epilepsy; (2) that other lesions beside tumors situated in the motor cortex may cause this form of spasm; (3) that it may occur in toxic and other diseases in which no demonstrable focal lesions are present; (4) that a spasm closely counterparting the Jacksonian type may be observed as a reflex or an hysterical disorder; and (5) that Jacksonian epilepsy may be simply an integral part or the entire expression of a case of idiopathic epilepsy. Each of these is fully considered in the paper to which reference has just been made.

TUMORS OF THE PARIETAL LOBE, REGION OF REPRESENTATION  
OF CUTANEOUS AND MUSCULAR SENSIBILITY AND OF  
STEREOGNOSTIC CONCEPTION.

In this connection the parietal lobe is defined after the usual manner of the anatomical works, namely, considered as regards the lateral aspect of the hemisphere, as that part of the cerebrum which is situated between the central fissure in front, the line of the parieto-occipital fissure behind and that of the Sylvian fissure below. It includes, therefore, the postcentral, superior parietal and inferior parietal gyres. This lobe can be divided physiologically into areas of representation of cutaneous and of muscular sensibility and of stereognostic conception, the first having its seat in the postcentral gyre; the second probably in the anterior portions of the superior and inferior parietal convolutions, and the third in the posterior portion of the superior parietal. Cutaneous and muscular sensibility and stereognostic conception probably all have some representation on the mesal aspect of the cerebrum, but we are only concerned with this indirectly in the present study of operable cerebral lesions.

The positive focal symptoms of parietal cortical and cortico-subcortical disease are impairment, usually moderate, of cutaneous sensibility, and especially of the pain and temperature senses, diminution or loss of muscular sensibility and astereognosis. When other symptoms are present they are commonly due to pressure or destructive invasion of envioning regions with different functions. These may for example, if the tumor advances in a cephalic direction, be motor paresis and Jacksonian spasm with their usual accompaniments as regards the reflexes. Jacksonian spasm, however, as elsewhere indicated, occurs only rarely. If the growth invades posteriorly, the added symptoms may be visual aphasias, such as word blindness and letter blindness, and if inferiorly word deafness or other auditory aphasic phenomena. Any considerable implication of the cerebral subcortex posteriorly may give rise to hemianopsia.

If the tumor is strictly limited to the parietal lobe and does not cause any considerable pressure on the pyramidal system, both the cutaneous and the deep reflexes may be impaired in the direction of diminution. Not only is the Babinski response absent, but the cutaneous plantar response may be as negative as that which is observed in hysterical anesthetics. The knee-jerk and other tendon and muscle phenomena on the sides of the lesion remain normal, and on the opposite side either normal or somewhat depressed. If either by pressure or by destructive process, as the growth increases, the motor zone or the pyramidal tracts be involved, persistent ankle clonus and the Babinski response will appear. I have seen and recorded several cases in which the syndrome as regards the reflexes has changed during the progress of the case, as thus indicated.

To emphasize the most important features of the diagnostic symptomatology of tumors of the parietal lobe, it is necessary to briefly discuss the question of its subdivisions into different forms of sensorial and memorial representation. As I have long taught, the representation of cutaneous sensibility in all its forms is, generally speaking, located in such a manner as to surround the region of motor representation. As the motor zone according to our latest views is situated precentrally on the lateral aspect of the hemisphere, and also precentrally in the superior half of the paracentral lobule on its mesal aspect, cutaneous sensibility is in all probability represented in the postcentral convolution and in the lower half of the paracentral. As to how far the gyrus fornicatus takes part in this representation is not quite clear; not improbably the calloso-marginal fissure and the upper border of the gyrus fornicatus are concerned in cutaneous or muscular sensory representation, or in both. Cortical sensory representation is probably divided into segments for different cutaneous areas of the body, and these have topographical relations with centres and subareas of the motor region. The representation of cutaneous sensibility in the face, for example, is probably situated postcentrally and on a level with

motor facial representation, that is, in the lower third of the postcentral and the adjoining anterior portion of the inferior parietal convolution, or the latter may be the seat of muscular representation for the face. The representation of cutaneous sensibility in the upper extremity occupies the postcentral convolution over a large area, extending from the facial representation to that of the trunk, this being subdivided for different parts of the upper limb. The representation of sensation of the trunk occupies a narrow strip like its correlated precentral motor centre, while sensation in the lower extremity, the anus and vagina is represented close to the longitudinal fissure on the lateral aspect of the hemisphere and more largely in the posterior and inferior portions of the paracentral lobule and the adjoining limbic lobe. Just where, in the general sensory field, the different forms of cutaneous and of muscular sensibility have their separate cortical seats it is impossible, with our present knowledge, to say.

The views here expressed with regard to the subdivisions of the cortical sensory areas, to which should be added in this connection the area for stereognostic conception, have been held by the writer for some years. They were published in the *Proceedings of the Philadelphia County Medical Society* for 1904, and also presented in a paper before the American Neurological Association in the same year. Cases of cortical lesion have occasionally been published showing the restriction of disorders of sensation and of motion to one extremity or to limited portions of an extremity or the face, but the inferences drawn have usually been based on the view that the motor region was both postcentral and precentral.

In the well-known case of Starr and McCosh,<sup>1</sup> a limited postparietal lesion produced loss of muscular sense confined to the opposite arm and forearm without paralysis.

Spiller<sup>2</sup> has recently reported a case which indicates that

---

<sup>1</sup> M. A. Starr and A. J. McCosh, *Amer. Journ. of the Med. Sciences*, Phila., 1894, vol. cviii.

<sup>2</sup> Wm. G. Spiller, *Journ. of Nerv. and Ment. Disease*, Feb., 1906, vol. xxxiii.

sensation may be affected from a cerebral cortical lesion without motor paralysis, and that the sensory alteration may be confined to one limb. A few cases similar to those of Starr and McCosh and of Spiller have been recorded.

The writer holds in the first place that the cortical representation of cutaneous and muscular sensation is separate from that of movement; secondly, that it is distinct not only for face, arm, trunk, and leg, but also that special segments or areas of the skin are definitely correlated with subdivisions of the sensorial and stereognostic cortex; moreover, that the restricted centres and subareas for sensation and stereognosis are correlated anatomically and functionally with special cortical motor centres. In the periphery, segments of the skin are over or closely related topographically to the muscles producing movements which are represented in the motor cortex by centres which are connected with cortical sensory centres representing these cutaneous segments or areas. The segment of the skin covering the muscles producing adduction of the thumb, for instance, is represented in the cortex by a centre which is distinct but neuronally associated with the cortical centre for this movement of the thumb.

The parietal symptom complex as stated includes astereognosis, or as some prefer to call it, stereoagnosis, the recognition of the nature and use of objects by manipulation. This is not a sense like that of pain, contact, or temperature; neither is it entirely correct to speak of the function as stereognostic perception. Stereognosis is a conceptual process. The ability to recognize objects by touching and handling them so as to obtain an idea of their form is brought about by the recalling of memorial images obtained in the first place, through such senses as contact, pain, temperature, spacing, location and position, but although thus obtained the process of recognizing objects in this way becomes an independent one. The cutaneous and muscular sensory processes are primary; stereognosis is secondary and higher. The former are comparable to what takes place in the primary visual centres in the cuneus and calcarine cortex;

the latter to the higher visual processes represented in the lateral occipitotemporal region. The stereognostic centre or area should therefore be situated in the concrete memory field or posterior association area of Flechsig. This is just where clinicopathological observation has placed it, namely, in the superior parietal convolution and the adjoining cortical expanse on the mesal plane of the hemisphere. This conceptual area, it will be seen, is surrounded on all sides by cutaneous, muscular and visual centres which administer to it. It is probable that in the process of stereognostic conception vision often plays a part; in other words in handling objects not only are cutaneo-muscular memorial images recalled, but also to some extent the visual concept of the object appears in consciousness.

A tumor rarely originates in and is still more rarely confined to the postcentral convolution. It is much more likely to have its primary nidus in the motor zone or in the postparietal region. It is for this among other reasons that ataxia and astereognosis are commonly more prominent manifestations in tumors of the parietal lobe than disorders of cutaneous sensibility. It is also likely that cutaneous sensibility has more or less bilateral representation in each hemisphere, so that destruction of both the right and the left postcentral gyres is necessary in order that decided cutaneous anesthesia shall be present.

With regard to tumors of the centrum ovale of the parietal lobe, of which I have seen several interesting examples, the differentiation between these and cortical neoplasms can be summarized in the statement that the disorders of cutaneous and muscular sensibility and of stereognostic conception are more persistent and complete in accordance with the depth of the destructive lesions, and with the additional statement that important invasion symptoms such as paralysis and tonic spasticity on the one hand, and hemianopsia and visual aphasias on the other, are much more likely to be present early in the subcortical growth.

In a case reported by Oppenheim<sup>1</sup> a man twenty-three years old had headache and vomiting with attacks of unconsciousness, after one of which he was left with paralysis of the left arm and left leg. The ophthalmoscope showed no optic neuritis. Pupils were normal and ocular movements were also normal. Examination showed that the ordinary use of the left arm was not much diminished, but hand pressure was slightly diminished. Tactile sense in the fingers and on the palmar surface of the hand was slightly diminished, as was also the sense of position. Disturbances of stereognostic conception were very pronounced in the left hand as tested with watch keys, steel pens and other objects. Sensations of pain and temperature were intact. In the left arm was a moderate but distinct ataxia. The left leg was dragged slightly in walking. The tendon reflexes on the left side in the leg were exaggerated to the extent even of a clonus. The left leg showed distinct ataxia. Hemianopsia was not present. Oppenheim's provisional diagnosis was tumor of the right parietal lobe reaching to the border line of the postcentral convolution and the first temporal convolution. The tumor was successfully removed. It was probably from description largely either cortical or cortico-subcortical.

In 1905 Dr. Chas. H. Frazier operated on a case of gummatous meningitis with involvement of the cortex of the parietal lobe, a case which illustrates the principles of diagnosis for tumors or other irritative lesions of this region. The patient was under the care of Dr. Wm. G. Spiller, and had previously been operated on at the Philadelphia Polyclinic by Dr. John B. Roberts. For a time he was in the wards of the writer in the Philadelphia General Hospital. The case will be fully reported by Dr. T. H. Weisenburg at the meeting of the American Neurological Association in June, 1906. The main symptoms were diminution of cutaneous and loss

---

<sup>1</sup> Oppenheim, *Mitteilungen aus den Grenzgebieten der Medizin und Chirurgie*, 1900, 3d vol.

of muscular sensibility, astereognosis and hemiparesis, and in addition the patient had frequently recurring attacks of Jacksonian epilepsy. The spasms began with a flexor movement of the fingers and adduction of the thumb, and then spread to the forearm, arm and shoulder, sometimes involving the face and abdominal muscles and very rarely the lower extremity. This case was interesting both as indicating the location of the areas for stereognostic conception, cutaneous and muscular sensibility and movements, and also because of the peculiar manner in which the impairment or loss of muscular sense and stereognostic conception was limited to portions of the hand.

In November, 1899, Dr. Keen operated for me on a case which illustrated the principles of diagnosis applicable in cases of tumor of the parietal lobe. The localizing symptoms were, in the main, impairment of cutaneous sensibility, loss of muscular sense, ataxia, astereognosis, paresis and ultimate paralysis. The patient had some verbal amnesia and fatigue on reading. At one examination he showed a temporary partial right hemianopsia. Reversals of the color fields and contraction of the fields for form similar to those supposed to be typical of hysteria were present at several of the examinations. The deep reflexes were exaggerated on the affected side and ankle clonus was present at a relatively early period after the recognition of the existence of a tumor. The Babinski response was not present at first; in fact, the metatarsophalangeal reflex was absent for a long time. Later the Babinski response appeared. Operation was performed with the view of uncovering the superior parietal convolution as the central point of procedure. The tumor was removed and the patient lived in comparative comfort for about five years, when there were signs of recurrence of the growth. Operation was again performed by Dr. Keen and a tumor at the site of the former lesion, but invading more anteriorly, was revealed and removed. The patient, however, succumbed to the shock of the operation.

In another case, a boy eight years old, operated upon by



Dr. Keen, the chief symptoms were impairment of the muscular sense, ataxia, astereognosis and paresis. Cutaneous sensibility was unimpaired or but slightly affected, with the exception that he could not locate skin sensations accurately. The deep reflexes were all exaggerated on the affected side, ankle clonus and the Babinski reflex being present.

A tumor was found and removed by Dr. Keen, it being located in the main in the superior parietal convolution (parietal of Wilder).

In another case the patient early developed marked sensory symptoms. When examination was made, three weeks before operation, it was found that the pressure sense was absent all over the hand, that the pain and temperature senses were absent in the upper extremity, most markedly in some portions of it; that the Babinski reflex could not be obtained in the great toe, and the right arm-jerks were absent. Two weeks later the patient had a severe attack of tonic spasm in the right arm, which lasted fifteen minutes. Paralysis of the limbs of the right side, in a few days, was practically complete; no hemianopsia was present. The profound disturbances of sensation in this case were probably due to early implication of the parietal subcortex; the motor symptoms to subsequent invasion of the motor subcortex. Operation and necropsy showed that the tumor had invaded both subcortex and cortex of the parietal region and the subcortex of the postfrontal region; it had evidently originated in the subcortex, as it was just breaking through the parietal cortex at the time of operation. Operation in this case was performed by Dr. W. W. Keen.

In still another case recorded by me which was operated by Dr. W. J. Hearn, the first focal symptom was loss of power in the right leg. At the time of examination loss of power was marked in leg and arm, more complete in the latter, and some facial paresis was also present. Knee-jerk and patellar clonus were present on the right, although, strange to say, both the ankle clonus and the Babinski reflex were absent. The right leg exhibited spasticity and tremor and

the right arm was also spastic. Sensation to touch and pain was nearly lost in the right upper extremity; it was but slightly impaired in the right lower extremity. Impairment of muscular sense was also a marked feature. Astereognosis was present and became more and more positive as the case progressed to its termination. All forms of cutaneous sensibility and muscular sensibility were tested by the usual methods, with the result of showing impairment, which as time passed became more and more complete in the upper extremity. The so-called senses of locality, position, pressure and spacing were found wanting. In the right lower extremity the quadriceps-jerk and knee-jerk were exaggerated, and patellar clonus was marked. The focal symptoms became more and more profound, but did not alter except in degree. The patient suffered from headache of great severity and optic neuritis, which passed into atrophy. The diagnosis was made of a dense tumor of large size, probably in the main subcortical, situated chiefly in the parietal region, possibly invading the motor region and extending or compressing the posterior limb of the internal capsule and the optic radiations. The position of the growth was also determined by a Roentgen ray investigation, the shadow being very decided. In the operation performed by Dr. Hearn a portion of the tumor was removed.

Although this case eventually became cortical by its growth from within outward, it presented the characteristic features of a subcortical postfrontal and parietal growth—namely, early and marked paralysis, tonic spasticity without Jacksonian convulsions, loss of all forms of sensation and astereognosis; the reflexes, as might be expected, were of uncertain diagnostic importance because both the motor and the sensory subcortex were involved.

In a case of large parieto-occipital tumor the mistake of operating for the motor region was made. The patient was seen late, when the motor symptoms overshadowed all others, and one or two points in the past history of the patient were not obtained until after the operation, especi-

ally some facts which seemed to indicate that hemianopsia had been present. At the time when it was decided to operate, the patient's symptoms were such as to make it impossible to determine clearly the existence of symptoms like hemianopsia, astereognosis and impairment of cutaneous and muscular sensibility. Because of the predominance of motor symptoms, such as paralysis with contracture and exaggerated reflexes, it was decided to operate for the motor region, although the position of the growth was regarded as somewhat uncertain.

The general symptoms of brain tumor were present. The operation was performed by Dr. A. C. Wood, of Philadelphia. The patient died several weeks after the operation, and it was found at necropsy that the posterior line of the opening was just anterior to the large tumor mass.

TUMORS OF THE REGION OF THE JUNCTION OF THE PARIETAL,  
OCCIPITAL AND TEMPORAL LOBES, THE HIGHER  
VISUO-AUDITORY REGION.

The inferior parietal or subparietal convolution curves around the posterior extremity of the Sylvian fissure to unite with the first or supertemporal convolution, and in like manner another portion of the subparietal convolution curves around the posterior extremity of the first temporal fissure to join with the hinder portion of the second temporal convolution. Two angular or curving convolutions are thus formed. To that which is constituted by the convolution which winds around the posterior extremity of the first temporal fissure the term *pli courbe* or angular convolution has long been applied. The general region formed by the curving and uniting extremities of these parietal and temporal convolutions is one of the highest functional importance. It is the visuo-auditory area of the cerebral zone of speech. In the angular convolution, and perhaps extending somewhat beyond it posteriorly, are situated the centres for word

seeing, letter seeing and number seeing. The primary auditory centre, that area the destruction of which on both sides will cause cerebral deafness to primary sounds, is situated in the retroinsular convolutions and the coterminus part of the posterior extremity of the first temporal convolution. The centres for word hearing and for other higher forms of auditory representation, as for natural musical notes and intonation, are situated on the outskirts of the primary region of auditory representation. The word hearing centre has been placed by me at the junction of the first and second temporal convolutions in their posterior parts. The centre for intonation is probably situated more anteriorly in the first or second temporal convolutions. With regard to the function of word hearing and of intonation, the representation is much more evolved in the left than in the right hemisphere.

A tumor destroying the angular or highest visual region will cause word blindness, letter blindness and number blindness, or some of these; also verbal amnesia, visual agraphia, paragraphia, alexia, dyslexia and paralexia. The chief invasion symptoms will be auditory aphasias and hemianopsia if the disease advances in a postero-inferior direction, or if in an antero-superior direction, astereognosis and disorders of cutaneous and muscular sensibility. ♦

A tumor occasionally originates in the first or second temporal convolutions, of which I have seen instances. If such a growth originates in this portion of the left hemisphere the central feature of the syndrome will be word deafness with its aphasic accompaniments, such as paraphasia, paralexia and word dumbness. Commonly some visual aphasia is associated with the auditory aphasia because of the proximity of the higher visual centres and their associations with the higher auditory centres.

Dr. Stanley Barnes<sup>1</sup> has reported an interesting case which

---

<sup>1</sup> Stanley Barnes, *Review of Neurology and Psychiatry*, vol. i. 1903.

illustrates the principles of focal diagnosis in a case of tumor situated so as to destroy or partly destroy the fibres which connect the visual and auditory centres together and these centres with the speech and graphic centres in the third and second frontal convolutions. A tumor was present which had evidently grown very slowly over a period of nine or ten years. The growth was bounded in front by the postcentral, and behind by the angular convolution, which was somewhat involved by young growth; above the superior parietal lobule was also somewhat implicated. It would seem from the description that the tumor occupied largely the inferior parietal convolution, although the recorder of the case speaks of it as bounded below by the supermarginal convolution. The patient had a series of attacks extending over many years. In these he was dazed or dizzy, had shimmerings of light before the eyes, and had numbness beginning in the right hand and extending to the arm, side and leg. Other symptoms were word dumbness, paraphasia, concentric contraction of the visual field on the side opposite to the lesion, and at times slowness in understanding what was said. Spontaneous writing, writing from dictation and from copy were all markedly affected. He had an imperfect right hemianopsia. He was not object blind, and had no loss of power or impairment of sensation or astereognosis. After the early seizures, the focal symptoms disappeared almost entirely, but were more persistent as time went on between the attacks. Optic neuritis was not present until late. Headache, vertigo and nausea and vomiting were among the general symptoms. The growth would probably have been largely included in the upper portion of the opening advised for the exposure of the visuo-auditory centre, and in the lower portion of the parietal opening. By moving the visuo-auditory opening a little forward and toward the mesal line the tumor would have been well uncovered.

## MIDDLE AND INFERIOR TEMPORAL REGIONS.

Tumors are infrequent in the middle and inferior temporal regions, which include the lower half of the second and the whole of the third, fourth and fifth temporal convolutions. The uncinate and hippocampal convolutions are of course too centrally situated to be accessible to the surgeon. A growth involving the second, third and fourth temporal convolutions might be removed, at least in part, but in the case of the third and fourth temporal convolutions, not without some destruction of the brain substance around the tumor. I have seen a case of mid-temporal tumor which at an early stage, probably a year before the death of the patient, might have been removed by a careful surgical procedure. Such growths, like tumors in other situations, may arise in the membranes of the middle fossa and gradually compress and invade the temporal lobe. The symptoms produced by a tumor in the mid-temporal region are not well known. In one case studied by me they included word dumbness, hemianopsia and a partial mind blindness and word blindness. The tumor in this case, however, at the time of investigation just before death had invaded considerably toward the occipital lobe. A tumor strictly limited to the mid-temporal region will probably give as its main symptom word dumbness because of the destruction of the naming centre in this region, presuming its existence here. If such a centre should not here exist, as has been asserted, the same symptoms will be produced by destruction of the tracts passing through the various sensory centres on the receptive side of the brain to the motor speech centre in Broca's convolution.

The opening used in the effort to reach the middle and lower temporal regions should be made as low as possible on the side of the skull, its superior limit being on a line which would correspond with the horizontal branch of the Sylvian fissure just before it turns upward posteriorly.

TUMORS OF THE OCCIPITAL LOBE, THE LOWER AND HIGHER  
VISUAL AREAS.

The primary cortical visual centres, the centres of the optic perception field, are situated entirely or almost entirely on the mesal surface of the occipital lobe, the centres of color recognition being probably situated more ventrally on its tentorial aspect. The secondary or higher visual area, however, covers a large extent of the lateral occipito-temporal expanse. Centres of object recognition in its various forms are situated from the first to the fifth occipital convolutions inclusively and occupy also the contiguous caudal extremities of the adjoining temporal convolutions. These centres of object recognition, as has been indicated by me in other contributions, have probably a considerable subdivision, but the subareas or centres partly or wholly authenticated are few in number. They include the centres for word seeing, letter seeing and number seeing in the angulo-occipital region and centres for persons, places and natural objects in the rest of the lateral occipital lobe. I have suggested also the probable existence of centres for geometric and architectonic forms close to the representation of the symbols of language, but no facts have been forthcoming as yet substantiating this suggestion.

It is evident from a study of the anatomy of the skull and brain that only those occipital tumors are operable, or at least can be operated upon with much hope of success, which are situated wholly or largely in the lateral occipital region. It is true that the mesal surface of the lobe and even its tentorial surface may be to some extent explored, and by a good chance a small tumor may be shelled out of either of these regions. Another point worthy of recollection in this connection is that a large part of the occipital lobe may be removed, as was done in one of my cases by Dr. Frazier, without fatal or even serious symptoms, except of course the necessary loss of vision; so that a tumor sit-

uated in any part of the occipital lobe may be worthy of the consideration of the surgeon.

A tumor of the lateral occipital or occipito-temporal region, the area of higher visual representation, if the lesion be a left-sided one, will give for its main symptoms word, letter and number blindness, complete or partial, and if partial their accompanying aphasic defects such as paralexia, agraphia and paraphasia, optic aphasia or word dumbness, and in some cases mind blindness, which in unilateral lesions is usually incomplete and transient or paroxysmal. As tumors, even those which originate in the membranes, usually sooner or later involve the subcortex, hemianopsia is often present. Other compression and invasion symptoms are chiefly auditory symptoms, such as word deafness and paraphasia, although ataxia and astereognosis may appear if the growth advances forward. In addition to the hemianopsia, if its advance is subcortical, hemianesthesia and hemiparesis or paralysis may appear.

The Wernicke reaction is absent. The deep and superficial reflexes in the extremities are usually not changed. Motor affections and psychic disturbances except those concerned with visual concrete memories are absent.

In the last section I have spoken of the manner in which the highest visual and the highest auditory areas could be exposed jointly or separately. If the symptoms are almost purely visual the osteoplastic opening should be more posterior than those referred to in that section; in other words, it should be made so as to include the entire lateral aspect of the occipital lobe with adjoining extremities of the parietal and upper temporal convolutions, as indicated by the space marked occipital in Fig. 2. Practically the region referred to in this figure would be exposed by an opening one side of which would be parallel with the longitudinal fissure, about one-half inch from the mesal line, and the other parallel with the lateral sinus about one-half inch from the cranial line corresponding to this sinus. The other two



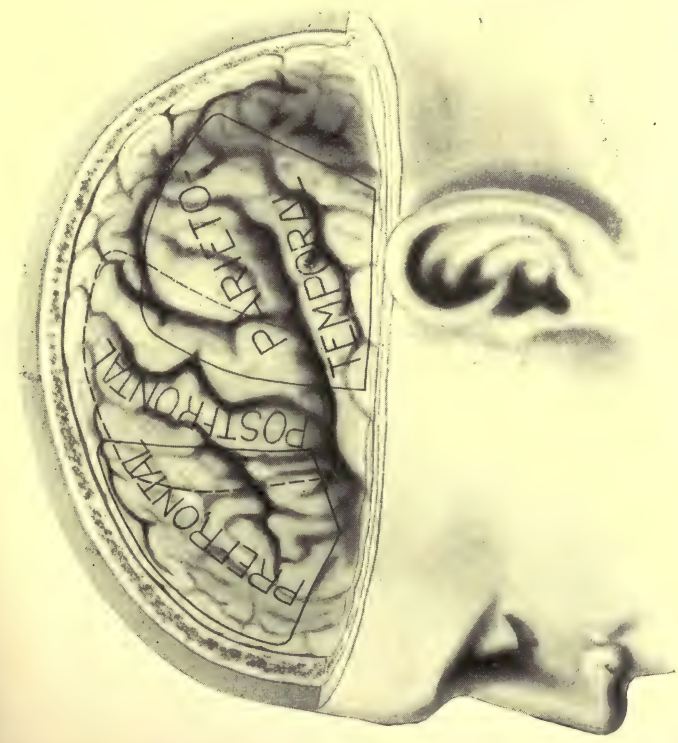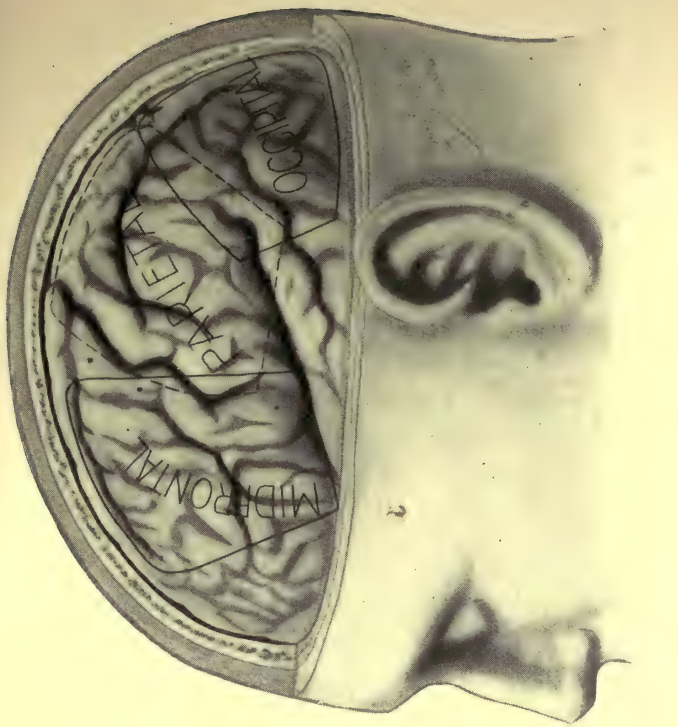


FIG. 1.—Diagram showing the convolutions uncovered by standard osteoplastic openings for the prefrontal, postfrontal (motor), and parietotemporal (visuoauditory) regions.

FIG. 2.—Diagram showing the convolutions uncovered by standard osteoplastic openings for the midfrontal, parietal, and occipital regions.

sides of the opening could be made in the most convenient manner possible.

I have seen no cases of successful operation on the occipital lobe, although in two cases of occipital tumor operation was performed for me by Dr. Frazier. The growths, however, were not reached, probably because they were located tentorially or meso-tentorially. In one case the patient died, but no necropsy was allowed; the other patient is still living and in fair general health, although a portion of his occipital lobe was cut away several years since. This case is one of those referred to by Drs. Spiller and Frazier in their paper on "Decompression."

A tumor of the right basal occipito-temporal region, if the optic radiations and cuneus are not involved, is very difficult of diagnosis. In a case of this kind occurring in my practice, Dr. Frazier performed a subtentorial operation. This patient had the well-marked general symptoms of brain tumor, including optic neuritis of an extremely high grade. Hemi-anopsia, as tested by the hand, which was the only method which could be adopted owing to his relative blindness, was not present. The only symptoms which seemed to have any localizing value were a drooping of both eyelids and nystagmus on lateral movements. Associated upward movements were performed promptly, but the patient was unable to keep the balls upward, and convergence was very slightly performed. The tumor in this case was large and dense, and had destroyed the occipito-temporal region in large part.

#### GENERAL REMARKS ON SOME OF THE SOURCES OF ERROR IN THE FOCAL DIAGNOSIS OF BRAIN TUMOR.

In spite of the numerous advances, some of them quite recently made, in our knowledge of focal physiology and focal diagnosis, mistakes are still made by those whose business it is to locate tumors or other operable lesions for the surgeon, although it is notable that these mistakes

are growing fewer. At several points in the preceding pages some of the sources of error in focal diagnosis of brain tumors have been pointed out, as, when speaking of the occurrence of cerebellar, sixth nerve and other symptoms because of the tilting of the brain, and its jamming into the foramen magnum by a prefrontal growth, as recorded in one of the cases of Collier; as also when referring to the fact that Jacksonian epilepsy may be simply a part of the convulsive attack in a case of idiopathic epilepsy, and that this form of spasm, due to a variety of focal lesions and general states, may be attributed to the presence of a neoplasm in the motor region; and again, as when speaking with references to illustrative cases, of the masking of parietal or prefrontal symptoms by the late and more obtrusive motor manifestations due to pressure and invasion.

The paper of Collier on the false localizing signs of intracranial tumor, to which reference has already been made several times, presents in an admirable way the manner in which focal symptoms in cases of brain tumor may mislead the neurologist and surgeon. Almost every point to which he calls attention has been personally observed by me, and to some of the points I have called attention incidentally in various papers. The contribution of Collier has, however, particular value because of the succinct and eminently practical manner in which he has marshalled these false portents, and in the remarks which follow I shall again avail myself of his observations.

The interpretation of symptoms due to pressure exerted upon a functional area or tract as the evidences of tumor impairing or destroying this area or tract and the obscuring of the early and more important symptoms by those which are caused by late invasion or encroachment are matters upon which emphasis has already been made, but because of their importance it will be of service to refer to them again in this general discussion of diagnostic errors, especially as the neurologist is sometimes called late in the course of

a case of brain tumor to decide as to the site and operability of the lesion. He may see the patient for the first time after the disease has been present, recognized or unrecognized, for months or even years. The patient at this time may present a striking symptom-complex. It may be that of hemiparesis or hemiplegia, with occasional attacks of Jacksonian epilepsy; it may be hemianopsia with some attendant sensory phenomena; or it may be aphasia or agraphia; or other symptoms formerly present may be overshadowed or obscured, as for instance, in a case of hemiplegia such clinical phenomena as hypæsthesia, ataxia and astereognosis, or in a similar case, psychical, aphasic and agraphic phenomena. It follows, therefore, that when the localization of a growth is for the purpose of exactly fixing the limits of an operation, the method in which the tumor has spread, as determined by a careful study of the history of the development of symptoms in the case, is often of the greatest importance. Probably the mistake most frequently made is that of supposing a tumor originating and largely occupying the prefrontal lobe, and only encroaching upon the graphic, speech or motor region, chiefly occupies the last.

Compression symptoms usually precede for a short time at least those of absolute encroachment, and this fact needs to be borne in mind. It may be said, however, that symptoms due solely to pressure are rarely absolutely continuous and can be differentiated by a close study of the case. In many cases the pressure seems to transiently let up or recede, probably because, in some cases at least, of the filling and emptying of the cysts which are often connected with tumors.

Collier's discussion of the disappearance of true localizing signs in late stages of brain tumor is in part a discussion of the effects of invasion. Among other things, he shows how the late symptoms may obscure entirely the presence of a cerebellar growth.

One must be always on his guard not to be misled in his

efforts at accurate localization because of the presence of abducens palsy. Different theories in explanation of the frequent occurrence of this symptom have been given. Probably it has most often been attributed to the effects of pressure upon the nerve in its long intracranial course, and this doubtless accounts for it in some instances. Collier has suggested another explanation which is reasonable and may explain the symptom in some cases. He has shown that as the result of pressure of a large prefrontal tumor, the brain may be more or less tilted so that the cerebellum and oblongata are jammed into the foramen magnum. One of the consequences of this compression and tilting of the entire brain is traction on nerves like the sixth and third, which have a long caudocephalic course. The sixth nerve especially would be subject to such traction; in other words, the case would afford an illustration of indirect traumatic traction palsy. The nerves like the fifth, seventh, eighth and others which run transversely or more obliquely are not subjected to the same amount of traction. Whatever may be the correct explanation, the diagnostician should always bear in mind that while paresis or paralysis of the sixth nerve may be of strict localizing value, that is, may indicate involvement of this nerve, it may on the other hand be an indirect symptom of tumor of large size situated in various regions of the brain.

Fifth nerve symptoms, either sensory or motor, may be present in a case of brain tumor in which this nerve is not directly involved. In two cases referred to by Collier, in which the tumor was situated in the left prefrontal region and frontal centrum ovale respectively, fifth nerve anesthesia and hemianopsia were both present. Collier attributes the symptoms referable to this nerve to pressure exerted on the middle fossa by a large prefrontal tumor on the same side.

The occurrence of bilateral spastic paresis in a case of brain tumor is not infrequent and may be misleading. In one of my cases of tumor of the cerebello-ponto-oblongatal

recess this symptom was most marked, and hydrocephalus of considerable degree was found on necropsy. So marked was the spastic paralysis in this case that I suspected some form of spinal disease, as meningomyelitis, in addition to the brain tumor which was evidently present from the general, as well as the local, symptoms. Collier lays much stress on the occurrence of this symptom of bilateral spastic paresis due to hydrocephalus accompanying a brain tumor in various intracranial situations. A tumor of the brain stem is most likely to give rise to this affection. Affections of various cranial nerves may be associated with the bilateral spastic paresis.

In discussing errors in focal diagnosis, the question of multiple tumors needs brief consideration. When more than one growth is present in the cranium, it is rare to find these growths in the cerebrum proper. Usually one will be present somewhere in the cerebrum, and another or others at the base or in the cerebellum. In multiple sarcomatosis, growths may, for instance, be present in both cerebellopontile recesses, in the middle and anterior fossa and even in various positions in the spinal canal. In very rare cases similar tumors may be present at nearly corresponding points in both hemispheres. A tumor of the callosum occasionally invades in both directions. In bilateral tumors, if recognized, operation on both sides might be considered; in other cases the growths are inaccessible and inoperable.

Our concern is with the operable tumors of the cerebrum, but a few words might be said about the diagnosis of some of those intracranial neoplasms which are inaccessible and inoperable, especially as in a few instances these give symptoms which may seem at some stage to point to accessible regions. Tumors of the thalamus give inco-ordination and anæsthesia, and according to some authorities central pain. If the pulvinar or optic radiations are involved hemianopsia will be present. When the superior cerebellar peduncles are included in the lesion hemichorea and hemiathetosis may be present, and when the pregeniculum is implicated the Wer-

nicke pupillary reaction. Forced laughing or crying have also been noted as thalamic symptoms. Monoplegias or hemiplegias described in connection with thalamic lesions are probably due to the destruction of the neighboring parts of the internal capsule. A tumor involving the thalamus and posterior part of the posterior limb of the internal capsule might at some stage of its development have some of the appearances of a tumor of the parietal subcortex.

Tumors of the lenticula and caudatum give symptoms which cannot with our present knowledge be well separated from growths affecting the internal capsule. These symptoms are mainly hemiparesis or hemiplegia with disorders of speech, and if the lesion is in the caudal portion of the lenticula, hemianæsthesia may be present. Von Bechterew<sup>1</sup> has described a symptom of lesion of the lenticula designated by him as pseudomelia paræsthetica. To a patient suffering from this affection the limbs appear to be in a position in which they are not.

With regard to tumors of the chiasm and the pituitary body, attention should be concentrated upon bitemporal hemianopsia, olfactory disorders and symptoms indicative of implication of the third, fourth and sixth nerves. The part which some believe is played by the lesions of the pituitary body in the causation of acromegaly should be borne in mind. In tumors of the crura, symptoms of third nerve involvement on one or both sides and paresis of the extremities on one or both sides are prominent. Chiasmic, pituitary or crural lesions can scarcely be mistaken for any form of operable lesion of the cerebral cortex or subcortex.

Tumors involving the cinerea of the region of the Sylvian aqueduct, the brain stem or the cranial nerves at the base anywhere in their course give pseudobulbar, nuclear and cranial nerve symptoms—a statement sufficient to indicate the method of their separation from operable cerebral lesions.

The symptoms of tumors of the pons will vary according

<sup>1</sup> Von Bechterew, *Neurol. Centralbl.*, No. 17, September 1, 1905.

to the exact location and extensions of the growth. Among them the most notable are alternating hemiplegias of different type, paresis or paralysis of separate or of associated ocular movements, dysphagia, anæsthesia, which may be of the crossed type, astereognosis in rare instances, painful affections of the trigeminus and vasomotor and thermic changes.

The chief symptoms of tumors of the quadrigeminum are impaired sight or hearing or both, paralysis of ocular movements, bilateral or associated, and inco-ordination especially in attempts to walk or stand. Other symptoms have also been recorded, such as nystagmus, automatic repetition of words, and a tendency to move backward or other forced movements. Focal symptoms referable to neighboring parts, such as the cerebellum and the ascending and descending tracts in the pons oblongata may be present and the general symptoms of a neoplasm, such as headache, optic neuritis, vertigo, nausea and vomiting, are usually marked.

As tumors of the cerebellum and the cerebellopontile angle have been discussed elsewhere by the writer and by his colleagues in the preparation of the present series of papers, attention will be directed to cerebellar growths only in the briefest possible manner. It should be remembered that an accessible parietal tumor may give ataxia as one of its prominent manifestations, but that a growth giving this symptom is to be differentiated from a cerebellar growth, causing ataxia by the fact that the ataxia is more likely to be confined to the extremities of one side, and especially to one upper extremity in parietal lobe cases, and that in the same cases, astereognosis and impairment or loss of cutaneous and muscular sensibility are usually present, these being absent in a cerebellar neoplasm. I would refer elsewhere, however, for a full consideration of this subject.<sup>1</sup>

---

<sup>1</sup> Tumors of the Cerebellum, New York Medical Journal and the Philadelphia Medical Journal, February 11 and February 18, 1905; reprinted with papers by Drs. Frazier, Weisenburg, de Schweinitz and Ludholz as a monograph.



With regard to the focal diagnosis of brain tumors from such lesions as abscess, hemorrhage and acute softening, from embolism or thrombosis, little need be said. The principles of diagnosis are the same as in the case of tumors. The differences in symptomatology depend chiefly upon the differences in the nature of the lesions, although in the case of hemorrhage and acute softening, the rapidity of development is of some assistance in differentiation. An abscess may cause either more or less pressure than a tumor; probably when entirely confined within the brain substance, less rather than more. An abscess may be extracerebral that is, of the membranes, as for instance when in the middle fossa. In such cases the symptoms will not only be indicative of the physiological area disturbed or injured, but also of dural irritation, and it may be of disturbance of the functions of cranial nerves. The fact that an intracerebral abscess is often latent for a considerable or even a long time needs to be borne in mind. After all the differentiation between abscess and tumor will depend largely upon the history of probable causation, and upon the presence or absence of the indications of sepsis. In the presence of purulent otitis or of some other source of pus, abscess becomes more probable, and yet the diagnosis of abscess must not be reached simply in this way, as I have known not a few instances in which brain tumor was present in cases with the evidences of recent or old aural disease.

With regard to the diagnosis of hemorrhage from tumor the usually sudden occurrence of hemorrhage is an important point; it may also develop more or less slowly. It must be kept in mind that a hemorrhage sometimes takes place during the growth of a tumor, either into its substance or on its borders. I have seen instances of such hemorrhages in cases of gliomata and even of gummata. A point of value in the differentiation of hemorrhage from tumor is that in some cases of brain tumor, although the neoplasm has been long existent, the onset of focal symptoms of diagnostic im-

portance is rapid. This is probably to be accounted for by the brain ceasing after a time to accommodate itself to the new-growth, and also by the sudden or rapid increase of its destructive influence on vascular regions invaded by it. Acute softening from embolism is always sudden, and embolic apoplectiform symptoms are of a special type. The presence of endocardial and valvular lesions or of other pathological sources of emboli will of course have great weight in diagnosis. In softening from thrombosis, which may be sudden or rapid in onset, although the changes in the vessels leading up to the attack may have been long present and increasing, the absence of the general symptoms of brain tumor and of the pressure and irritation symptoms are important.

The diagnosis, focal and general, of brain tumor from general paresis is sometimes difficult; it is especially so in cases of prefrontal tumor. In several instances I have hesitated and postponed operation because of this difficulty. In certain cases of general paresis, as is well known, the symptoms are of a quiet or apathetic type. The patient does not exhibit the extravagant optimism of the typical parietic. In a few cases most of the decisive spinal and cranial physical symptoms, such as changed knee-jerks, ataxia, and disturbances in the iritic reflexes, may be absent. The scene is dominated by dementia showing itself in loss of memory, disorientation, impaired judgment and lack of self-control. The speech disorders are never entirely absent, but unfortunately in the case of a prefrontal and midfrontal growth these may be present. In such a case the general symptoms of brain tumor if present are of the greatest value, but one or even all of them may be absent and yet a neoplasm be present. It is sometimes necessary to wait in such cases for the development of aphasia and agraphia if the tumor is left sided, or for Jacksonian epilepsy and parietic symptoms if right sided.

## REMARKS UPON THE SURGICAL ASPECTS OF OPERABLE TUMORS OF THE CEREBRUM.<sup>1</sup>

BY CHARLES H. FRAZIER, M.D.,

*Professor of Clinical Surgery, University of Pennsylvania;  
Surgeon to the University Hospital.*

---

DURING the past decade there has been a renewal or revival of interest in the surgical aspects of tumors of the brain, chiefly because of the frequent failure even to find the tumor the earlier attempts were attended with disheartening results and there was a period in which surgical therapy was abandoned almost as a means of affording relief for patients affected with brain tumors. At the present time, however, there is a widespread activity in this field of surgery and the many problems relating thereto are being carefully studied and freely discussed. As a result of this renewed activity the surgery of brain tumors is established upon a much more exact basis, the indications for or against surgical intervention are more clearly defined, the methods of dealing with the great variety of conditions, at first somewhat perplexing, are more clearly understood, and the details in technique have been so elaborated that the operation can now be performed with but slight risk to the patient's life and the prospects of improvement or recovery are very much greater. We have still, however, much to learn, and the results which have been attained thus far are still far from ideal. Dr. Mills has dealt in his paper with what might be said to be the most important phase of the whole subject, namely, the diagnosis, since it is

---

<sup>1</sup> This paper was prepared as a sequel to the paper of Dr. Charles K. Mills upon "The Focal Diagnosis of Operable Tumors of the Cerebrum," published in the UNIVERSITY OF PENNSYLVANIA MEDICAL BULLETIN for April-May, 1906.

only by the early recognition of the presence of a tumor that we can hope to increase the percentage of operable tumors and thereby the percentage of cures. This paper will be devoted chiefly to a discussion of questions pertaining to the technique, and the views expressed are the result of my observations in a large number of cases which, especially through the courtesy of Dr. Charles K. Mills and Dr. William G. Spiller, I have operated upon at the University Hospital during the past five years.

**THE OPERABILITY OF TUMORS.** Walton and Paul<sup>1</sup> made a study of the clinical and postmortem records of 424 cases, many of which were observed by themselves or their immediate colleagues. They divided their cases into (1) operable tumors, under which head they include the primary, accessible, well-defined tumors which may be removed without cutting the brain tissue, springing in the great majority of cases from the dura; (2) inoperable tumors, including those involving deep-seated structures, the basal ganglia, the pituitary body or the middle lobe of the cerebellum, extensive infiltrating gliomata and most cases of multiple growth and metastasis; and (3) doubtful cases, including gliomata and non-encapsulated sarcomata in accessible regions, and many subtentorial tumors and cysts which can simply be evacuated. Of the four hundred and twenty-four cases, they classed thirty, or 7 per cent., as operable; three hundred and thirty-eight, or 80 per cent., as inoperable; and fifty-six, or 13 per cent., as doubtful, the combination of operable and possibly operable reaching to 20 per cent. By eliminating cases in which metastasis or infection was present and cases without diagnostic symptoms, the number of operable cases was reduced to fourteen, or 3.3 per cent., and the doubtful to thirty-four, or 80 per cent.

The term operable would seem to be made practically synonymous with curable by Walton and Paul; it should have

<sup>1</sup> G. L. Walton and W. E. Paul, *Journal of Nervous and Mental Disease*, vol. xxxii., August, 1905.

a wider significance than this, that which is partly given to it under their designation of doubtful cases. Any case of brain tumor which can be reached and wholly or partially removed with subsequent benefit to the patient should be regarded as operable, remembering that we are in the presence of a disease almost absolutely fatal without operation.

A few sources of fallacy may be present in statistical studies like those of Walton and Paul. In the first place their conclusions are drawn from a study of cases which came to autopsy. No criticism is to be made upon this fact, as it is only by a study of such cases, and those in which operation has been actually performed and the tumors reached, that we can get positive data for our guidance; but the size and radiations of tumors found at necropsies are different in many cases from their size and extensions at the time when operation should be taken into most favorable consideration. Again and again I have seen on the postmortem table a brain tumor which would have been inoperable a short time before death, but which might have been entirely removed a few months or a year or two previous. This is true especially of dural tumors which have grown and destroyed brain tissue by invasion and obliteration of vessels, and also to a less extent of infiltrating tumors.

In rare cases small tumors of the middle lobe of the cerebellum, if operated sufficiently early, might be removed, although not after they have extended so as to form connections with inaccessible regions. The period of the development of the tumor has therefore considerable to do with its operability wherever situated.

Distinct advantage may result to the patient, as I have seen, from the evacuation of cerebral cysts, although such benefit is not always derived.

A point of much practical importance in the settlement of the question of the operability of a brain tumor, or rather of the advisability of operating, is that which is based upon the question of what the operation is expected to accomplish.

Operation should be advised in every case in which relief from suffering for any considerable period can be secured. In a few cases, tumors of the brain can be so completely removed that the patient may be regarded as cured; in a few others the growth can be removed in whole or in part with chances in favor of its return, but with great temporary benefit to the patient; in a third class of cases operations beneficial in relieving the painful and distressing symptoms of the disease, although the growth cannot be removed at all. Cerebral tension and irritation are diminished in this class of cases, and blindness from optic neuritis is often prevented, relieved, or deferred.

Of the operable cases the most accessible, and therefore, those which promise most success, are the tumors which arise and develop on the lateral aspect of the cerebral hemisphere the growths with which this paper is particularly concerned.

So much as has been said thus far as to the operability of tumors has had to do chiefly with their accessibility and inaccessibility. A word or two might be said with reference to the nature of the growth. If the tumor is found to be very vascular and of the infiltrating type, it is very questionable to my mind as to whether any attempt whatsoever should be made to extirpate it. If the tumor is not encapsulated, it is impossible to tell how much tissue should be removed and there is always a likelihood of a portion of the tumor being left behind. In the performance of operations for the removal of malignant lesions in any part of the body, it is a well-known clinical fact that if the operation is imperfectly performed the tumor begins to grow at a very much more rapid rate than prior to operative interference. In addition to this the hemorrhage which occurs upon attempts at removal of very vascular growths is most profuse and of such a character that it is very difficult and sometimes impossible to control unless one resorts to so formal a procedure as closure of the carotid arteries. This of itself may deter.

mine a fatal issue. For these reasons, therefore, I am disposed to include among the inoperable class of tumors not only those which are found to be inaccessible but also those which are of the type already described. No matter which operation is performed the condition must be regarded as an incurable one and there is no question but that the patient will enjoy a period of relief quite as long if not longer, and quite as free from distressing and annoying symptoms, when a simple decompressive operation is performed. Furthermore, the chances of recovery from the immediate effects of the operation are very much greater, of course, after the palliative than after the radical procedure. The mortality after simple decompressive operations in which no attempt is made to remove the tumor should be very low.

TECHNIQUE OF CRANIOTOMIES. In the great majority of our cases the following technique was observed: the day before the operation, the patient's head having been shaved, the shape of the flap to be reflected was carefully mapped out by certain craniometric lines, usually the Anderson-Makin lines, at first with an aniline pencil and then with a stick of nitrate of silver. In the course of two hours the nitrate of silver lines will be sufficiently fixed to prevent their being rubbed out during the disinfection of the scalp. A word or two might be said at this juncture as to the desirability of mapping out a flap according to a reasonably accurate craniometric method. I have heard it said that it is entirely unnecessary, for example, to determine the position of the central fissure with relation to the scalp before operating for the purpose of exposing the motor area; that with a little experience one should be able at a glance to tell in a general way the position of the fissure. One has but to familiarize himself with the marked variations in the position of the fissure in heads of different shapes to realize how impossible this would be. If we turn, for example, to the admirable studies of Frierip it will be seen how variable the position of the fissure is in relation to the external auditory meatus. I

have selected the ear or the external auditory meatus as an example, because the available illustrations demonstrate this point. In some cases the fissure is entirely behind the line of the external auditory meatus, in some the fissure crosses it and in some it is almost in front of it. In answer to this argument one might say that if a large enough area is exposed, if the flap is big enough, one can be sure of exposing the entire motor area. That is perfectly true, but there are many reasons why an unnecessarily large flap should not be made. The motor flap, which I am in the habit of making, measures from three and one-half to four inches in width; if because of uncertainty as to the precise position of the fissure an inch and one-half or two inches were added to the width, which is a reasonable allowance to make, the flap would measure five and one-half to six inches in width. While it is quite possible to reflect a flap of these dimensions, and even a larger one if need be, such a procedure is quite as unjustifiable as the making of an incision in the abdominal wall six inches long, when one three inches long would answer the purpose quite as well.

There are other reasons, however, for determining before the operation the position of the region which it is desired to expose. If this precaution is not taken it is quite possible that the operator might fail to expose the lesion. Tumors are not always situated entirely within the regions to which the symptoms are referred. A tumor might only encroach but a little upon the motor area and yet give rise to motor symptoms. If the opening were half an inch or an inch too far backward or forward it might fail altogether to expose the tumor.

To return from this divergence to the technique, the patient is placed upon the table, secured in the manner to be described, the anæsthetic, ether, is then administered by the assistant anæsthetist. The chief anæsthetist disinfects his hands as thoroughly as though he were going to participate in the operation, puts on a sterile gown and gloves and does



not take charge of the anæsthetic until the patient's scalp has been disinfected and the operation is about to begin. These regulations regarding the anæsthetist are really important, though seemingly insignificant, because the hands of the anæsthetizer are so near the field of operation that there is always the possibility of their coming in contact with the instruments or objects that may be employed during the course of the operation. Prior to the beginning of the anæsthetic an observation is made of the blood pressure, and this is repeated at intervals of five minutes or oftener. The table is now elevated, and as the incision is made the assistant makes firm pressure at the base and sides of the flap for the purpose of controlling bleeding until a few hæmostats may be applied. A small opening is made in the skull with the burr or chisel and the bone divided with the spiral steotome. In some cases, particularly if the bone is unusually thick, the base of the flap or the bridge of bone between the two extremities of the incision is partially divided with a Gigli saw, but in the majority of cases this bridge of bone is broken across by elevating the flap. When this has been accomplished a piece of gauze is wrapped around the osteoplastic flap and allowed to remain there until the end of the operation. I insist upon this because of the possibility of the bone in the flap being denuded of its periosteum and the overlying scalp, thus depriving the bone of its blood supply and necessitating its removal. The dura is then inspected, the presence or absence of adhesions and of pulsation of the brain noted. The absence of pulsation is always indicative of increased tension, which may be due to a large cyst, tumor, abscess or internal hydrocephalus. After the dura flap is reflected, by making an incision about one quarter of an inch from the margin of the bone, the appearance and consistency of the cortex is noted. A rapid survey is made of the exposed field for any pathological condition that may be detected by sight or by delicate palpation; there may be an increased consistency of the cerebral tissue, as in the presence of a tumor, or

diminished consistency and a sense of fluctuation, as in the presence of a large cyst or an internal hydrocephalus; abnormally dilated veins or opaque milky streaks along the course of the pial vessels or any variation from the appearance of normal brain tissue should be noted.

It is important to note whether the brain bulges through the opening once the dura is removed. Bulging of the brain may sometimes be the most troublesome feature of the operation. We should distinguish between what might be called "initial" bulging, or that which occurs immediately after reflection of the dura, and "consecutive" bulging, or that which manifests itself during subsequent exploratory manoeuvres. The initial bulging is indicative of the presence of considerable increase in the intracranial tension, such as might be due to internal hydrocephalus or the presence of a large tumor. This however, is not invariably the case; a tumor may be present and yet there may be little or no "initial" bulging. To illustrate this I could cite the case of a cortical sarcoma of moderate dimensions and another of a large subcortical tumor in neither of which was there any initial or consecutive bulging. Naturally, however, the character of the tumor has to be taken into account; thus a very vascular sarcoma would be more apt to bulge through the opening than a gumma. The release of pressure from a growth abounding in large vascular channels would result in a reactionary dilatation, more particularly of the venous channels, and this in turn might be followed by such circulatory disturbances as would readily lead to cerebral œdema. During the course of the exploratory manipulations the brain may bulge to an inconsiderable degree through the opening, even when the tumor is not found, or if present, is not situated at or beneath the area exposed. This consecutive bulging is due no doubt to the traumatism of a greater or less degree inflicted by the exploratory measures and to the exposure of the brain surface to the injurious influence of a comparatively low temperature. The swelling

and bulging under the circumstances is no doubt due to œdema; this, as Cannon pointed out in connection with the secondary increase of intracranial pressure in head injuries, is the result not of any increase of blood pressure but of certain chemical changes in the brain substance itself, whereby the osmotic pressure is so increased that the brain becomes rapidly œdematous.

The subsequent steps vary according to a number of circumstances. If nothing abnormal has been found by this preliminary examination the question of further exploration is then considered. (This is a matter of so much importance that it will be treated more at length under a separate heading.) This consists in either an incision into the cortex, where there is an evident increase in the consistency of the brain or in the introduction of a special exploratory canula where there is reason to suspect a cyst, abscess or internal hydrocephalus. When the exploration is concluded and the lesion, if found, appropriately treated, preparations are made to close the wound. Hemorrhage from every source should be checked as far as possible: from the cerebral veins whenever possible by ligation, otherwise by tamponade, and from the bone by Horsley's wax. There will always be a certain amount of bleeding or oozing, and to prevent the formation of a hæmatoma beneath the flap adequate drainage must be provided. The flap is replaced and the edges of the wound united by interrupted silkworm-gut sutures. These sutures, if properly introduced, will control bleeding from vessels in the scalp, thus providing the necessity of applying ligatures.

Drainage is provided by introducing a strip of rubber tissue through two counteropenings, one just in front and the other just behind the flap. Whatever oozing there may be will be spontaneously arrested within twenty-four hours. The drainage may be removed then or at the end of the second day, when the stitches are removed and a collodion dressing applied. The patient is not confined to bed more than

three or four days unless the operation has been an unusually severe one.

**SUBCORTICAL GROWTHS AND THE LIMITS OF EXPLORATION.** One of the most difficult questions, and one which must be decided during the course of an operation for the exposure of a tumor, is the question of exploration for subcortical growths. Given a case in which, when the dura is reflected, the tumor is not visible to the naked eye, should the case be regarded as inoperable and an attempt to find the growth be abandoned, or should we proceed to further exploration with the hope of exposing and removing a subcortical growth. Referring again to the statistics of Walton and Paul it would appear that the field for surgical intervention in brain tumors was a very limited one. According to Walton and Paul the tumors, which were operable, took their origin from the dura itself or were purely cortical tumors; in either instance they were visible to the eye of the surgeon as soon as the dural flap was reflected.

Of the tumors, which were not in either of these positions, the majority were so situated that they would not have been exposed by the usual exploratory incision or puncture that is made in the cortex. Codman (*Boston Medical and Surgical Journal*, July 20, 1095), after reviewing the records of operations for brain tumors, even goes so far as to suggest that we should be satisfied in every case with a purely palliative operation. An opinion so radical as this should not for a minute be entertained. I would advocate an exploratory incision, one or more, to the depth of at least one centimetre in every case in which the tumor does not appear in the cortex. Such a procedure is in itself comparatively free from danger, and if, from conservative estimates, there is but one chance in fifteen or even twenty of finding the tumor, the patient should be given the benefit of this chance. I know of one case in which the operator, failing to find a cortical growth, declined to search for the tumor. The patient died shortly after the operation and a small, quite

operable growth was found just beneath the cortex, so near the surface in fact that it would have been exposed by a very trivial incision. If a tumor has been accurately localized and the flap carefully mapped out we can be reasonably sure that it is situated in that portion of the brain that lies within the margins of the opening and should not hesitate to make one, two or more exploratory incisions in the cortex. To abandon altogether, as Codman suggests, what might be called the radical operation for the palliative one, would, I believe, be a retrograde step in the development of cranial surgery. There are certain cases in which it is possible beforehand to determine the precise position of the tumor, or in which the tumor is believed to be inaccessible, when no other course may be left to the operator than to perform a palliative or decompressive operation, but in all cases an attempt should be made to expose the tumor. A flap should be reflected in the region, in which it is believed to be situated, and an exploratory incision should be made in the cortex if the tumor be not visible upon the surface.

ANÆSTHESIA. All the operations, which I have performed, were carried out under general anæsthesia and in every instance ether was the anæsthetic. Theoretically, chloroform might be preferred because, by lowering blood pressure, it might diminish the amount of bleeding, but its depressing effect upon the circulatory apparatus should of itself constitute not only a serious objection but a positive contraindication. In many cases of brain tumor, particularly those large enough to increase intracranial tension, disturbances of the cardiac and respiratory mechanism during the course of or immediately after the operation are not uncommon accidents. It is most important, therefore, that no drug be used which has a distinctly depressing effect upon either of these vital functions. For this reason, I have preferred not to use morphine-scopolamine anæsthesia. An hypodermic injection of one-sixth of a grain of morphine may be given fifteen minutes before

beginning the administration of the anæsthetic, and there are no objections, so far as I know, to using ethyl chloride preliminary to the ether. Whatever may be the advantages in other operations of inducing narcosis with nitrous oxide, it should not be used in operations upon a patient with brain tumor. In the case of very vascular tumors and when there is much intracranial tension the veins are already much engorged; the intense cyanosis attending administration of nitrous oxide would cause still greater distention of the venous channels, so much so as to seriously interfere with the circulation of the brain. Of equal importance with the selection of an anæsthetic is the selection of an anæsthetizer. Except in cases of emergency the administration of the anæsthetic should not be entrusted to any but experienced hands. We are dealing with a class of patients who, as a rule, are not the best subjects for operative intervention, and who, therefore, demand the attention of a reliable anæsthetist. The condition of the patient must be watched with the greatest vigilance throughout the operation, and the operator himself should feel such absolute confidence in his anæsthetizer that his attention need not be distracted at any time from the field of operation. Whatever there is to be said of the desirability of having a regular anæsthetizer attached to operative clinics may be said with even greater force when the operation is to be performed upon the cranial cavity.

**POSITION OF THE PATIENT.** As a means of controlling hemorrhage, even though to a very slight degree, it is advisable to operate with the head of the patient somewhat elevated. In order that the patient may not slip down on the table during the progress of the operation, the patient is strapped to the table by a web belt which is passed under the table and over the patient's legs just below the knees. The table is then raised to an angle of thirty-five degrees. I have found it convenient in all operations upon the head to use a head rest which is especially useful in operations upon the posterior portion of the skull. All the necessary manipulations on

the part of the operator and his assistants may be carried out with very much greater freedom, when the head projects on this rest beyond the edge of the table.

**HEMORRHAGE.** Considerable attention has been paid to the effect of hemorrhage during the course of operations upon the cranial cavity. As a rule, the amount of blood which escapes from the wound in the scalp and cranium is not sufficient to have any deleterious effect. Rubber tubing or inflatable tubing may be applied around the head as tourniquets, but neither of these have proven satisfactory in my earlier operations and I have come to depend solely upon the use of hæmostatic forceps. While the scalp incision is being made and the section made in the bone the assistants should be instructed to make pressure with gauze pads at the base




FIG. 1.—Nicholson's hæmostatic forceps.

and around the margins of the wound, since by this simple precaution a considerable amount of the hemorrhage may be controlled. Dr. Nicholson has had manufactured for his own use a set of hæmostatic forceps (F g. 1), with broad blades, so constructed that the scalp in its entire thickness could be grasped and hemorrhage controlled until the operation is completed. The suggestion made by Heidenhain is a very excellent one and consists in the introduction of a precutaneous ligature through the entire thickness of the scalp surrounding the area in which the flap is to be made. I have never used this method myself, but in a letter recently received from Theodor Kocher, of Berne, he refers to Heidenhain's method as very efficacious.

So much for hemorrhage from the scalp; hemorrhage from

the diploic sinuses may be satisfactorily controlled by plugging the sinuses with Horsley's wax. When engaged in the removal of a vascular tumor hemorrhage is very profuse and often alarming. It is a question whether any attempt should be made to remove these very vascular and usually infiltrating growths when of large dimensions; the immediate danger to life is great and the inability to determine precisely the limitations of the growth leave one always in doubt as to whether the tumor has been entirely removed. These are cases in which we should be satisfied with such palliative measures as can be derived from a decompressive operation.

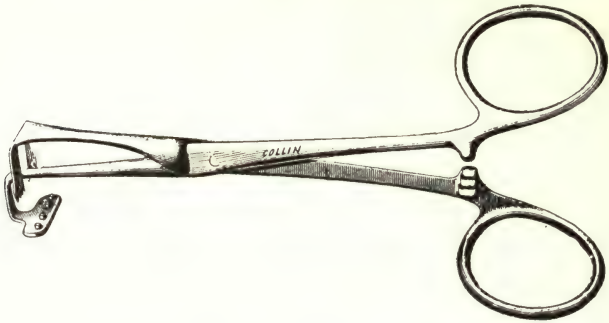


FIG. 2.—Howzel's hæmostatic forceps. (From Marion's *Chirurgie de Système Nerveux*.)

However, when the attempt has been made and the bleeding is profuse but two courses are open, gauze tamponade or temporary closure of one or both carotid arteries. Crile, to whom we are indebted for this suggestion, performed this preliminary operation in a series of operations without any serious ill effects. It seemed to me that if as in Crile's hands the operation were entirely free from danger a very important contribution had been made to the technique of cerebral surgery. Unfortunately, however, the danger of cerebral thrombosis resulting in death or in a hemiplegia is not an imaginary one, after ligature of one or the other carotid arteries, nor is it after only temporary closure. Unfortunately,



too, closure of the carotids does not control hemorrhage entirely, the venous hemorrhage which is often the most troublesome is little, if any, affected. My own experience has been limited to six cases, two of which were excisions of the superior maxillary bone, the others brain operations, but from this limited experience, I should say that we should resort to this operation only in the most extreme cases and then apply it to one but not to both common carotid arteries. If copious hemorrhage is anticipated it is a good plan to expose the artery on the affected side as a preliminary measure, so that if the emergency arises a clamp may be applied immediately. Whether or not the patient is suffering any ill effects from hemorrhage, during the course of the operation, may be determined by observing the blood pressure. The sudden withdrawal of a large amount of blood from the system will have a deleterious effect by disturbing both directly and indirectly the circulatory apparatus. The latter may be detected by noting the condition of the blood pressure; if hemorrhage has been profuse and the blood pressure is falling, steps should be taken at once to replace the amount of circulatory fluid lost either with normal saline solution or a 1:50,000 adrenalin-saline solution. If the blood pressure has fallen but little the plain saline solution will suffice as a rule to restore the circulatory apparatus to its normal state; in cases, however, where the blood pressure is rapidly falling and signs of shock are impending adrenalin should be added.

Apart from the effects of hemorrhage upon the patient's general condition Dr. de Schweinitz has called my attention to the fact that in certain instances, as in a case recently operated upon, the choked disk, although it may eventually subside, may be increased somewhat after the operation. This he attributes to the effect of hemorrhage.

**OBSERVATIONS UPON THE BLOOD PRESSURE.** It has been our custom in all cranial operations to have observations made upon the state of the blood pressure with the Stanton modification of the Riva-Rocci instrument. During the past

three years we have accumulated a large number of blood pressure charts from which a great many interesting observations could be made. These will be treated more at length in a subsequent paper. These observations were instituted as a routine procedure, because the condition of the blood pressure is the most reliable index of the patient's condition. When the normal or approximately normal blood pressure is sustained throughout the operation we are assured that the operative procedures have not been of sufficient gravity to induce shock. The blood pressure record will determine whether a sufficient amount of blood has been lost to seriously embarrass the circulation and to require the immediate use of restorative remedies, particularly normal saline solution.

The blood pressure record is the most reliable guide when considering the question of performing the operation in one or two stages. Horsley recommends the adoption of the two-stage operation in every case, without exception, and von Bergmann in cases in which the patient's general condition is below par or in which the tumor is a particularly large one. With neither of these opinions am I entirely in accord. This question should not be decided until the preliminary stages of the operation have been completed. If after the flap has been reflected and the tumor exposed the patient's condition, as indicated by the blood pressure, is entirely satisfactory there is no reason whatsoever why one should not proceed to remove the tumor without any further delay. In the accompanying chart (Fig. 3) one sees how the normal blood pressure was maintained throughout the entire operation. It was a case in which a fibrosarcoma was found and removed almost two years ago, and the patient has remained up to the present time, as far as anyone can tell, free from recurrence. In this case it would have been folly to have postponed, until a subsequent time, the removal of the tumor. Not only is it unnecessary, therefore, in cases in which the circulation is not seriously disturbed or embarrassed to divide the operation into two stages, but it may be

distinctly harmful. Codman (*Boston Medical and Surgical Journal*, July 20, 1905) found from his study of the records of cases operated upon in the Massachusetts General Hospital that an unusually large proportion of cases died from sepsis, and he believes that the two-stage operation may be partially responsible for this complication. This deduction is a reasonable one, and should be given due consideration in determining upon the advisability of operating in one or two stages.

In many cases of brain tumor the condition of hypertension has been noted; this may, however, be due to cerebral lesions other than tumors, as, for example, in cases of large intracranial hemorrhage, either epidural or subdural, and, as we have noted, in cases of cerebral abscess and tuberculous meningitis. Hypertension, however, is not invariably associated with the presence of a tumor. If the tumor is a small one, or if it is of slow growth, infiltrating and destroying the brain tissue as it increases in size, the intracranial tension will not be increased and there will be no corresponding rise in blood pressure. That the intracranial tension may be relieved by a decompressive operation has been demonstrated by the fall of blood pressure which follows this procedure. This phenomenon is noted even if no incisions have been made in the dura, or if made, have been immediately closed with sutures.

Of further interest have been the observations which were made upon the blood pressure in connection with certain procedures other than the removal of tumors. At one time it seemed to me that the circulatory disturbances, particularly the rapid increase in the rate of pulse, was the result of the sudden relief of intracranial tension following the removal of a tumor or some similar procedure. This phenomenon is more conspicuous in operations upon the cerebellum and is often associated with a fall in blood pressure. Circulatory embarrassment, occurring as a complication of cerebellar operations, is very much more readily explained, owing to the

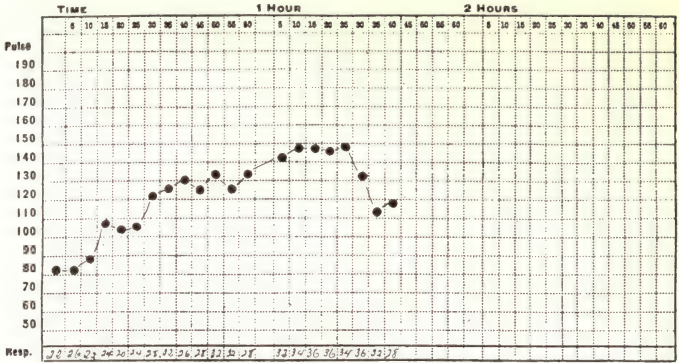
# ANESTHESIA AND BLOOD PRESSURE RECORD.

NAME

HOSPITAL *U. of P.*

INDEX FILE NO. *624* VOL.

## ANESTHESIA CHART.



Operation *Cremiectomy*  
 Operation Started *1:40 PM*  
 Anesthetic *Ether.*  
 Variety *Squibb's*  
 Time to Anesthetize *15 min.*  
 Examination of Chest (before)

Date *5-21-'04*

Operation Ended *2:55*

Method

Amt. to Anesthetize *f3vi*

Operator *Dr Frazier.*

Anesthetizer *Dr Asher.*

Total Amt. Used *f3x*

## BLOOD PRESSURE CHART.

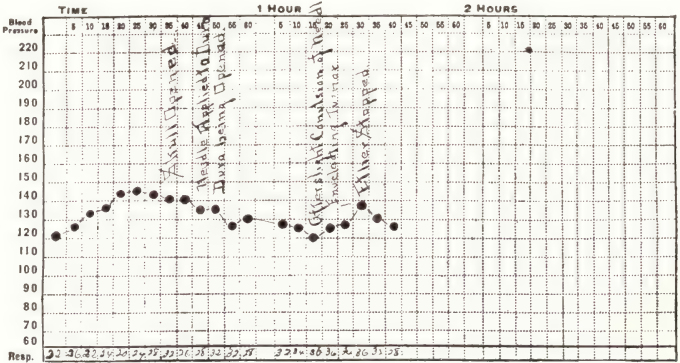


FIG. 3.—Normal blood pressure maintained throughout operation and unaffected by enucleation of tumor. Note disproportion in rate of pulse.

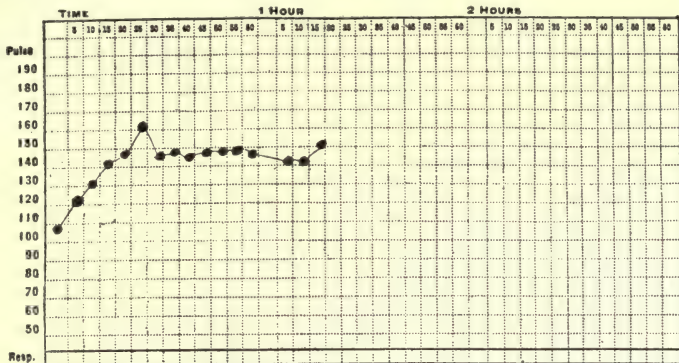
# ANESTHESIA AND BLOOD PRESSURE RECORD.

NAME

HOSPITAL

INDEX FILE No. 1207 VOL

## ANESTHESIA CHART.



Operation **CRANIOTOMY** Date **3.15.06** Operator **DR FRAZIER**  
 Operation Started **5 11 P.M.** Operation Ended **6.23 P.M.**  
 Anesthetic **ETHER**  
 Variety **SQUIBBS** Method **GAUZE** Anesthetizer **DR ASHER**  
 Time to Anesthetize **12 MIN** Amt. to Anesthetize **3 ii** Total Amt. Used **3 iv**  
 Examination of Chest (before) **NEGATIVE**

## BLOOD PRESSURE CHART.

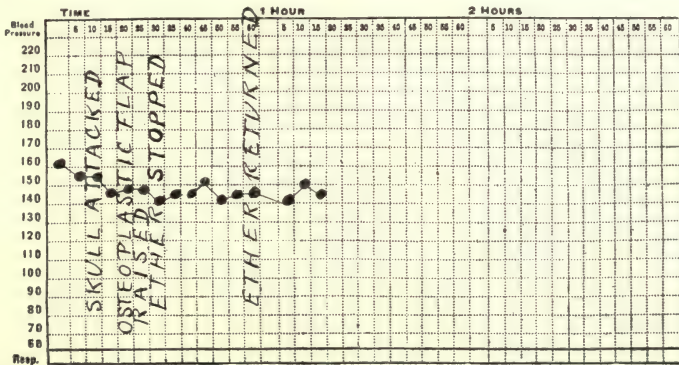


FIG. 4.—Note unusually rapid rate of pulse while the blood pressure is maintained at or about 140.

proximity of the medulla oblongata to the field of operation. In operations upon the cerebrum, however, we have been somewhat surprised to note the negative results, in so far as concerns the blood pressure, attending the evacuation of large cysts or abscesses, or even the opening of distended ventricles. I have at hand a number of charts in which the blood pressure is seen to be unaffected by any of these procedures.

It may be of interest in this connection to call attention to the absence of any relation between the rate of the pulse and the state of the blood pressure. In a great many of our cases the rate of the pulse increased very rapidly almost immediately after the operation began. This increase in the rate of the pulse seems to be altogether out of proportion to the gravity of the operation, especially when it appears before the brain has been explored (Fig. 4). Whatever may be the cause of this phenomenon, there is as a rule no accompanying fall of blood pressure. It is needless to say that the rate of the pulse may have no influence upon the blood pressure, but unless the condition of the blood pressure was known in the course of the operation a good deal of anxiety might arise in the mind of the operator when the rate of pulse increases rapidly to one hundred and fifty, sixty or seventy. Yet I have never seen a case in which there was cause for alarm, unless the warning had first been given by a fall in the blood pressure. If the tachycardia is unassociated with a hypotension there is no necessity for resorting to stimulation. After the operation is concluded the pulse will gradually return to normal.

**VARIOUS METHODS OF EXPOSING TUMORS.** It is not my purpose to describe all the methods of opening the skull for the exposure of underlying lesions, as a complete list of them may be found in surgical text-books. I will refer to but a few of them, and to those only which are employed in the important clinics of this country and Europe. Unless in the performance of a palliative operation, when the permanent

removal of bone is clearly indicated, the trephine is no longer used for the purpose of exposing tumors. The advantages possessed by Wagner's osteoplastic flap are so great as to prohibit the use of an instrument such as the classical trephine, which leaves a permanent defect in the skull. As to the ways of making a Wagnerian flap, I shall refer only to a few:

1. *Mallet and Chisel*. When Wagner first described his osteoplastic resection of the skull in 1889 he used the chisel and mallet. Since that time so many superior instruments have been introduced into the surgeon's armamentarium that the chisel and mallet have practically been discarded. As compared with any other methods this can be said of a certainty to have no advantages while possessing unquestionable disadvantages. Not only does it require very much more time to make the opening, but meanwhile a degree of traumatism is being inflicted upon the brain, which is, to say the least, undesirable.

2. *Craniotomies*. Various instruments have been devised for making sections of the skull with greater expedition than is possible either with the chisel or with a Hey or Doyen saw. The simplest of these is Dalgren's craniotome or forceps (see Fig. 5), with which a flap of any size or shape may be made after an opening has been made in the skull either with a burr or trephine. When operating upon a thin skull this instrument should give entire satisfaction, and has the advantage over others in that the opening in the skull may be made of any shape that may be desired (Fig. 6). Of the other craniotomes, which resemble each other in the principles of construction and method of operation, one was devised by Codivilla (*Revue de Chirurgie*, 1900, tome ii. p. 646) and one by Stellwagen (*Annals of Surgery*, July, 1902). The method of operating these instruments is very similar: in the case of the Codivilla craniotome the saw is operated through the medium of a moderately long shaft, and in the case of the Stellwagen instrument through the medium of a handle similar to that of a trephine. Both these instru-

ments possess many admirable features; their simplicity of construction, the ease with which they can be sterilized, manipulated and regulated to cut skulls of various thicknesses and openings of various dimensions, the possibility of operating them without the aid of a motor, make them very serviceable instruments. They are comparatively inexpensive and are perfectly safe in the hands of inexperienced operators. While not wishing in any way to depreciate the value of these instruments, I prefer other instruments to these, for two reasons: first, because one is obliged to make in all cases a circular opening. In many instances this is unfortunate because a portion of the area to be explored will not be ex-

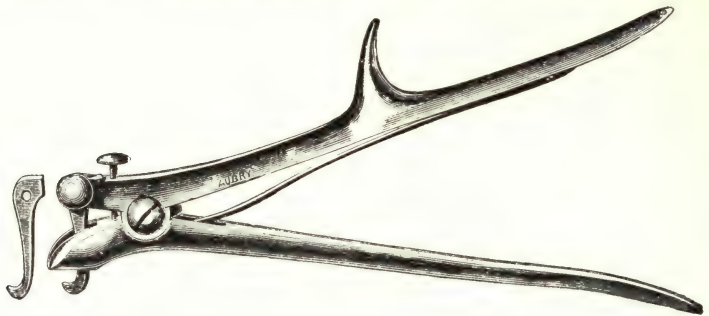


FIG. 5.—Dalgren's forceps.

posed. Thus in exploring the occipital lobe, in order to uncover this lobe entirely, we must expose that portion of the lobe at the angle between the transverse and longitudinal sinuses, but with a circular opening this is impossible. So, too, in any case in which it is desired to explore the region bounded by the longitudinal fissure, a circular opening will "cut corners" and leave a considerable area uncovered. In a general way the lines or fissures dividing the various lobes are comparatively straight and the sides of the osteoplastic flap should run parallel to them, so that the ideal flap is a rectangular rather than a circular one. In the second place, a considerable



amount of blood will be lost during the process of sawing through the bone. The greatest amount of bleeding comes from the venous channels in the diploe; with the Codivilla or Stellwagen trephine one begins to saw through the skull layer by layer from without inward until one reaches the diploe; upon reaching the inner table of the skull, one must proceed more cautiously for fear of penetrating the dura and injuring the brain. Meanwhile, hemorrhage from the diploic

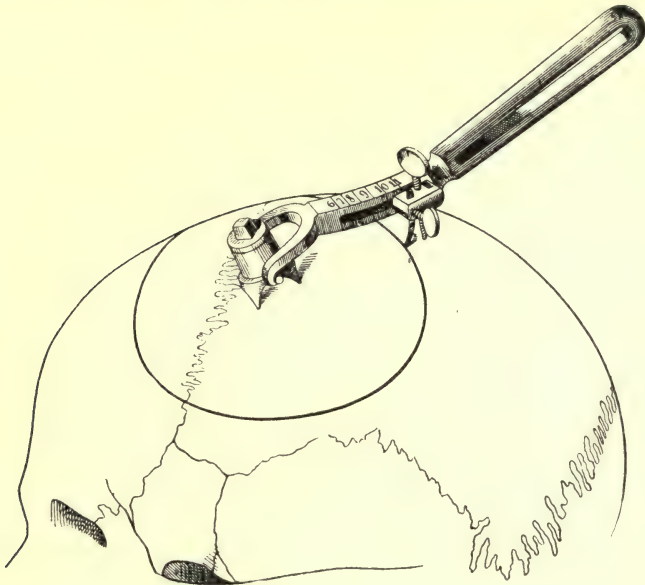


FIG. 6.—Codivilla's craniotome. (From Marion's *Chirurgie de Système Nerveux*.)

vessel is very free, and, of course, uncontrollable until the bone is entirely divided and the flap reflected. The spiral osteotome which we are about to describe divides the entire thickness of the skull as it proceeds; furthermore, it seems to crush and occlude the openings of the diploic sinuses, and in that way tends to arrest hemorrhage.

3. *The Gigli Saw*. Shortly after Wagner (1889) described his osteoplastic resection of the skull, Toison (1891)

suggested that the bone be divided with a saw, between a number of trephine openings, from within outward. The saw which he used for the purpose was a thin flexible instrument, trapezoid on cross-section. In 1897, Obalinski recommended the use of the flexible wire saw—the Gigli saw—as a substitute, and since that time the Gigli saw has been used exclusively for this operation, and various instruments have been devised by Gigli, Lauenstein and others to guide the saw from one opening to the other. A number of openings varying from three to five, according to the size of the flap, are made in the skull with a trephine or spherical burr. To protect the dura and brain from laceration these openings must not be placed too far apart; since the surface of the brain is convex, the saw if stretched across too great a space from one opening to another will of necessity come in contact with, and when in operation cut through, the dura and into the brain. If this precaution is taken the method of Toison and Obalinski is in many particulars an ideal one. The opening in the skull can be made of any shape or dimensions, with little traumatism and in a comparatively short time. The instruments are inexpensive, easily procurable, require no adjustment, and no especial experience or practice in their manipulation.

4. *The Circular Saw and the Spiral Osteotome.* These instruments differ from all others in this essential, in that they are operated by means of a hand or electric motor. In 1895 Doyen introduced his circular saw (see Fig. 7), which is armed with a guide inserted beneath the bone to afford protection to the underlying dura. A similar instrument has been used for a number of years by McCosh. After the incision is made in the scalp, four or five holes are bored through the skull, as in the Toison method, with a cone-shaped burr (*fraise spherique*) about one-quarter of an inch in diameter. When the holes have been drilled the circular saw is substituted for the burr and the bone intervening between the holes sawed through. As compared with any

others previously mentioned the Doyen method might claim superiority solely because it is somewhat more expeditious. The presence of the guide or flange attached to the saw protects the dura, and while the same number of holes must be drilled as in the Toison method there is less difficulty in applying the circular saw, and the bone can be sectioned more rapidly.

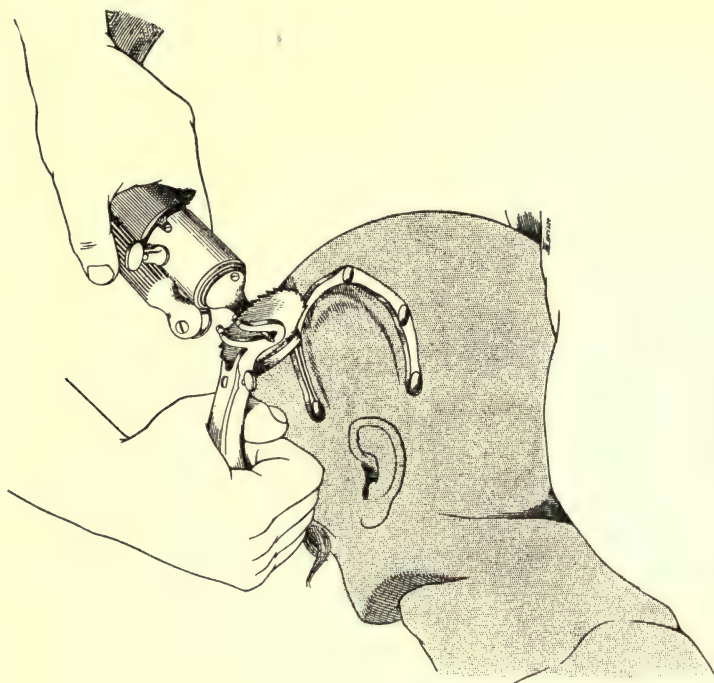


FIG. 7.—Doyen's electrical craniotome. (From Marion's *Chirurgie de Système Nerveux*.)

In 1894 Cryer, then an instructor at the University of Pennsylvania, devised an instrument which he called the spiral osteotome. This was the first instrument operated by a hand or electric motor to be used in the performance of craniotomies. (See Fig. 8.) The instrument is very

simple in its construction and is provided with a flange which protects the dura.

Curiously enough, very little was known of Cryer's instrument, outside of Philadelphia, until 1900, and about this time Sudeck, apparently without any knowledge of the one which Cryer and others had been using for six years devised an osteotome which is identical in every particular. Even at the present time most American surgeons, familiar with the spiral osteotome refer to it as Sudeck's instrument, and this is the name invariably given the instrument in foreign literature. In my clinic at the University Hospital, in the past fifty or more craniotomies, I have used Cryer's instrument because I believe it to possess certain features which make it superior to any other. In the first place it is necessary to make but one opening in the skull, and this can be done

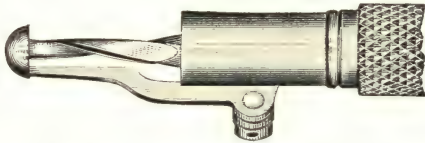


FIG. 8.—Cryer's spiral osteotome.

in a few seconds with the small trephine or burr, instead of three or more as required for some of the other methods, notably Toison's and Doyen's. Secondly, a flap can be fashioned of any dimensions, with straight or curved margins as the occasion demands. Thirdly, the flap can be cut more quickly than by any other method; from the time the drill is introduced until the flap is reflected but a minute or two will have elapsed. That the element of time plays no unimportant part in the outcome of operations upon the subjects of brain tumors I am fully convinced, therefore, preference should be given to the instruments which are most economical as to time.

CRANIOMETRIC LINES AND CRANIOCEREBRAL RELATIONS.  
In the concluding portion of this paper will be described a series of openings which are so arranged as to expose certain

well-defined physiological areas of the brain. The shapes and size of each opening are defined according to our knowledge of certain craniocerebral relations. The variations in the shapes of the skull and in the relation of the fissures and convolutions of the brain to the skull are well known, and at first thought it might appear impracticable if not impossible to outline upon the scalp a flap which would correspond to a given area of the brain. From frequent observations on both the living subject and upon the cadaver I have been surprised to find how frequently the craniometric lines correspond to the fissures and convolutions of the brain. It will be interesting in this connection to allude to some of the conclusions at which Froriep arrived in an investigation of the relations between the brain and the skull (*Die Lagebeziehungen zwischen Grosshirn und Schädeldach*, von Dr. August Froriep). He noted among other things that all the specimens which he examined could be divided into two groups; (1) the frontopetal (Fig. 9), or those in which the greater portion of the brain lies anterior to a vertical line drawn through the external auditory meatus, and (2) the occipitopetal (Fig. 10), or those in which the greater portion of the brain lies posterior to the external auditory meatus. In the first or frontopetal group the central fissure lies with relation to the position of the external auditory meatus farther forward and is more vertical in its course; in the second, or occipitopetal group, the central fissure lies farther back and follows a more oblique course. These two groups however, have no relation to the brachiocephalic and dolichocephalic skulls. It might at first be supposed that the frontopetal brains corresponded to the brachiocephalic skulls and the occipitopetal to the dolichocephalic skulls, but this is not the case. The position of the brain, while not independent of the form of the skull, has no relation with the proportion of the breadth to its length. It was found, however, that while there was no relation between the position of the brain and the relative length and breadth of the skull there was a relation between

the length of the skull and the brain; thus the occipitopetal type of brain was found in the long skulls and the frontopetal type in the shorter skulls. The absolute measurements, as to length, are those upon which the greatest reliance should be placed in any craniometric system. Froriep also found that the position of the brain was more dependent upon the configuration of the *hinterhaupt* than upon any of the diam-

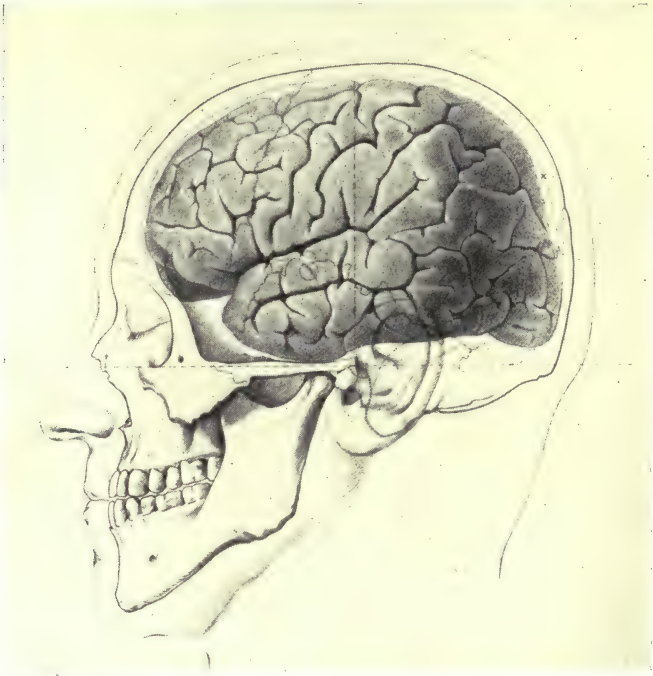

FIG. 9.—Type of frontopetal brain. (After Froriep.)

eters of the skull. The greater the distance between the occipital protuberance and the internal auditory meatus the nearer does the form and position of the brain correspond to the occipitopetal type. It was also noticed that the nearer the brain corresponded to the extreme occipitopetal type the lower the position of the inion.

These observations interest me, especially for two reasons:

first, because he found that the absolute length of the skull could be considered a factor, which took into consideration, variations in the shape of the brain and its relations to the skull; and secondly, because he found that, based upon familiar craniometric methods, there was a variation in the position of the Sylvian or Rolandic fissures of not more than

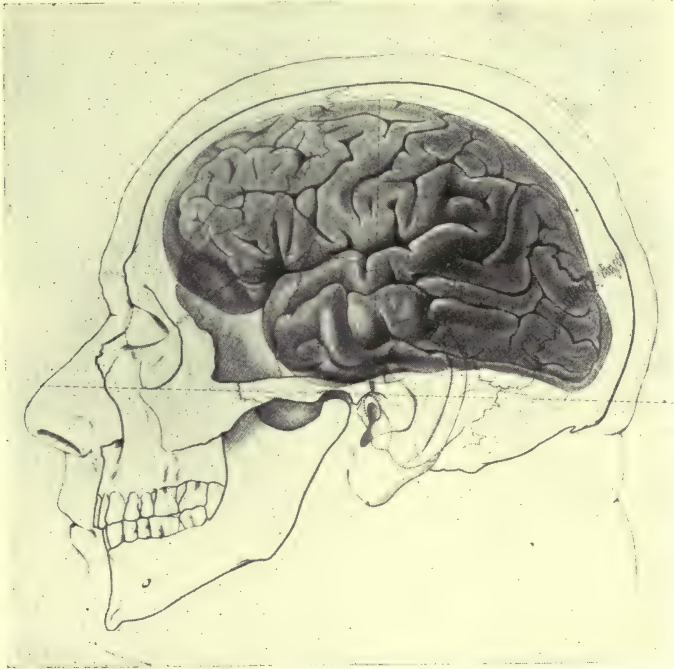

FIG. 10.—Type of occipitopetal brain. (After Froriep.)

35 to 40 mm. between the most extreme frontopetal and occipitopetal types of brain.

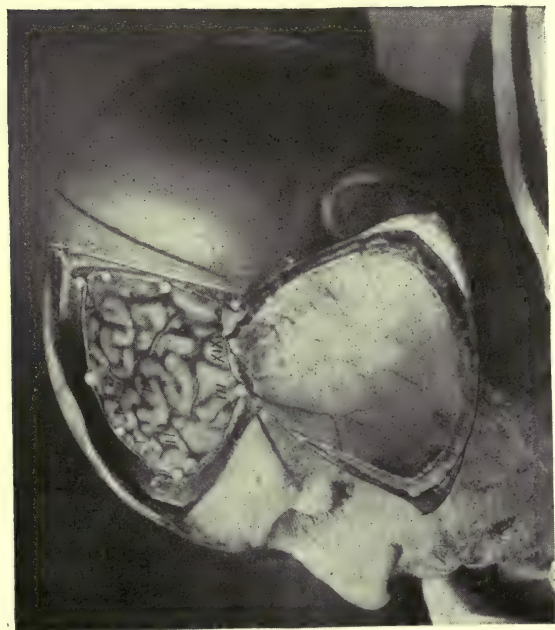The calculations in the Anderson-Makin method, which we have used exclusively for determining the position of the Rolandic and parieto-occipital fissures, are based upon the length of the skull, measured from the glabella to the inion. The upper extremity of the Rolandic fissure corresponds to a point one-half to three-quarters of an inch behind the mid-

point between theinion and glabella. The upper extremity of the parieto-occipital fissure corresponds to a point one-quarter of an inch behind the mid-point between the line of the Rolandic fissure and theinion. If any criticism whatever is to be made upon the Anderson-Makin method it should be upon the rules for determining the direction of the fissure. These taken into consideration the position of the external auditory meatus and the latter we have seen occupies a variable relation to the central fissure in different types of brains. However, there is not a great deal of variation in the direction of the fissure, and if we are reasonably sure of the position of its upper extremity there will be no danger of our failing to expose it, particularly when the posterior margin of the flap is made at least three-quarters of an inch posterior to the fissure.

The illustrations of the various openings, as seen in Figs. 11 to 16, were made from photographs which were taken after the operations, described in the text, were performed upon the cadaver. Before the skullcap was removed pins were introduced around the margin of the openings in order to enable one to determine positively the extent of the area exposed. A photograph was then taken after the skullcap was removed, and in each illustration Roman numerals have been used to indicate the important convolutions included in the opening. In almost every instance it will be seen that the outlines of the flap corresponded to the physiological area of the brain which it was intended to expose.

Tumors of the brain in their earlier stages at least are confined to one of the various physiological lobes or areas of the brain. If there be any localizing symptoms they will point to the tumor being situated in the prefrontal, the midfrontal, the postfrontal or motor, the parietal, the occipital or the parieto-temporal or visuoauditory region. These correspond to the conventional areas recognized by Dr. Mills in his discussion of the diagnosis of cerebral tumors. In the majority of cases, therefore, the surgeon is called upon to



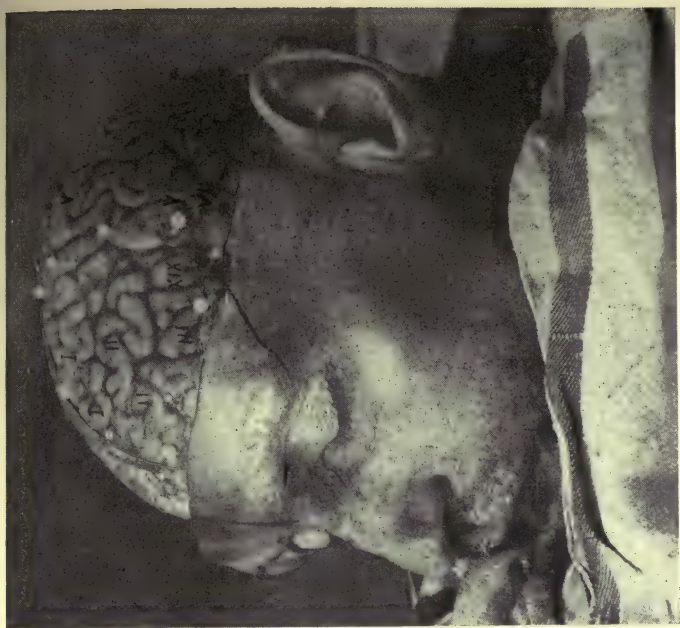

A

FIG. 11, A.—Prefrontal opening, showing relation to Sylvian and Rolandic fissures.

FIG. 11, B.—Area of cortex exposed in prefrontal opening, including (I) superior frontal convolution, (II) middle frontal convolution, (III) inferior frontal convolution, and (XIX) Broca's convolution.

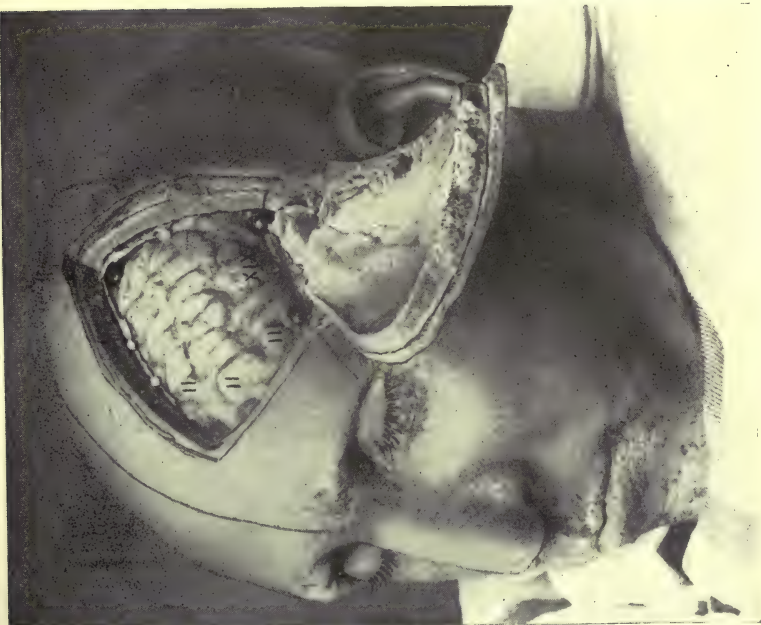
B



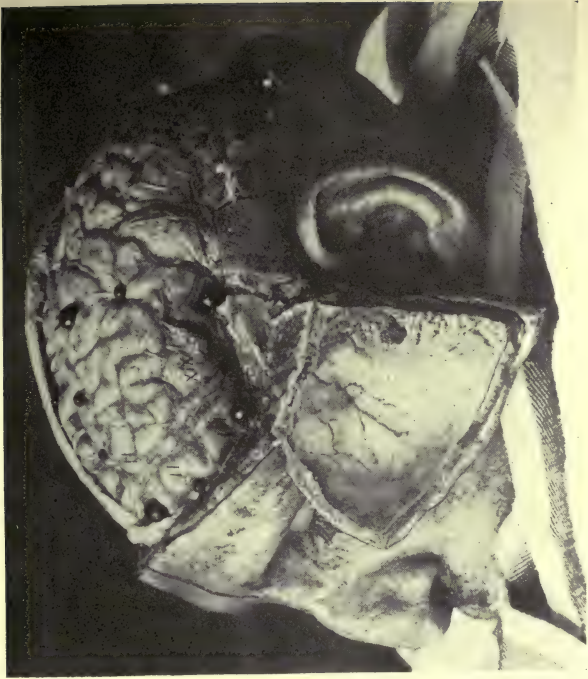
make a flap which will expose a tumor in one or the other of these regions. For these six conventional regions, therefore, we have six conventional openings. I shall describe these openings seriatim, with the aid of illustrations, and refer briefly to the history of one case for each opening.

1. PREFRONTAL OPENING. The frontal lobe, according to the usual acceptation of the anatomist, comprises on the lateral aspect of the cerebrum all that region between the cephalic extremity of the brain and the central fissure. That it is a region of high functional value is understood when it is recalled that it is subdivided into at least three great physiological areas, namely, a prefrontal or higher psychic zone, a midfrontal or intermediate psychical motor zone, a region of representation of skilled movements of speech, of writing and of the lower extremity, and probably of the head and eyes, and a fundamental motor region. When the symptoms are psychical, therefore, it will be necessary only to expose the prefrontal area, although because of the tendency of prefrontal tumors to spread backward it is advisable to have the flap large enough to expose at least a portion of the midfrontal region. The opening of the prefrontal region would have the following boundaries (see Fig. 11, A and B): Its anterior boundary should run about parallel and a little below the frontal eminence, its superior boundary one-half inch below and parallel with median line; its posterior boundary is parallel with the central or Rolandic fissure, beginning above at a point four inches behind the upper extremity of the anterior boundary, and the base on a level with the Sylvian fissure. This opening would, measuring four inches in width and about three and one-half inches in length, expose the first, second and third frontal convolutions (see Fig. 11, A and B).

Mrs. S., aged forty eight years, referred to me by Dr. Charles K. Mills, November 9, 1903, presented symptoms of a prefrontal lesion. In this case there were no localizing phenomena other than those of a psychical nature. Patient's



A



B

FIG. 12. A.—Midfrontal opening extending below Sylvian fissure and not including first frontal convolution.

FIG. 12. B.—Area exposed by midfrontal opening, including (II) middle frontal convolution, (III) inferior frontal convolution, and (XIX) Broca's convolution.

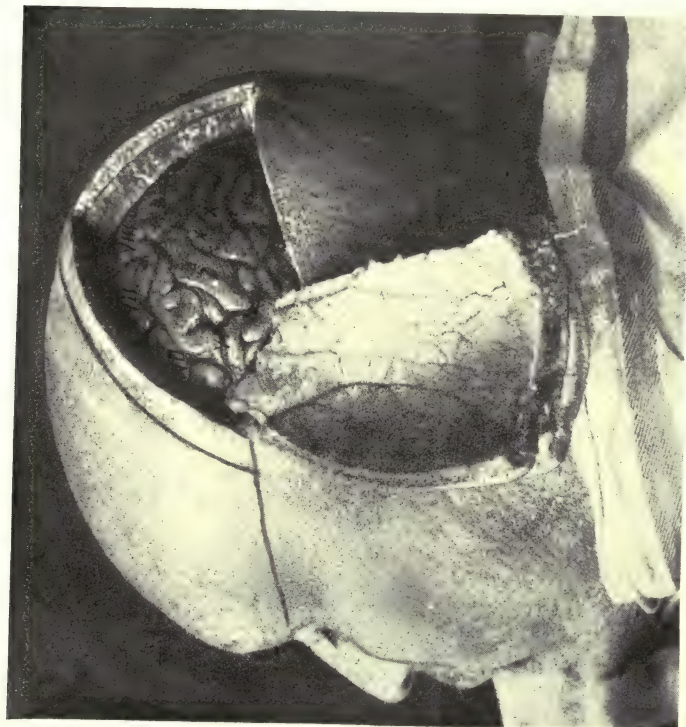mental condition was rather dull and apathetic. She was very slow in answering and easily confused. Her memory was evidently impaired. In addition to these phenomena, the patient had the usual symptoms of brain tumor, headache, optic neuritis and vomiting. Under ether anæsthesia an incision was made corresponding to the one which we have described as suitable for this region, exposing the three frontal convolutions. The region was explored with absolutely negative results. The patient died ten days after the operation, and an autopsy revealed a tumor in the cerebellar pontile angle and a very marked internal hydrocephalus. The latter condition was responsible no doubt for the disturbance of function in the frontal lobes and naturally led to an error in diagnosis.

2. MIDFRONTAL REGION. The opening in a case of tumor in which at least the initial effects point to the growth being situated in the third or second frontal convolution, no matter what may be the other symptoms, should be so placed that the third frontal convolution will be found in about the middle or just below the middle of the opening. This flap (see Fig. 12, A and B) differs from that for prefrontal tumors in that the superior margin is about an inch or inch and a half from the median line and the base or inferior margin is below the line of the Sylvian fissure, over the anterior limits of the temporal lobe. The anterior and posterior margins differ in no respects from those in the flap for the prefrontal region except in so far that they terminate an inch or an inch and a half from the median line and may each be made a little more posteriorly to the prefrontal opening. In addition to the agraphia and aphasia there were in the following cases symptoms pointing to invasion of a portion of the motor cortex. In this case it was necessary to modify the shape of the regular midfrontal flap so that it exposed a portion of the motor zone as well.

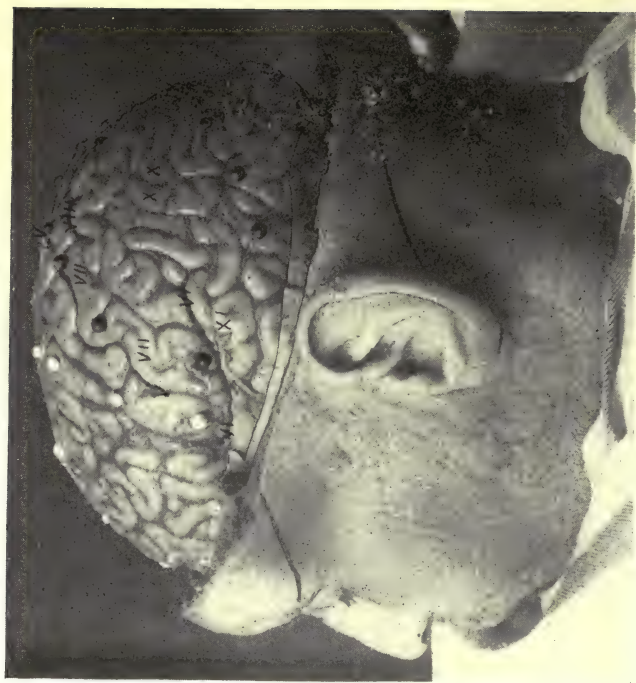
J. S., aged twenty-eight years, was admitted to the University Hospital, May 20, 1904. He was sent to the hospital by

Dr. J. W. McConnell, with the following history: Four years ago he had his first convulsion; a year later a second; six months later a third. From that time on the convulsions appeared with increasing frequency, but with less severity. At first they were associated with loss of consciousness, but more recently consciousness has been preserved. Dr. McConnell described the attacks which he saw as follows: There was fixity of gaze, blubbering movements of the lips, increased secretion of saliva, twitching of corner of the mouth and twisting of head to the right, with clonic spasm of the entire right side of the face. There was no loss of consciousness. When told to, the patient moved his hands during the spasm. The right pupil was dilated during the attack, the eyes were in the median line and the spasm involved the orbicularis palpebrarum. After the attack his speech was very much impaired, in fact for a few moments he was unable to speak at all. When speech returned it was as that of an intoxicated person. There was evidence of involvement of the right facial nerve. It was further noted that though the patient was an educated man, his writing was absolutely unintelligible. He neither could spell the words nor make the characters. A craniotomy was performed, and a tumor occupying portions of the superior and middle frontal convolutions, possibly the upper extremity of the third frontal convolution, was exposed. The tumor was removed and upon examination proved to be a sarcoma. The patient made an excellent operative recovery, and has up to the present writing remained free from recurrence.

3. PARIETAL OPENING. The loss or impairment of stereognostic conception and impairment of muscular and cutaneous sensibility suggest a lesion of the parietal lobe. When there are no other localizing symptoms the opening in the skull should be so made as to expose the region between the motor area and the occipital lobe, the anterior margin running parallel with and just posterior to the Rolandic fissure, the posterior margin beginning at the parieto-occipital

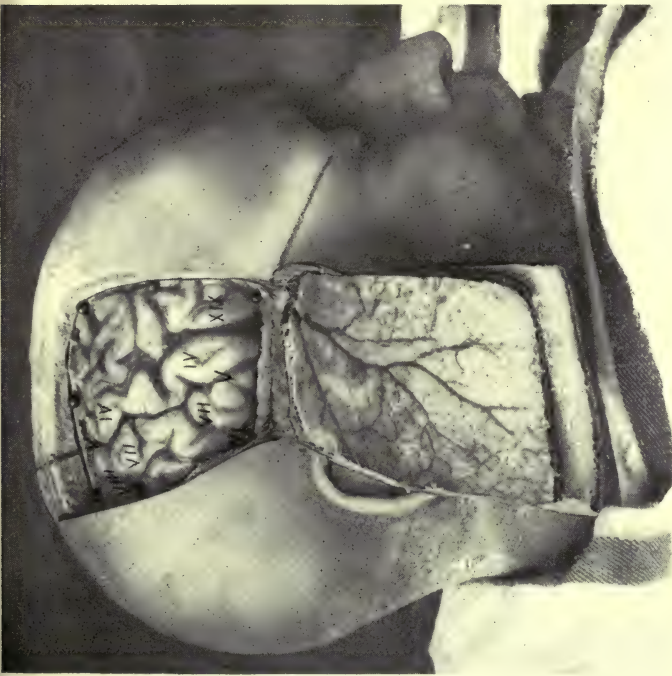


A

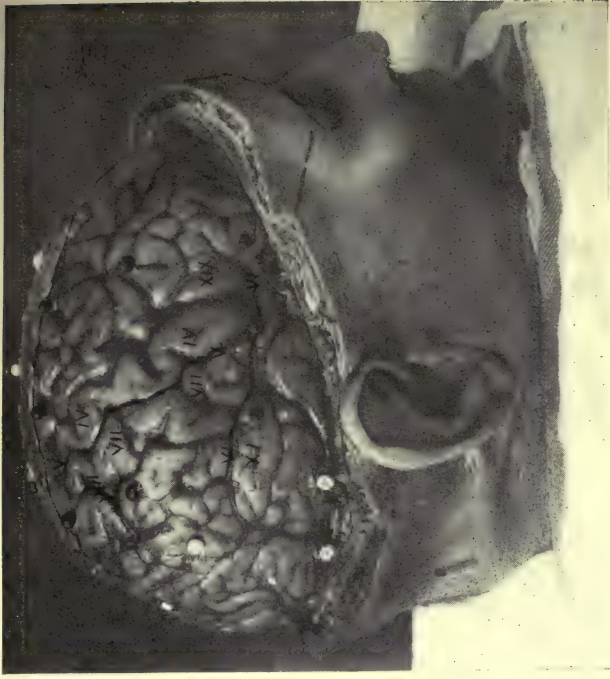


B

FIG. 13, A.—Parietal opening showing relation to Rolandic and Sylvian fissures. Note in Fig. 13 B (IX) how accurately this fissure was localized by craniometric method.  
 FIG. 13, B.—Area exposed in parietal opening, as indicated by black pins, including (VII) postcentral convolution, (VIII) intraparietal fissure, (XX) angular gyrus. Compare Fig. 13 A and note how accurately the Rolandic fissure V and the parieto-occipital fissure IX had been localized.



A



B

FIG. 14. A.—Standard motor opening, showing accuracy with which flap had been marked out with relation to V or Rolandic fissure.

FIG. 14. B.—Area exposed in motor opening, as indicated by *black* pins, includes (IV) precentral convolution, (V) Rolandic fissure, (VII) postcentral convolution, and (XIX) Broca's convolution. Note how accurately the base of the flap corresponds with VI, the Sylvian fissure. Both the Rolandic and Sylvian correspond exactly with the lines which were marked upon the scalp before the flap was reflected.

fissure and extending downward along a line nearly parallel with the anterior margin (see Fig. 13, A and B). I have never been called upon to operate for the removal of a tumor confined to the parietal lobe, but the following case—a gunshot wound—will serve as an example of an instance in which it was necessary to make a parietal opening:

The patient, C. J., aged fourteen years, sustained an injury from the discharge of a revolver; the bullet entered the left temple and passed upward and backward, lodging, as it was supposed from a skiagraphic study and from the symptoms, in the right parietal lobe. There was very evident impairment of stereognostic conception in the left hand. In addition to this significant symptom there had been some convulsions involving the entire right side of the face and the right upper and lower limb. The convulsions ceased, however, and there remained paralysis of both the upper and lower limb. Sensation for touch and pain in the lower limb was normal, but, as stated above, stereognostic conception was impaired in the left hand. The motor symptoms were attributed to the injury which the motor tracts had sustained as the bullet passed through to the parietal lobe. Furthermore, a very accurate calculation, based upon the skiagraphic study, localized the bullet in the parietal lobe about an inch from the cortex. After carefully considering the symptoms and the skiagraphic evidence the parietal lobe was exposed and an attempt made to find the bullet with an exploratory needle. In this, however, we were not successful and inasmuch as the bullet was believed to be at least an inch from the surface, it did not seem justifiable to continue the search by making an exploratory incision. When the patient was discharged from the hospital the strength of the upper extremity was almost entirely restored, but there remained some weakness in the peroneal and tibial group of muscles in the lower extremity.

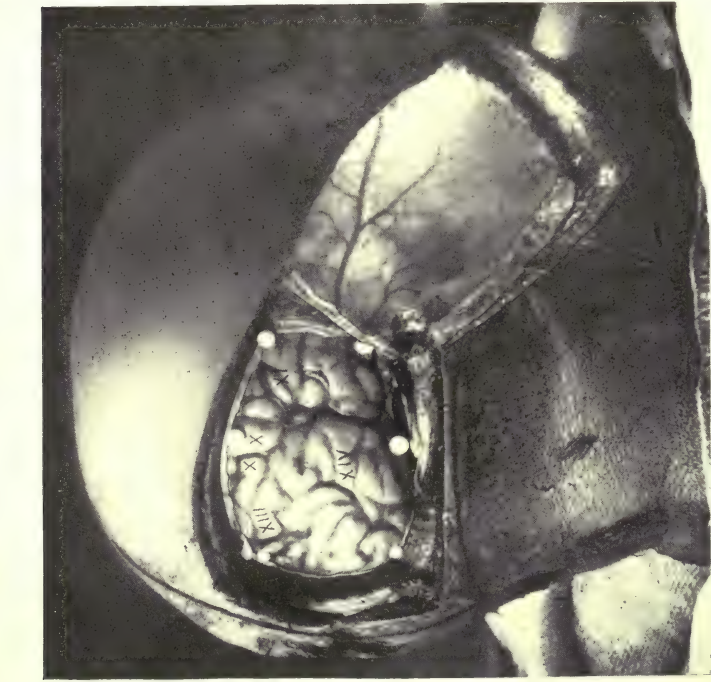
In every instance, providing the lesion is of recent formation or is of small dimension, the localizing symptoms will point to functional disturbances in but one physiological area. In



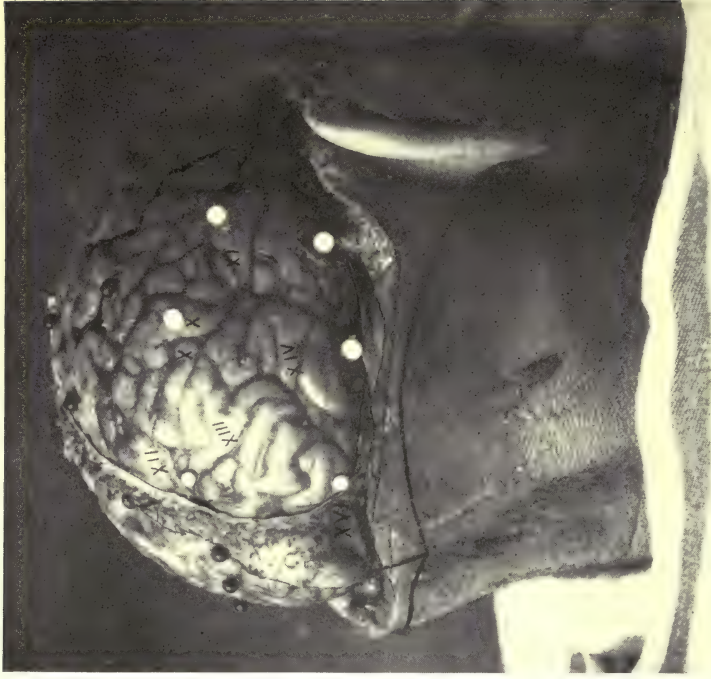
cases of long duration the lesion may grow beyond the limits of one physiological area and involve that adjacent to it. Thus, for example, a tumor may begin in the parietal lobe and extend to the occipital or motor region. Such was the history of the following case:

M. McJ., aged thirty-nine years, under the care of Dr. William G. Spiller, was admitted to the University Hospital October 11, 1904. There were no abnormal ocular phenomena. The cranial nerves were not affected. Tactile sensation was normal on both sides of the face. The grasp of the left hand was feeble, and there was slight diminution of sensation for both touch and pain in entire left upper limb. Stereognostic perception in the left hand was entirely lost. The patient complained of persistent and severe headache and had occasional convulsions, which began in the abdominal muscles and involved the left side of the face, and left upper and lower limbs. Under such circumstances it was necessary, of course, to reflect a flap which would include both the motor and parietal regions. The posterior margin of such a flap should correspond to an extension of the line of the parieto-occipital fissure, but the anterior margin need not be made quite so far in advance of the Rolandic fissure as would be necessary when the tumor was believed to have originated and to have remained localized in the motor area. Under such circumstances the anterior margin of the flap is usually made two to two and a half inches in front of the Rolandic fissure. An opening of this description was made in the case just alluded to and a large infiltrating gumma found and removed. The operation was unattended with any difficulties and the convalescence was uncomplicated.

**MOTOR OPENING.** In a paper recently published ("The Motor Area of the Cerebrum, its Position and Subdivisions, with Some Discussion of the Surgery of this Area," by Charles K. Mills, M.D., and Charles H. Frazier, M.D., UNIVERSITY OF PENNSYLVANIA MEDICAL BULLETIN, vol. xviii.) conjointly with Dr. Mills, I wrote somewhat at length upon the



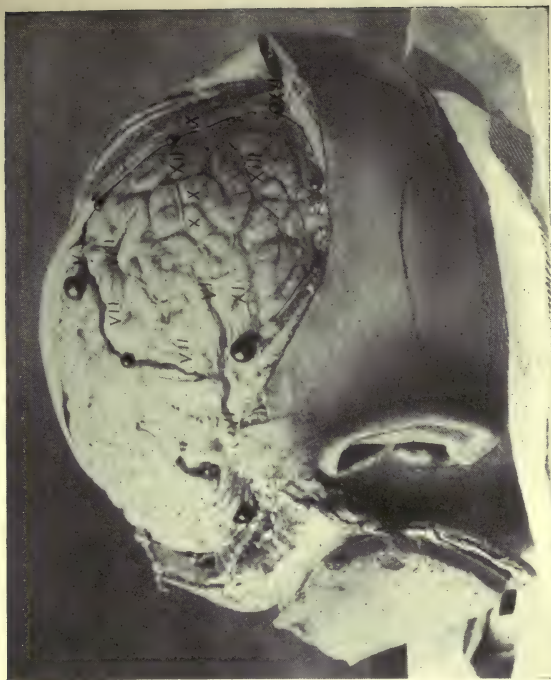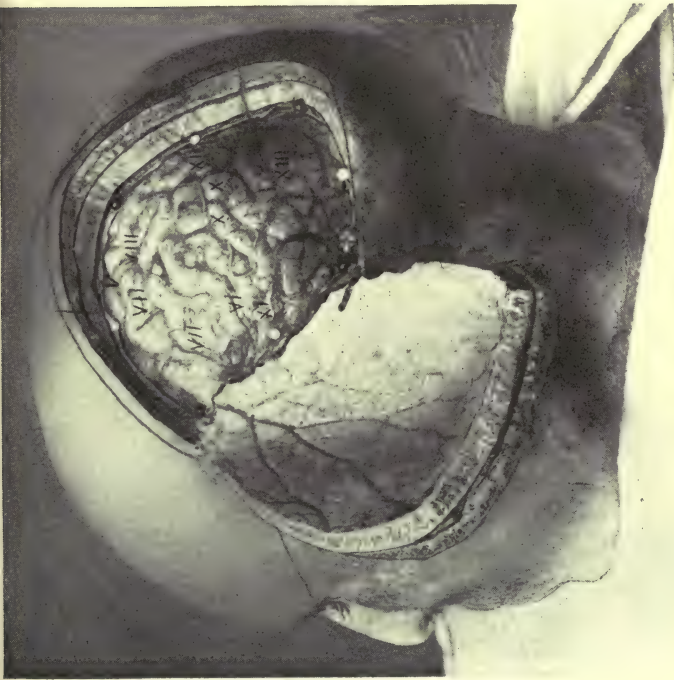
A



B

FIG. 15, A.—Occipital opening.

FIG. 15, B.—Area exposed in occipital opening as indicated by *white* pins, includes (XII) superior occipital, (XIII) midoccipital, and (XIV) inferior occipital convolutions, also a portion of (XI) first temporal convolution. This opening is not intended to include (XX) the angular gyrus, and the illustration shows it just on the outskirts.



A

B

FIG. 16, A.—Parieto-occipital opening.  
 FIG. 16, B.—Area exposed in parieto-occipital opening: V, Sylvian fissure; VII, precentral convolution; VIII, intraparietal fissure; IX, parieto-occipital fissure; XII, superior occipital convolution; XIII, midoccipital convolution; XX, Broca's convolution. The anterior margin of the flap, which was mapped out upon the scalp so as to run parallel with and just behind the Rolandic fissure, proved to be almost on a line with the fissure. Likewise the position of the parieto-occipital proved to have been very accurately localized before the flap was reflected.

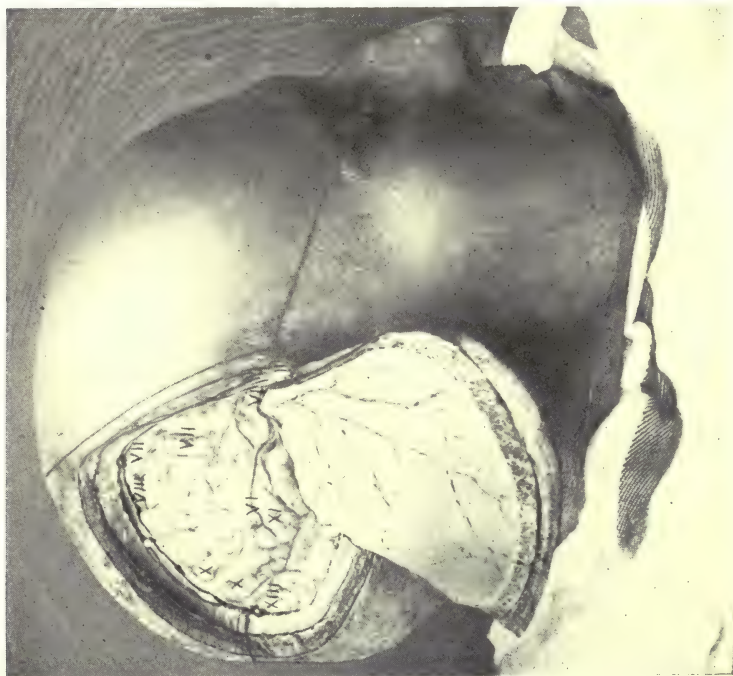
position of the motor area and upon the shape of the motor flap. For the exposure of this area we had adopted a standard motor opening in connection with some observations which were being made upon the position of the motor cortex with relation to the central fissure. The results of our observations upon the human subject, taken in connection with the experiments of Grunbaum and Sherrington upon the anthropoids, led us to believe that the motor zone in man at least is entirely or almost entirely in front of the fissure of Rolando. For this reason the motor flap is so mapped out that at least two-thirds or three-fourths of the opening lie in front and not more than one-third or one-fourth posterior to the Rolandic fissure. The lines corresponding to the central and Sylvian fissures are marked upon the scalp; the posterior margin of the opening runs parallel with and about three-quarters of an inch behind the central fissure; the superior margin should not extend nearer than one-half an inch to the median line and the base of the flap crosses the Sylvian fissure (see Fig. 14, A and B). A forward central extension of the opening should be outlined on the scalp to cover what is believed to be the most anterior portion of the area for the eyes and head. If the flap measures three and a half to four inches in width it will be wide enough to expose this area. It may be necessary in some cases to rongeur away the bone at the upper margin of the opening if the lesion is found to be near the longitudinal fissure. I have been called upon to expose the motor area more frequently than other areas, and have found the opening which we had adopted most satisfactory.

G. K., aged fifty-two years, was admitted to the University Hospital under the care of Dr. William G. Spiller, May 1, 1903. The significant features of the history were as follows: Headache of several years' duration, becoming more and more constant and more and more severe; weakness in the right upper extremity; convulsions involving the right side of the face and right arm, and motor aphasia. Dr. de Schweinitz

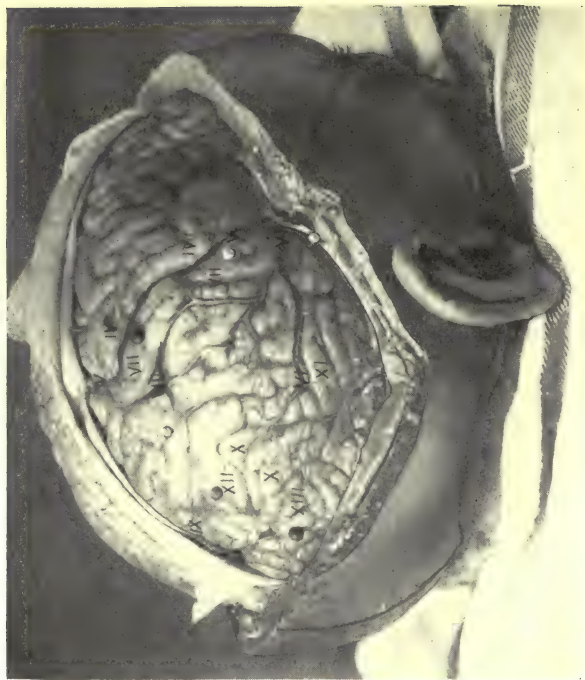reported that this was only a suggestion of a choked disk. Upon reflection of a motor flap an area was exposed to view which was evidently pathological and proved to be a tumor. The tumor was situated near the anterior margin of the opening, so that if the latter had been a little smaller the tumor would not have been exposed. The patient's condition at this time was entirely satisfactory, so that there was no necessity for postponing the removal of the tumor until a subsequent time. The extirpation of the growth was proceeded with and attended with no technical difficulties. The patient recovered from the immediate effects of the operation; on the fifth day it was observed that his aphasia was very much better, both as to the size of his vocabulary and as to the rapidity with which he could give expression to his thoughts. The headache of which he had complained so bitterly was almost entirely relieved. Subsequently the tumor, which was found to be a sarcoma, recurred, and the patient eventually died.

**THE OCCIPITAL OPENING.** This opening is used in cases in which the predominant symptom is hemianopsia. To expose the occipital lobe the flap should extend posteriorly to the line of the lateral sinus, anteriorly to the parieto-occipital fissure and above to within half an inch of the median line (see Fig. 15, A and B). The parieto-occipital fissure is situated approximately one-quarter of an inch posterior to a point midway between the inion and the line of the Rolandic fissure. The reflection of this osteoplastic flap is attended with some risk because of the proximity of the posterior and superior boundaries to the transverse and longitudinal sinuses respectively. It is most important that the entire occipital lobe should be exposed, and yet one must be exceedingly careful in reflecting the dural flap not to injure either of these large sinuses. The following is a case in which the operation for the exposure of the occipital lobe was performed:

The patient, M. B., aged seventeen years, was transferred to me from the service of Dr. Mills, October 9, 1904, with



A



B

FIG. 17, A.—Parietotemporal opening.

FIG. 17, B.—Area exposed in parietotemporal opening, including the temporal as well as the parietal convolutions.

the history of having been struck on the back of the head nine months before. He was not unconscious at the time he fell. About an hour later he became dazed, walking around aimlessly, and remaining in this state for about half an hour. On January 28, 1904, he was seized with shortness of breath, succeeded by tingling in the ears, and fell to the ground. It was said that during the convulsion his eyes were turned from side to side and that the whole body, with the exception of the hands and wrists, fell into a state of spasm lasting from five to seven minutes, with frothing from the mouth. Since that time he has had five attacks of this character, the latter one having been preceded by violent occipital headache and vomiting. He has marked optic neuritis, complains of intense headache and occasionally vomits. There is no hemiasynergia of either side. The patellar reflexes are normal. Hearing is not markedly affected. There is no paralysis of either facial nerve. Sensations for pain and touch are undisturbed. The movements of the extraocular muscles are normal, but there is nystagmus in looking either to the right or left. Stereognostic perception is normal in both hands. There is no disturbance of the reflexes and no muscular atrophy in any extremity. Inasmuch as the symptoms pointed entirely to the occipital lobe, a craniotomy was performed in this region. It was noted, upon reflection of the flap, that there was but slight pulsation and great tension, and when the dural flap was turned back the brain at once bulged through the opening. There was no evidence of a neoplasm on the cortex. The brain had protruded so through the opening that it was necessary in order to cover the defect to use a flap from the pericranium and also to remove the bone from the osteoplastic flap. The patient enjoyed considerable relief in so far as the headache, vomiting and dimness of vision were concerned, but the hernia which developed after the operation continued to increase in size and the optic neuritis recurred. He was re-admitted to the hospital December 21, 1904. The original flap was reflected, an exploratory canula

introduced and a large cyst discovered, extending to within one-half inch of the brain cortex. Upon evacuation of the cyst the brain collapsed and the dural and musculocutaneous flaps were replaced without any difficulty. With the exception of this disturbance of vision, which was not entirely relieved by the second operation, the patient's health is excellent.

In February, 1906, a letter was received, stating that he had had no "bad spells." The hernia which had developed at the site of the operation has not increased in size for the past year, but has remained about stationary.

There are certain cases in which, in addition to hemianopsia, there are symptoms suggesting some lesion in the neighborhood of the visuoauditory centres. Under such circumstances the anterior margin of the flap should be three-quarters to one inch in front of the line of the parieto-occipital fissure, the posterior and superior margins corresponding to those used for the simple occipital opening.

In other cases there may be symptoms pointing to a lesion not only in the parietal region but also in the region of the visuoauditory centres. In the one case we are called upon to make an occipitoparietal opening or an occipital opening extending about an inch in front of the parieto-occipital fissure; in the other, a parieto-occipital opening (see Fig. 16, A and B) that is a parietal opening extending three-quarters to one inch behind the occipitoparietal fissure. Some cases may point to a lesion of the angular gyrus alone, and under these circumstances the line of the occipitoparietal fissure should correspond with the middle of the flap.

Finally, there may be instances in which the symptoms refer to a lesion not only in the parietal but in the temporal region, in which case the flap must be so placed that its base is sufficiently below the line of the Sylvian fissure to expose the temporal convolutions. (See Fig. 17, A and B.)



## CEREBRAL DECOMPRESSION.

PALLIATIVE OPERATIONS IN THE TREATMENT OF TUMORS  
OF THE BRAIN, BASED ON THE OBSERVATION OF  
FOURTEEN CASES.<sup>1</sup>

BY WILLIAM G. SPILLER, M.D.,  
*Professor of Neuropathology and Associate Professor of  
Neurology in the University of Pennsylvania,*

AND

CHARLES H. FRAZIER, M.D.,  
*Professor of Clinical Surgery in the University of  
Pennsylvania.*

From the Department of Surgery and the Department of Neurology,  
and the Laboratory of Neuropathology in the University  
of Pennsylvania.

---

### REMARKS BY DR. SPILLER.

PALLIATIVE operations in cases of brain tumor are not new, and the temporary benefits to be derived in this way have been fully recognized by many physicians during many years. It has seemed time well spent to examine some of the reports of cases treated by trephining, or other method of opening the skull, for the relief of pressure when a tumor could not be localized, or if localized could not be removed. Unquestionably many cases have been omitted, and yet I have collected sufficient to demonstrate that palliative treatment has an important place in cerebral surgery.

---

<sup>1</sup> Read in the Section on Nervous and Mental Diseases of the American Medical Association, at the Fifty-seventh Annual Session, June, 1906, and published simultaneously in the Journal of the Association.

## REVIEW OF LITERATURE.

Annandale<sup>1</sup> said, in 1894, that more than twenty years previously he had opened the skull of a patient whose symptoms were those of general brain pressure and, although no special condition was found, temporary relief was marked. Another case of this kind, he says, was operated on by Sir Joseph Lister in the same wards with success. In 1889, Annandale removed a piece of bone from the skull because of intense headache, following an injury of the head years previously. No abnormal condition was found, although the dura was incised. The patient made an excellent recovery and was perfectly cured. Annandale remarked that when no localized symptoms of brain tumor exist an exploratory operation may be performed, and experience has shown that in some of these cases the operation has been useful in taking off general pressure and in a few instances has even been followed by shrinking or degeneration of the growth. Again, a growth may give rise to effusion of fluid or to hemorrhage, and the symptoms caused by these conditions may be at least temporarily removed by the operation.

Sahli,<sup>2</sup> in 1891, spoke of improvement from palliative operations. The tumor in one case was supposed to be in the cerebellum. Vision improved and headache disappeared after a palliative operation. The patient (a boy) died some months later and no necropsy was obtained. Sahli thinks that two trephining remote from each other give more relief of pressure than one. Sometimes Nature performs a palliative operation, what he calls *Selbsttrepanation*. In consequence of the pressure the skull becomes thin at the region of the Pacchionian bodies and openings may

<sup>1</sup> Edin. Med. Jour., January to June, 1894, p. 898.

<sup>2</sup> Volkmann's "Sammlung klin. Vorträge, Innere Medicin," Nos. 1 to 29, 1890-1894, p. 300.

occur, and in one case he saw the brain protruding through several such openings.

The palliative operation, he thinks, is not ideal, is not without danger, and improvement is only temporary. In one case of prolapse of the brain he observed unconsciousness immediately followed by death. Acute prolapse of the brain may impair the function of the rest of the brain. He recommends small trephinations in preference to large.

In 1891, White<sup>1</sup> described a number of cases of epilepsy in which improvement followed operation, although nothing abnormal was found.

In 1893, Horsley<sup>2</sup> said that the removal of excitatory symptoms by opening the skull is a marked phenomenon, convulsions ceasing. In one of his cases in which the diagnosis of tumor of the middle cerebellar peduncle was made the skull was opened only to relieve the pressure, and the cerebellum protruded almost an inch through the trephine hole. The symptoms of tumor soon disappeared, and six months later the man felt perfectly well. He survived eighteen months, and during this time had few attacks. Instead of a tumor only a small cavity was found.

Horsley thinks that some tumors are so interfered with in their nutrition by opening the skull and suddenly altering the pressure therein that they forthwith degenerate. In another of his cases the tumor was too large for removal, but the patient survived for over two years, with disappearance of the attacks and improvement of the hemiplegia. The tumor at the time of the operation was obviously malignant and rapidly growing, but had later undergone complete destruction by the mere exposure at the time of operation. Such a result, he says, cannot be anticipated or expected as likely to follow, but it is an argument in favor of opening the skull for the purpose of palliating a condition which cannot be cured.

---

<sup>1</sup> *Annals of Surgery*, August and September, 1891.

<sup>2</sup> *Brit. Med. Jour.*, 1893, No. 2, p. 1365.

Horsley says, also, that he has found in every case the effect of opening the skull has been to remove the headache, and, further, that in cases where it was known before operation that the tumor could not be removed, relief from severe pain afforded by opening the skull persisted until the patient died. The simple and safe procedure of opening the skull should be undertaken when drugs fail. At the Berlin Congress Horsley pointed out that opening the skull caused the swelling of the optic disks to subside, and that the subsidence may proceed steadily to complete recovery, provided atrophy has not previously begun. If atrophy has commenced the condition is hopeless. Vomiting is dependent on the degree to which intracranial tension is raised, and, as a rule, this symptom disappears when the skull is opened.

Jaboulay,<sup>1</sup> in 1893, obtained good results by trephining in a case of tubercle of the brain without opening the dura. The prognosis from trephining, he thinks, is better the more superficial and circumscribed the lesion is.

Caton and Paul<sup>2</sup> trephined the skull in a case of acromegaly in 1893. The dura bulged in the opening. The operation relieved the headache, and the remaining three months of the patient's life were comparatively comfortable.

Macewen<sup>3</sup> did a palliative operation in 1889 in a case with symptoms of cerebellar tumor. The patient experienced great relief. After a week tuberculous tumors were removed from the cerebellum.

Taylor<sup>4</sup> reported a series of cases of brain tumor to show that there is almost invariably a subsidence of optic neuritis after operation whether the tumor is removed or not. This fact, he says, was known to Horsley so long ago as 1888. In discussing Taylor's paper Horsley said that if

---

<sup>1</sup> Arch. provinc. de Chir., 1893, vol. ii.

<sup>2</sup> Brit. Med. Jour., Dec. 30, 1893, p. 1421.

<sup>3</sup> Ibid., Dec. 23, 1893, p. 1367.

<sup>4</sup> Transactions of the Ophthalmological Society of the United Kingdom, 1893-1894, vol. xiv, p. 105.

there is any atrophy present no amount of reduction of pressure within the skull will produce the slightest change or afford the slightest relief in respect of the loss of vision. If there be commencing atrophy after operation the neuritis that may be present will disappear, but the atrophy is permanent; opening the skull, therefore, is not justifiable if the atrophy is well marked. Horsley was probably referring to the operation only in so far as vision is concerned, as the operation may relieve some of the other symptoms, even though it may be too late to restore vision. The optic neuritis may disappear, Horsley says, even though the dura is not opened.

In a case reported by Keen,<sup>1</sup> in 1894, the diagnosis of intracranial tumor was made, but the growth could not be located. Trephining was recommended with a view of relieving intense headache. The tumor could not be found.

The bone was not replaced, and, although the brain bulged greatly, head'ache and hallucinations entirely disappeared, and the man became a quiet and tractable patient. He died four and a half months after the operation, having been much relieved during this time. The operation was performed in 1892. In another case, also, much benefit was obtained by a palliative operation.

Bruns,<sup>2</sup> in a case of brain tumor in which the tumor could not be found at operation, improved the patient's condition by opening the skull. By the end of the third week very little choked disk remained, attacks of blindness no longer occurred, headache was much less severe and vomiting ceased. Similar improvement he had noticed in two other cases of brain tumor after trephining.

Byrom Bramwell,<sup>3</sup> in 1894, said that he had advocated trephining for the relief of symptoms in his book, *Tumors of the Brain*, published eight years previously, but that he

<sup>1</sup> Amer. Jour. of the Med. Sciences, January and February, 1894.

<sup>2</sup> Neurolog. Centbl., 1894, p. 20; also 1893, p. 389.

<sup>3</sup> Edin. Med. Jour., January to June, 1894, p. 1067

would advocate the operation still more strongly in 1894 in cases in which there is a great increase of intracranial pressure and drugs have failed. When he published his book he had not been aware that Grainger Stewart or anyone else had recommended the operation. In many cases the headache is intense, and it has been shown that in some of these cases sudden death occurred, apparently as a result of the mere severity of the pain and sudden inhibition of the action of the heart. In other cases in which the intracranial pressure is greatly increased, the patient dies suddenly in an epileptic fit or as the result of failure of respiration. Opening the dura reduces intracranial pressure and relieves headache and other symptoms, among them optic neuritis.

In 1894, Kammerer<sup>1</sup> reported a case of supposed tumor of the brain in which double trephining was done for the relief of pressure. The headache disappeared, vomiting ceased for several weeks and then occurred occasionally. The motive power of the right side (previously this side was paretic) improved and some sensation returned. The dura was not incised.

Wyeth remarked that he had trephined in two cases with symptoms of brain tumor, and, finding no tumor, had sewed up the dura, but had not replaced the bone; improvement had followed the relief of pressure.

Sänger,<sup>2</sup> in 1894, reported a case of brain tumor in which after opening the skull and dura prolapse of the brain with improvement in the symptoms occurred.

In one of the cases of tumor reported by E. Albert,<sup>3</sup> in 1895, in which palliative trephining was done, headache disappeared, but vomiting persisted. The dura probably was not opened. Later trephining was done on the other side of the head, but vomiting persisted. The relief afforded

---

<sup>1</sup> *Annals of Surgery*, January to June, 1894, vol. xix, p. 685.

<sup>2</sup> *Neurolog. Centbl.*, 1895, p. 472.

<sup>3</sup> *Wien. med. Woch.*, 1895.

in this case was in regard to headache and might have been greater if the dura had been opened.

In another case in which trephining was done for brain tumor the dura was punctured. Headache became at once less severe, but the improvement was only temporary. In another case after trephining apparently without opening the dura, vision improved and headache and vertigo disappeared. The symptoms returned and the dura was opened. The operation was not very successful as a palliative means.

Schlesinger,<sup>1</sup> in a case of brain tumor, had a large protrusion of the brain as a result of the operation. The protruded portion could not be replaced, nor was it excised, and when the patient was presented he had a subcutaneous tumor on his head as large as a fist. The general condition improved as a result of the operation, the palsy diminished, the Jacksonian convulsions ceased on the third day after the operation, and the choked disks and headache disappeared. Seven weeks had elapsed since the operation at the time of presentation. A later report of this case states that the improvement lasted several months and then the symptoms returned rapidly and death soon resulted. The entire right cerebral hemisphere was replaced by a gliosarcoma.

Decompressive trephining, a term employed by Jaboulay,<sup>2</sup> performed for brain tumor, according to this author, has proven to be of some benefit, more often not. When done for the relief of inoperable tumors the results are not always brilliant. He speaks of astonishing results produced by trephining in the cerebellar fossa in a case of basal tumor; the pain ceased and the vision improved. The patient lived four and a half months after the operation. Jaboulay seems to believe that the relief in palliative operations is greater for tumors of the cerebellum and adjoining parts than for tumors of the cerebrum.

<sup>1</sup> Neurolog. Centbl., 1895, p. 702, and 1898, p. 974

<sup>2</sup> Lyon Médical, 1896, p. 73.

Broca and Maubrac<sup>1</sup> ascribe to Horsley the honor of being the first to describe carefully trephining as a palliative operation in brain tumor, although scattered references to the subject are found in the literature, and they refer to Annandale and Lister. Horsley recommended making a large opening in the skull without opening the dura. Sahli, they say, recommended excision of the hernia that is produced by opening the dura, especially as the portion of the brain involved in the hernia is impaired in its function. They say that Kocher did operate in this way on a child in the service of Sahli for a tumor not localized, but probably in the cerebellum. A hernia of the cerebellum was excised and benefit resulted. Broca and Maubrac employ the term "cerebral decompression." The palliative operation, they think, exposes the patient to the danger of shock, and when the operation is performed at an advanced period of the disease death is not exceptional. When the patient survives the most distressing symptoms are lessened or disappear entirely, and, therefore, the palliative operation should be employed. It does not cause more rapid growth of the tumor. Exploratory trephining, when the diagnosis of location has been incorrect, has taught us that cerebral decompression may give important results. These authors express themselves in favor of partial removal of a tumor when the whole cannot be excised, but are undecided as regards Horsley's view that partial ablation may retard the growth of the remaining portion. They report two cases of tumor in which palliative operation was beneficial.

In 1895, J. J. Putnam<sup>2</sup> remarked that he knew of one patient who, in consequence of simple opening of the skull, had been free from pain for many years, though blind. He said he had seen relief from pain by large openings in the bone in several cases. He was speaking of brain tumors.

<sup>1</sup> Arch. Gén. de Médecine, February, 1896, p. 129.

<sup>2</sup> Boston Medical and Surgical Journal, January 16, 1896, p. 66.



Schultze's<sup>1</sup> results from palliative operation in brain tumor were disappointing as recorded in his paper published in 1896. He speaks of it as often dangerous, but at times beneficial.

Ludwig Bruns<sup>2</sup> thinks that when the tumor cannot be removed or only a small part of it is removable, trephining does not affect the focal symptoms, but causes the general symptoms quickly to disappear if the opening is large. Consciousness returns, headache, vomiting, and choked disks disappear. In two of his cases the patients, who had hovered between life and death, had been able to walk again after palliative operations. In one of his cases (glioma of the occipital lobe) improvement lasted several months; in a second case it lasted some weeks. As headache in many cases does not return at all the recurrence of symptoms is not so distressing and the patient passes into coma. The tumor, by growing through the opening, removes the pressure on the lymph tracts within the skull. Bruns says the opening in the skull must not be too small, and the dura also must be opened.

Clarke and Morton<sup>3</sup> report a case of tumor of the brain without localizing symptoms, in which a large area of the skull was removed for relief of intracranial pressure and the dura was not incised. Headache disappeared. They remarked that Beevor and Ballance thought that removal of bone alone without incision of the dura was not likely to relieve intracranial pressure, but they (Clarke and Morton) believe that the actual increase in the bulk of the cranial contents may not be considerable if the tumor is small, and the bulging of the dura mater even to a very limited extent may be sufficient to relieve the increase of the intracranial pressure caused thereby. Clinical evidence

<sup>1</sup> Deuts. Zeit. f. Nervenhlk., 1897, vol. ix, p. 217.

<sup>2</sup> "Die Geschwülste des Nervensystems," S. Karger, Berlin, 1897, p. 229.

<sup>3</sup> Brit. Med. Jour., 1896, p. 802.

in Caton and Paul's case, as in their own, showed distinctly that removal of an area of bone alone is sometimes sufficient. Except for the recurrence of fits five months after the operation, the trephining was of great benefit in Clarke and Morton's case. Optic neuritis subsided, leaving some consecutive atrophy, but the patient had good vision, was entirely free from headache and vomiting, except once during the last series of fits, had recovered his mental powers and had a comfortable existence.

Alfred Wiener<sup>1</sup> reports a case of irremovable tumor. After opening the skull, headache and convulsions disappeared for about two months, but the tumor grew through the opening of the skull, attained considerable size on the outside of the skull, and the symptoms returned. Wiener speaks in favor of trephining in cases of brain tumor, even when there is no other hope of success than the relief of the general symptoms.

Rohmer<sup>2</sup> has collected a large number of cases in which the palliative operation in tumor of the brain had a beneficial effect on vision.

von Bergmann<sup>3</sup> has called attention to the fact that in contrast to those cases in which improvement was pronounced after palliative operations for brain tumor others are recorded in which no benefit was obtained, and, indeed, the symptoms were made worse. The improvement is only temporary and in some cases has been of very short duration. The operation also is dangerous. Improvement has occurred after merely opening the skull or after opening the dura also; surgeons, therefore, he said, preferred to remove a large piece of bone and leave the dura intact, but as cerebrospinal fluid can escape only after the dura is opened, the incision of the dura is a necessary part of the palliative operation. There was a tendency, he said, to stop at a palliative opera-

---

<sup>1</sup> New York Med. Jour., Oct. 15, 1898, p. 541.

<sup>2</sup> Revue Méd. de l'Est., 1898, p. 525.

<sup>3</sup> "Die Chir. Behandlung von Hirnkrankheiten," Berlin, 1899.

tion, and this must be strongly combated. The future of the surgical treatment of brain tumors lies in the advancement of diagnosis, and in this way the almost thankless palliative operation may be changed to a radical cure. As the escape of cerebrospinal fluid is more important than the opening of the skull, v. Bergmann recommended lumbar puncture. Since v. Bergmann wrote his book experience has shown that lumbar puncture in cases of brain tumor may be dangerous. He has been pessimistic both as regards palliative and radical operations for brain tumor. He gives a long list of cases in which exploratory and palliative operations were done, but almost all of these were attempts at removal of a tumor. In his book (1899) occurs the expression, "decompressive trepanation." He refers to a case reported by Remsden in 1825, in which trephining was done for headache.

Sänger,<sup>1</sup> in 1894, reported two cases to show that under certain circumstances trephining is proper, even when a tumor cannot be removed. In 1899 he presented a case of brain tumor in which a palliative operation had been performed. Inunctions were at first effective, but later the symptoms became very severe. An opening was made over the cerebellum and the cerebellar lobe at once protruded; when the dura was incised much cerebrospinal fluid escaped into the bandages for more than three weeks. After the operation vomiting and headache ceased and full recovery seemed possible. Choked disk disappeared, and vision improved so much that the patient was again able to read. The gait also improved and ataxia became hardly noticeable. The operation was performed August 7, 1899, and the presentation of the patient was made November 14, 1899.

Babinski,<sup>2</sup> in 1901, reported a case in which a tumor could not be found after the cerebral dura was opened, although the symptoms had been so severe as to make an operation

<sup>1</sup> Neurolog. Centbl., Dec. 1, 1899, p. 1118.

<sup>2</sup> Revue Neurolog., 1901, p. 266.

desirable. The headache and vomiting ceased after the operation, which was performed January 14. The choked disks disappeared by January 30. The presentation of the case was made February 7, 1901. In another case Babinski observed signs of an intracranial disease. The patient had an intermittent discharge of cerebrospinal fluid by the nose. Headache was lessened by the escape of fluid and became more intense when the flow ceased. Nature in this way produced decompression he says. This case is not unlike some others reported in the literature in which Nature has effected a means of relief for intense intracranial pressure, and bears a resemblance to a case observed by me in consultation with Dr. Laplace and reported in this paper (Case 1).

A. Sanger<sup>1</sup> presented a case in which he had made the diagnosis of cerebellar tumor and an opening was made over the left cerebellar lobe. The improvement was marked, and Sanger believed that either the tumor had undergone a retrograde change or the condition was hydrocephalus. Of eleven cases in which a palliative operation was performed the symptoms were much lessened in ten. The time for operation that Sanger chooses is the beginning of impaired vision. When the opening is made over the cerebellum the dura must not be opened immediately.

In 30 cases of brain tumor studied by Leslie Paton<sup>2</sup> that were operated on, useful vision was saved in 22 and the vision was as good as before the operation in 18. It is impossible to draw conclusions regarding his cases in which a tumor was removed and those in which a palliative operation was performed. In the discussion following Paton's paper J. S. Risien Russell said he had no doubt that trephining was of great value in saving sight. He never hesitated to recommend the operation even in cases in which there was no chance of either localizing the tumor or removing it, for by

<sup>1</sup> Verhandl. d. Deuts. Gesell. f. Chir., 1902, p. 158.

<sup>2</sup> Transactions of the Ophthalmological Society of the United Kingdom, 1904-1905, vol. xxv, p. 129.

relieving the intracranial pressure alone sight could be saved. His experience had been that removal of bone alone was not sufficient; it was usually necessary to open the dura in order to obtain sufficient relief of pressure to bring about a subsidence of the optic neuritis. Paton also expressed himself in favor of opening the dura, as he did not believe merely opening the skull was of much benefit. In two cases only the cranial cavity was opened, and blindness developed in both.

Codman<sup>1</sup> says:

“In 28 of the 36 operations the attempt at a radical removal of the tumor was made, and in the eight worse cases only was it decided to do only a palliative operation. I think we may almost say it is certain that if in no case the attempt at radical removal had been made and, instead, a simple operation for the relief of pressure had been done through an intermuscular incision over a “silent” portion of the cortex, the mortality would have been greatly diminished and the percentage of improvement been made much greater. I do not mean to say by this that radical operation in the hands of a surgeon who has made a specialty of brain work is not justifiable, but that in the hands of most of us, a simple palliative operation will be far better in the long run.”

In my opinion, only one who has made a specialty of brain surgery should attempt the removal of a tumor of the brain.

J. J. Putnam<sup>2</sup> reports cases of palliative operation. In Case 2 marked relief from terrible headache and optic neuritis followed the making of a large trephine opening in the parietal region, and this, too, although the bone was replaced. This improvement was attributed to the escape of cerebrospinal fluid, which gushed in large quantities from the wound in the parietal dura. The tumor was a glioma of the lateral lobe of the cerebellum. In Case 3 a large tumor mass protruded through the trephine opening, pushing the skin before it. A measure of relief followed the operation.

<sup>1</sup> Boston Medical and Surgical Journal, July 20, 1905, p. 74.

<sup>2</sup> Boston Med. and Surg. Jour., July 20, 1905, p. 76; also Jour. of Nerv. and Ment. Dis., May, 1906

Recently, in association with Watermann, he has reported other cases. Lund<sup>1</sup> also has reported improvement from the palliative operation in cases of tumor of the brain.

Cushing<sup>2</sup> has reported recently cases in which the palliative operation has been of much benefit.

I add condensed notes of two unreported cases in which palliative operation was performed by Dr. W. W. Keen with improvement in each.

CASE 1.—Jan. 3, 1901, E. H. M., aged twenty-six years, complained of failing vision and had later several attacks of temporary blindness. Among the first symptoms were severe headache on the right side and vomiting, later the pain shifted to the left side. He was found to have extensive optic neuritis. He has a little vision now in the left eye but is blind in the right eye. He has sharp, boring pains which shoot from the upper occipital region to the back of the left ear. The patellar reflexes are exaggerated. Dr. de Schweinitz, Dec. 17, 1900, found optic neuritis passing into atrophy.

Dr. Keen, Jan. 30, 1901, made an osteoplastic flap over the left parieto-occipital region. The dura was very tense. Four small openings were made in the dura, but nothing abnormal was discovered. The brain was punctured in the attempt to reach the lateral ventricle, and the attempt probably was not successful. The piece of bone was removed entirely. The patient was discharged February 18, almost entirely relieved of his headache.

At Dr. Keen's suggestion, I made inquiries regarding the present condition of this man and received the following letter, dated April 20, 1906: "I am wonderfully improved and relieved as to pain, cannot see except to distinguish between night and day, have not been bedfast for a year or more, at intervals have severe pain, say every week or two, lasting from twelve to twenty-four hours, after which brain is very sore. Since last July have been having a discharge from the left nostril of a watery-like fluid, since then the pain has not been quite so severe."

CASE 2.—Feb. 5, 1903. E. B., aged thirty-seven years. During the summer of 1894 a small tumor developed in the scalp on the posterior portion of the right parietal bone, producing headache and a sensation of pressure. In the summer of 1895 this mass was removed. His physician stated that it was a fatty tumor. All the pain and pressure symptoms disappeared and he was perfectly well.

After several months the headache and pressure sensation gradually returned; simultaneously with the onset of the headache his eyesight

<sup>1</sup> Boston Med. and Surg. Jour., July 20, 1905, p. 81.

<sup>2</sup> Surgery, Gynecology and Obstetrics, 1905, vol. i, p. 297.

began to fail, and for the last two months he has been partly blind. He has had frequent vomiting, but he attributes this to the iodides. Ataxia was noticed in the finger-to-nose test. His gait is ataxic with a tendency to fall to the right. Lateral movements of the eyeballs are ataxic. Patellar reflexes are minus. Dr. Sweet found papillitis passing into optic atrophy in both eyes.

Feb. 11, 1903, Dr. Keen exposed the cerebellum over nearly one-half of the right half of the occipital bone. The dura was extremely tense on palpation. The patient was discharged ten days after the operation entirely relieved of his headache and with the wound healed.

Dr. John T. Howell wrote to me, April 23, 1906, that the patient died in a hospital in England, July, 1904, after an operation in February of the same year. The skull was opened above the ear and a large tumor was taken from the brain. After returning from the Jefferson Hospital, in 1903, the patient's improvement was of short duration.

#### WHEN PALLIATIVE OPERATIONS ARE ADVISABLE.

After a careful study of these cases and of the views of the different authors, it will be seen that the weight of opinion is decidedly in favor of palliative operations. The choked disk, headache, vertigo, nausea, vomiting, and, to some extent, the convulsions are all favorably influenced by this method of treatment. Relief from these distressing symptoms is by no means to be despised, even though the tumor is not removable. The relief from many of these symptoms is often permanent, *i. e.*, during the period the patient may continue to live, and, as the growth of the tumor is not hastened by the palliative operation and may be slow, we are thankful for a means of removing the distressing symptoms of intense intracranial pressure.

My first case of palliative operation was in 1898, and the operation was performed by Dr. John B. Roberts. The marked improvement that occurred in that case and persisted at least during several years and until the patient passed from our observation convinced me of the benefit to be derived from palliative operations (Case 2 of our series). She is still living and is in good health.

In one of our cases (Case 10) headache was so severe that

relief was demanded at once. Byrom Bramwell, as already mentioned, has attributed sudden death in some cases of brain tumor to the severity of the headache and sudden inhibition of the action of the heart. The patient to whom I refer suffered such intense pain that he could not be reasoned with and was not responsible for his acts. Occasionally, in his attacks of pain, he grabbed anyone who might come within his reach and once bit his mother through the arm. The relief afforded in this case by a palliative operation has been most striking. Indeed, his relief from the previously constant pain has been so great that, as he expresses it, he is "lonesome without his headache."

In another case (Case 11) headache has been the symptom that above all others demanded treatment and the pain in the head was associated with pain in the neck, shooting down into the upper limbs. The symptom-complex has been in large degree that of cerebellar tumor, but the pain shooting into the upper limbs has made me fear that the tumor was extending downward through the foramen magnum on the cord. Some years ago I had a case of this kind, and at the necropsy a flat tumor was found covering a part of the pons extending into the posterior part of the fourth ventricle and growing down on the cord for several inches. In that case the development of the symptoms in the upper and lower limbs was more rapid than in the present instance, and, therefore, I feel that the tumor in the latter case may be confined to the region of the cerebellum. If so, I have no explanation for the pain in the upper limbs. The decrease of this pain, together with the decrease of the headache after the dura was opened at the second operation, gives me reason to believe that probably this pain of the limbs was indirectly caused by the cerebellar tumor. Headache and pain in the upper limbs still occur occasionally, but the condition of the patient has been vastly improved by the removal of a piece of bone and by opening the dura over the cerebellum.



I am somewhat skeptical as regards disappearance of Jacksonian convulsions after merely opening the skull and dura if the convulsions are very frequent.

In one of my cases in which the brain was exposed by Dr. Edward Martin and which will be reported by Dr. Martin and myself later, the tumor could not be found at the time of operation. The man was having five or six Jacksonian convulsions within an hour, and relief of intracranial pressure did not in any way check them. He died from exhaustion following the numerous convulsive seizures on the second day after the operation. After death a minute tumor was found nearly in the centre of the area exposed, but a little subcortical.

In a still more recent case under my care, in which fracture of the skull and subdural hemorrhage had occurred, trephining probably prolonged life about twenty-four hours, but did not in any way check the Jacksonian convulsions which before the operation were as frequent as six or seven within an hour, and continued in weakened intensity but with equal frequency after the operation. Opening the skull does not seem to relieve acute irritation of the brain, but it is of benefit in chronic cases, as not rarely convulsions occurring infrequently have been rendered less severe by this procedure.

I have considered whether palliative operations can obscure focal symptoms. Bruns thinks they cannot, but the subject is one that has important bearings. It is probable that a small tumor will cause more local disturbance if the general intracranial pressure is increased, not only because the local disturbance is added to the general pressure, but also because any one part of the brain is more irritable when the disturbance of the brain is general. This, however, is not sufficiently important to prevent palliative operation, and I would advise that this should be done before the general symptoms become very intense, and especially before optic neuritis has developed so far that

blindness is likely to result. The apparent unanimity of opinion as regards the effect on choked disks of opening the skull makes the necessity of this operation at an early period very evident.

It is a mistake to regard palliative operations as a substitute for radical operations. The tumor should be removed whenever this is possible, and palliative measures are to be considered only when the tumor cannot be located, or is too large for removal, or possibly is a glioma. Palliative operations only relieve, except in extraordinary cases such as those reported by Horsley. Codman's views that palliative operations are preferable to radical operations I cannot share, and would add that the argument he offers is insufficient, viz., that the former are less dangerous in the hands of inexperienced surgeons. No surgeon who has had little experience in operating on the brain should attempt the removal of a brain tumor, and before advising the attempted removal of a brain tumor I always inquire who is to perform the operation.

The experience of Horsley as regards atrophy of tumors as a result of palliative operations seems to be unique; at least I have found no other similar cases, nor have I ever seen any such result in any of our cases. Broca and Maubrac doubted whether Horsley was correct in believing that partial ablation of a tumor may retard the growth of the rest, but Horsley has observed atrophy of a tumor following a simple opening of the skull and dura. This is a striking statement. I have never seen arrest in the growth of a tumor following the removal of a part, but several times I have seen increase of symptoms result, and I dread the partial removal of a growth, especially if it is a glioma. It has seemed to me that the congestion of the tumor and of the surrounding tissue and the greater space afforded for the growth of the tumor, after partial removal, favor the rapid growth of the remaining portion. I am almost convinced that it is better to leave a tumor untouched if only a part can be re-

moved, especially if the growth is a glioma. The attempt, I think, should never be made to remove a glioma, and yet there seems to be no way to determine before operation that the tumor is a glioma. A patient has been under our care with the diagnosis of brain tumor and was operated on several times by Dr. Frazier. Each time as much of the tumor as could be seen was removed, and yet a return of the symptoms occurred soon after each operation, and when a necropsy was obtained the tumor (a glioma) was found to extend from the upper to the lower surface of one cerebral hemisphere.

I doubt whether it can be held that a palliative operation, by which the tumor is not partially removed, by relieving pressure, favors the growth of an intracranial tumor. Unquestionably the brain has protruded through the opening as in the cases of Schlesinger, Frazier, and Cushing, but it seems a questionable proceeding to excise the protruding portion. The tumor has grown through the opening and on the outside of the skull (Jolly, Wiener, Putnam, and others). In Jolly's case it formed an extracranial mass nearly as large as the man's head. It seems unquestionable that life was prolonged in this case by the operation, although it is doubtful if life under such circumstances is worth having. In Jolly's<sup>1</sup> case the clinical signs extended over a period of thirteen years. In the case that Dr. Martin and I observed, to which reference has been made, the symptoms of brain tumor had existed for eight years.

We have had some extraordinary cases in which the symptoms of brain tumor disappeared entirely or almost entirely after an opening had been made in the skull and dura; such, for example, is the case observed by Dr. John B. Roberts and myself in 1898, and also Cases 4, 5, 6, 9, 10, of our series. It may be thought that the growth of the tumor is arrested by the operation; this is possible, but doubtful. Internal hydrocephalus (meningitis serosa) or

---

<sup>1</sup> Berl. klin. Wochft., July 17, 1899, p. 636.

some other lesion may give the symptoms of brain tumor, and relief of intracranial pressure may cause great modification or disappearance of the symptoms. In some cases in which relief has followed palliative operations probably an incorrect diagnosis has been made; in others, the relief of pressure has permitted the tumor to grow slowly without causing many symptoms. My views as a result of my experience and of a study of the literature are:

1. Palliative operations should be performed early in every case in which symptoms of brain tumor are pronounced and before optic neuritis has advanced far, especially when syphilis is improbable or antisiphilitic treatment has been employed.

2. Partial removal of a tumor, especially of a glioma, is a questionable procedure.

3. Palliative operation does not under ordinary circumstances cause atrophy of a brain tumor and probably does not arrest its growth; on the other hand, it probably does not hasten its growth.

4. Palliative operation is not to take the place of a radical operation when the latter can be performed without great risk to the patient.

5. In some cases the symptoms of brain tumor disappear almost entirely for a long time or permanently after a palliative operation. This result is obtained either by relief of intracranial pressure or by removal of some lesion (meningitis serosa, etc.) other than brain tumor, and yet causing the symptoms of tumor.

#### REMARKS BY DR. FRAZIER.

The question as to whether a palliative or radical operation is indicated may be determined by answering the questions to whether the tumor is operable or not. The operability of brain tumors has frequently been discussed and the facts and figures which have been presented to us have been based

almost exclusively on the autopsy records and not on the finding at the time the operation was performed. The autopsy records may help to determine the percentage of operable tumors in so far as it reveals the nature of the tumor and may be able to fix on its point of origin. The very vascular infiltrating sarcomata should be classed with the inoperable tumors, for I believe the expectation of life and the enjoyment of that much of life which remains to the patient would be greater in the majority of cases after a palliative operation. On the other hand, the fibroma, or the somewhat defined fibrosarcoma and the gumma of limited dimensions, should be classified as of the operable group. The size of the tumor as revealed at the autopsy has no practical bearing at all on the problem; the size of the tumor at the time the symptoms first made a diagnosis possible should only be considered. There are some tumors of such large proportion as to make any attempt at removal inadvisable, but, on the other hand, tumors of very small dimensions may lead to a fatal termination.

If it were possible to ascertain the point from which the tumor took its origin we should have some valuable statistics as to the operability of tumors. The further away the tumor is from the cortex or the nearer it is to the base of the brain the more it approaches the field of inoperable growth. If the statistics are to be of much value to the surgeon they should be based on the records which are made on the operating table or at the autopsy, if the patient dies as a result of operation, only in those cases in which the patient has been brought to the surgeon comparatively early in the course of the disease. One might as well prepare a table and compile statistics as to the operability of carcinoma of the stomach based on the autopsy records of patients who died in the most advanced stages of the disease, when the lymphatic nodes far beyond the primary lesion have been invaded and the tumor is no longer confined to the stomach, but has invaded other organs adjacent to it. The question as to what percentage of tumors

of the stomach may be removed must be and is being determined in the very earliest stages and on the operating table. So with tumors of the brain, the greater the number of cases brought to the surgeon in the earliest recognizable stage of the disease the sooner will we be able to say with some degree of accuracy in what percentage of cases there is a reasonable hope of being able to perform a radical operation.

There are two classes of cases in which a decompressive operation may be required. One in which there is reason to believe the tumor cannot be removed in its entirety and the other in which the tumor cannot be localized and yet the possible loss of vision, the intense headache and distressing vomiting almost demand the immediate adoption of some measure of relief.

Cases of tumors of the cerebrum in which localization is impossible are rather the exception, although in cerebellar lesions it not infrequently happens that the tumor cannot be localized.

A word or two might be said with reference to operations performed for the relief of cerebellar tumors. The anatomic relations of the structure in the suboccipital resemble in certain particulars those in the temporal region. In both the bone is covered with a well-developed musculo-aponeurotic layer, even of a greater bulk in the suboccipital than in the temporal region. For purposes of exploration it is necessary to reflect a flap of considerable size, the incision beginning at the mastoid process and following the line of the transverse sinus to the occipital protuberance, drops in a vertical direction along the median line. And when the flap is replaced great pains should be taken to approximate carefully not only the cutaneous, but the musculo-aponeurotic layer. When the tumor cannot be localized or for any other reason a radical operation is not deemed feasible a less mutilating incision will answer the purpose quite as well. A vertical incision should be made, beginning a little above the superior curve line and extending downward for a distance of

three or four inches. The edges of the wound can be retracted sufficiently to afford space necessary to carry on the subsequent steps of the operation. A much more perfect approximation of the wound may be obtained as the muscles are split in the direction of their fibres and not in various angles, as is the case when a curved incision is made following the line of the sinus. This vertical incision enables one to remove the bone only from one side, but if for any reason a bilateral craniectomy seems advisable, the muscle-splitting operation may be repeated on the opposite side. Such a procedure has many advantages over the conventional bilateral craniectomy in which the bone from one mastoid process to the other is removed. There is less chance of disturbance arising from traction on the pons or medulla if an intervening bridge of bone is left. In addition to this the bone in the region of the occipital region is very vascular, often riddled with vascular channels of such dimensions as to admit of a very profuse and sometimes alarming hemorrhage. The region immediately surrounding the occipital protuberance should be regarded as the dangerous zone and as such scrupulously avoided.

Failing to find the tumor, we have in certain cerebellar cases deliberately removed from one-quarter to one-third of the cerebellar hemisphere and have attributed the relief of pressure, in part at least, to this. In all our cases the operation has been confined to one side, and as yet we have not found it necessary to operate a second time for the removal of the bone on the opposite side. Even if it were conceded to be necessary to remove eventually the bone overlying both hemispheres the operation had better be performed in two stages rather than in one; patients with cerebellar lesions are at the best not very favorable subjects for operative intervention, and preference should be given, therefore, to this procedure, which in giving the desired results will require less time and be attended with less hemorrhage and traumatism of the tissues.

First, as to those cases in which the tumor cannot be local-

zed. There are two points in the technique of the operation about which there may be some difference of opinion, namely, the area of the brain to be uncovered and the incision of the dura. The decompressive operation consists solely in the removal of a portion of the cranial vault with or without incision into or removal of a portion of the dura. When there is no guide as to the situation of the tumor the operator is free to select either one of four areas: the frontal, parietal, occipital or temporal. In discussing this question several years ago, attention was called to the desirability for cosmetic reasons of avoiding both the frontal and occipital regions; there remain, therefore, but two areas from which to make the election: the parietal and the temporal. It is desirable, as Sanger suggests, to give preference to that portion of the skull beneath which may be said to exist a silent area of the brain. This is especially true of the right temporal region, so that, in the absence of any contraindication, this may be said to be the region of choice. Through a longitudinal incision, following the direction of the fibres of the temporal muscle, a section of bone equivalent to 6 or 8 square centimetres may be removed. One should be content to make but one opening, at least at the first sitting. This will be found in most cases to be sufficient to afford the necessary relief of pressure. If in the course of events there is evidence of a recurrence of increased tension, as shown by such symptoms as headache, vomiting or choked disk, a second opening may be made on the opposite side of the head. Such were the circumstances in one of our patients (Case 5). The headache, which had been relieved temporarily, recurred. A second opening was made on the opposite side of the head, and since that time, a period of about three years, the patient has enjoyed almost entire relief.

Speaking now only of those cases in which the tumor has been definitely localized, it is impossible to determine prior to the operation whether the tumor is one appropriate for a radical rather than a palliative operation. The duration



of the disease is a guide neither to the size nor to the nature of the tumor. Malignant tumors in the brain are many of them surprisingly slow in their growth, and, though of many months' or years' duration, may still be in the operable stage. A very large tumor may be present with comparatively slight disturbance, or a very small one may be very serious in its consequences. A tumor of several years' duration may be no larger than a hickery nut or walnut, and yet give rise to a condition which may ultimately prove fatal.

Recently I was called by Dr. Charles K. Mills to operate on a patient who had had symptoms of a tumor for more than a year. The localizing symptoms were very vague, but all seemed to point to a lesion of the left cerebellar hemisphere. This was thoroughly explored, but with negative results, except in so far that there seemed to be a very unusual degree of tension within the cerebellar fossa. This was so suggestive of the presence of a tumor as to justify a very careful search. The results were negative. About two weeks later the patient died, and a tumor as large as a peach was found compressing the under part of the occipital lobe directly in contact with the tentorium cerebelli. Its position satisfactorily explained the existence of cerebellar symptoms. As the brain was being lifted out of the cranium at the autopsy the tumor dropped on the table. Though of large dimensions it was clearly an operable one, and had the symptoms made it possible to localize the growth it could have been removed without any difficulty, and owing to its benign nature the operation would have resulted in a complete cure. In such a case had the operator proceeded deliberately to the performance of a decompressive operation and not attempted to explore the affected area the opportunity of saving the patient's life and of affording him permanent relief would have been thrown away.

In every instance, therefore, the operator should begin the operation with the intention, first, of attempting to expose the tumor. He should proceed as for the performance of an

osteoplastic operation; the flap should be carefully mapped out and reflected and the usual exploratory measures adopted. Failing to find the growth or finding an inoperable one, the propriety of a decompressive operation is clearly indicated. He must then determine as to whether he will remove the bone of the flap, wherever this may be, or close the flap and remove the bone from the area of choice, namely, over the right temporal lobe. When, as is true in the majority of cases, the tumor is situated in the postfrontal (motor) or parietal region the bone over the temporal region may be removed through the same opening, thus avoiding the necessity of another incision. This was the procedure adopted in one of our reported cases. The patient was suffering so intensely from headache that he was operated on the day of his admission to the hospital; not waiting to make a more careful study of the case with a view toward accurately localizing the growth, we proceeded at once with the intention of performing a decompressive operation. Sufficient was known of the case to lead us to believe the tumor was in the motor region. Accordingly this was laid bare and a very large vascular tumor, probably a sarcoma, was at once exposed. Deeming it to be inoperable and wishing to afford relief from the intracranial tension, only the lower half of the bone contained in the flap, which extended down to the Sylvian fissure, was removed, but through the same opening a considerable portion of the bone lying below the fissure and under the temporal muscle was also removed with rongeur forceps. As will be seen in the record (Case 10) the headache was immediately relieved. The most important question, however, in the technique of the decompressive operation is as to whether the dura shall be incised or removed. The region from which the bone is to be removed is by comparison a matter of slight importance. To be able to answer this question one must be in a position to state from experience, first, whether the escape of cerebrospinal fluid through a dural opening is essential, and secondly, whether sufficient relief of tension may be afforded

with the dura intact. As to the escape of cerebrospinal fluid there are certain observers, notably v. Bergmann, who believe that the beneficial effect of this operation is largely attributable to the escape of cerebrospinal fluid. It might be difficult, possibly, to prove or disprove this idea on theoretical grounds, but from our own experience we have not been able to note any radical difference in the results between those cases in which the dura was either left intact or if incised for exploration was closed immediately afterward. To the escape of a small quantity of cerebrospinal fluid through a temporary opening in the dura could scarcely be attributed the relief, which extends over a period of months or years. In so far, therefore, as the results of the operation are concerned, it makes no difference whether the opportunity for drainage was afforded by a permanent opening in the dura. In the most satisfactory of the cases under our care the dura was closed; in one case, particularly, in which an exploratory dural incision was not entirely closed, the patient enjoyed no appreciable benefits from the operation.

I think it is very generally believed by those who have had but little experience with these operations that the success of the operation depends on the establishment of an opening in the dura as well as in the skull. It is said that the dura is not elastic enough to stretch sufficiently when subjected to pressure. That the dura will stretch, when the overlying bone is removed, sufficiently to afford adequate relief of tension has been demonstrated in our cases over and over again. Take, for example, a case which was operated on for a tumor believed to be in the occipital region. The tumor was not to be seen on or near the cortex, but there was a very much dilated right ventricle, possibly due to a tumor at the base, cutting off the intraventricular communication. If we turn to the illustration (Fig. 1) we see a genuine hernia cerebri, a hernia in which the dura as well as the scalp form the coverings. This patient has been under observation for a number of years and for the past year the hernia has not increased

in size. The optic neuritis was in this case too far advanced to enable us to save the patient's vision: in other respects the patient enjoys excellent health and is now in attendance at an educational institution. A decompressive operation was




FIG. 1.—Showing the protrusion subsequent to the development of a hernia cerebri following a decompressive operation, in which, after exploration, the dural wound was closed.

not a matter of choice in this case; at least at the outset this was not contemplated. The brain bulged so through the opening that it was impossible to close the flap without removing the bone.

As an example of how rapidly the dura may stretch when subjected to excessive pressure, one of the cases of our series may be cited in which an exploratory craniotomy revealed a large and very vascular ill-defined sarcoma. Its removal was out of the question; the incision in the dura was closed and a section of bone removed. Several records were made of the convexity of the head (Fig. 2) at short intervals, and

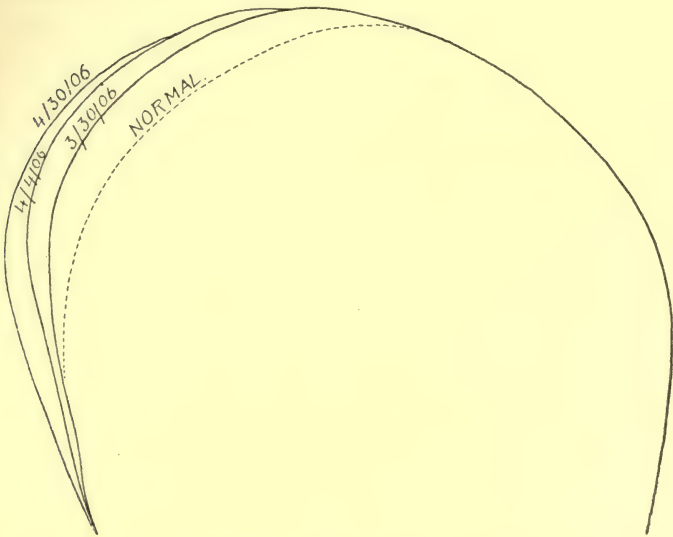


FIG. 2.—Showing the rapid development of a hernia cerebri in the decompressive operation. After the operation the dural wound was closed. The dotted line represents the normal contour on the affected side. The other lines represent the contour of the head: (1) March 30, 1906, one week after the operation. (2) April 4, 1906, twelve days after the operation. (3) April 30, 1906, five weeks after the operation.

it is rather surprising to find how rapidly the dura had expanded to accommodate the growth. On the other hand in another case in which a tumor was exposed and found inoperable the dural incision was only partially closed. The results in this case were as compared with the other, in so far as the relief of symptoms was concerned, much less satisfactory.

Whatever else may be said either in favor of or against the removal of the dura it should be borne in mind that if the dura is removed and any complication arises in the repair of the wound it is more than likely that a fungus cerebri will develop. An accidental wound infection, the persistence of a sinus, the remains of a drainage tract may result in infection of the exposed brain tissue and that very fatal condition a fungus cerebri. In the hands of operators experienced in this field of surgery the danger is very slight, but it is questionable whether the removal of the dura should be resorted to as a universal practice. While in a given number of cases the results may not be so pronounced the mortality will be higher unquestionably if the dura is removed in every case. Inasmuch as the brain may herniate through the opening in the skull when the dura is left intact, there is really no necessity for removing more than the overlying bone. If the dura is disturbed at all, the operator should be content with making a crucial or radiating incision in it, and in many cases it may be advisable to reserve this step of the operation until indications arise for further intervention. This course was pursued in one of our cerebellar cases in which temporary relief having been afforded the symptoms, particularly pain, recurred.

A muscle-splitting incision was made, the edges of the wound retracted and a crucial incision made in the dura. The results were very gratifying and have continued so now for a period of several months.

**MORTALITY.** Every one of the twelve patients operated on at the University Hospital, eleven by Dr. Frazier and one by Dr. Martin, recovered. The absence of any fatalities in the entire series is worthy of note. When one is debating as to the advisability in a given case of performing a radical or palliative operation, consideration should be given to the fact that there is at least no immediate risk as to life from the decompressive operation. In the palliative measure we have an operation which almost inevitably relieves the sources of discomfort and suffering, not only without endangering but

frequently prolonging life; in the radical measure we are undertaking an operation, which has a comparatively high mortality and is only successful in a small percentage of cases in finding and removing the tumor.

RESULTS. The opinions expressed in the paper are based on observations in a series of fourteen cases. The first operation was performed in 1898 and the last March 20, 1906. In but one of the entire series did the operation fail to afford the relief which would justify its performance. There was in this case some immediate improvement, but so slight as not to warrant the promise of relief which was held out to the physician and relatives of the patient. The operation was performed in March of this year; the patient was at the time almost comatose and her life was in immediate danger. At the present writing, May 25, 1906, her physician, Dr. Thomas O. Nock, writes me that the patient has been moved to the country, but her condition is little, if any, improved. All that can be said of this case is that life has been prolonged. The results in this case are a striking contrast to those following an operation performed in October, 1903. This patient probably has two lesions, one in the parietal lobe and one in the cerebellum, and before the operation suffered intensely from headache and neuralgia. When last heard from two and a half years after the operation she still enjoyed absolute relief. Perhaps the most brilliant of the series was a patient who presented the clinical symptoms of a cerebellar lesion, intense choked disk, frightful headaches, and persistent nausea, vomiting and ataxia. This patient (Case 4) was operated on two and one-half years ago and when last seen, February of the present year he was the picture of health and was engaged in hard manual labor. Neither headache nor nausea recurred, and though he had a choked disk, so elevated that he could scarcely recognize large objects, his vision is now practically normal. Apart from the fact that he occasionally has attacks of what he calls "dizzy spells" he is to all intents perfectly well and now weighs 184 pounds.

The decompressive operation offers to the patient relief from the three cardinal symptoms of cerebral tumor, headache, nausea, and vomiting, restores vision, and if the lesion is in the cerebellar fossa relieves ataxia and vertigo. Mention has already been made of the dangers of postponing operation once there are signs of choked disk. One of the strongest arguments in favor of the palliative operation is the opportunity to save or restore the patient's eyesight. Without exception the choked disks subsided in every instance but unfortunately in at least three of our cases the patients remained totally and hopelessly blind because the optic neuritis was of so long duration that the nerve had undergone atrophy. The subsidence of the choked disk takes place as rapidly when the dura is left intact as when it was incised. The case, which in Dr. de Schweinitz's opinion and experience responded most promptly to the operation was one in which the dura was not disturbed. Although the operation was performed only seven months ago the patient's vision has continued to improve. The prospects of preserving the eyesight alone would justify the operation, but no less so the opportunity of relieving headache. Our results with respect to headache have been uniformly good. There were two or three cases in which the headaches did not entirely cease, but in these there were intervals of relief and the headaches were less severe. As to the duration of the period of relief the longest in our series is between two and one-half and three years. In at least three of our cases the intensity of the pain seemed to be as great as that of a tic douloureux, and one patient had become addicted to the liberal use of morphine; yet in each one of these the relief was immediate, absolute, and permanent. In one instance the suffering was so intense that the operation was performed within a few hours of the patient's admission to the hospital, before an opportunity was afforded to determine with any degree of accuracy the location of the tumor. What has been said of the beneficial effect of the operation on the



choked disk, even when the dura was left intact, may be repeated in dealing with headache. Not that the dura was not opened in some cases for exploration, but in almost every instance the dural wound was immediately closed with sutures.

Mention might be made of the fact that in two instances Nature had already begun to relieve the intracranial tension. In these cases the tumor had grown through the dura and in one instance had almost perforated the skull. In conclusion we may say that there is no form of treatment, either medical or surgical, which, in the presence of an incurable lesion, causing sometimes great discomfort, sometimes intense suffering, so uniformly affords so great and enduring a measure of relief.

SUMMARY OF CASES.<sup>1</sup>

	Location of lesion.	Period since operation.	Results.
1. L.	Cerebrum	1 year (operation was not performed but relief of pressure occurred spontaneously).	Alive and free from pain.
2. B.	Cerebellum	7 years.	Almost complete recovery during two or three years; present condition unknown.
3. G.	Cerebellum and cerebrum	2 years and 7 months.	Alive and free from pain.
4. E.	Cerebellum	2½ years.	Alive and free from pain.
5. D.	Cerebellum	2½ years.	Alive and free from pain.
6. B.	Cerebrum	1 year and 7 months.	Alive and free from pain.
7. M.	Cerebellum	8 months.	Second operation was performed; tumor found and removed.
8. K.	Cerebellum	7 months.	Died seven months after operation.
9. L.	Cerebellum	7 months.	Alive and free from pain.
10. S.	Cerebrum	2½ months.	Alive and free from pain.
11. F.	Cerebellum	2½ months.	Alive and free from pain.
12. D.	Cerebellum	2 months.	Radical operation was performed two months after palliative operation.
13. C.	Cerebrum	.....	Alive but little if any relieved.
14. S.	Cerebellum	About 3 years.	Improved; death from tumor about three years after palliative operation

<sup>1</sup> A case under the care of Drs. Spiller and Martin to which reference is made in this paper, is not included in this table.

## ORIGINAL OBSERVATIONS.

CASE 1.—Probably tumor of motor area. The following case is of great interest as it seems to be one in which relief of symptoms from intracranial pressure occurred by escape of cerebrospinal fluid through the cribriform plate of the ethmoid bone without operation, and it may be, therefore, regarded as a case in which relief was afforded in a manner similar to that in palliative operations.

*Examination.* L. was seen by Dr. Spiller in consultation with Dr. Ernest Laplace, Aug. 13, 1904, at which time the following notes were taken: In showing the teeth the left corner of the mouth is drawn up better than the right. When drawing up each corner of the mouth separately he draws up the left better than the right. The eyelids are closed equally well on the two sides, and the resistance to any attempt to passively open the lids is as good on one side as on the other. Percussion of the scalp shows no area of tenderness. When the tongue is protruded it tends to deviate a very little toward the right. The movements of the tongue are free in all directions, and the tongue is not atrophied. The movements of the eyeballs seem to be normal in all directions, except that the movement to the left may be a trifle impaired. There is no nystagmus. The reaction of the iris to light is preserved, but tardy on both sides. Convergence and accommodation cannot be tested satisfactorily on account of the mental condition. The pupils are equal and regular. The masseter muscle contracts well on each side, but the left masseter contracts a little better than the right when the patient bites. He says that he feels touch more distinctly on the left side of his face. Pin-prick is probably perceived in the right side of the face as well as in the left, but his statements regarding sensation are not to be relied on. He understands what is said to him, although he appears dazed and has difficulty in replying, but apparently is not aphasic.

Upper limbs: The grasp of the right hand is distinctly impaired and is decidedly weaker than that of the left hand. The upper limbs are well developed and equally so. The biceps and triceps tendon reflexes on the right side are distinctly prompter than the corresponding reflexes on the left side. After a spasm the right upper and right lower limbs seemed to be almost completely paralyzed, and Dr. Laplace says that this paralysis following a spasm is only temporary.

Lower limbs: The lower limbs are well developed and there is no atrophy in any part. The patellar reflex is about normal on the left side, but exaggerated on the right side. There is no ankle clonus on either side. The Achilles tendon reflex is about normal on each side, and a trifle prompter on the right than on the left. The Babinski reflex is very pronounced on the right side; the big toe as well as the adjoining toe being drawn upward distinctly. The Babinski reflex is not present on the left side, the movement being flexion.

During the examination an epileptic attack occurred. It began with a slight flexion of the right forearm on the arm. This movement lasted from thirty to sixty seconds before the face was involved. The right lower limb seemed to be involved before the face. Clonic movements of small extension began in the right lower limb, afterward the movements occurred in the right upper limb. Both right upper and lower limbs were very spastic. The right side of the face was thrown into violent tonic spasm, and the lids on both sides were equally affected. There seemed to be a slight tendency of the eyeballs to turn to the right, but this was not pronounced. The lower part of the left side of the face, the left upper and lower limbs showed no convulsive movements and the left limbs were not spastic. Consciousness did not seem to be lost during the attack. Urine was not voided during the attack, but was immediately after the attack, voluntarily. After the attack the man was drowsy and passed into a light sleep lasting about five minutes.

*Further Examination.* A further examination on August 14th gave the following results: Sensation for touch is more acute on the left side of the face; sensation for pain is more acute on the right side of the face; this agrees with the findings of yesterday. The grasp of the right hand is not so good as it was at the beginning of the examination yesterday. A knife or a pencil put into the right hand is distinguished without difficulty when the eyes are closed. The weakness of the right upper limb has been much greater since the attack that we saw yesterday than at any time previously. He can barely lift the right hand from the bed. The paralysis of the right lower limb which developed after the attack that we saw yesterday disappeared in part during the afternoon, whereas, that of the right upper limb has persisted with very little change. The sensation for touch and pain seems to be more acute in the right lower limb than in the left. He seems to understand what is said to him, but has difficulty in getting words to reply and is partly motor aphasic. He yawns repeatedly and Dr. Borsch has noticed that during the convulsive attack the eyeballs are drawn toward the right but remain in this position only during a short part of the attack. The left pupil is larger than the right and the left recovers more slowly than the right.

*Subsequent History.* The following notes were obtained from Dr. Laplace: The patient continued to improve under high doses of iodide of sodium (100 grains daily) until all symptoms of paralysis had disappeared. Headaches also disappeared, but the optic neuritis continued. The field of vision gradually lessened until total blindness ensued, January, 1905. The patient remained in this condition until May, when convulsions attended by severe headaches returned, exactly similar to those seen by Dr. Spiller in August. About forty convulsions took place in the course of the first week in May, 1905. He suffered with intense headaches and was suddenly greatly relieved of all headache and of nearly all the other symptoms on expectorating

what seemed to be a certain amount of purulent material. (Dr. Laplace did not see the patient at the time of this nasal discharge.) Whether the material contained cerebrospinal fluid or whether it was pus which found its way into the nose, after burrowing its way through the cribriform plate of the ethmoid can, therefore, only be conjectured. In June and July the patient improved, but his lower extremities remained weak. This weakness of the lower extremities has increased gradually from July, 1905, until the present time. Mental hebetude gradually set in, but there has been an absolute freedom from headache, from July, 1905, until now.

*Present Condition.* Complete blindness; perfect consciousness. He is thoroughly rational when aroused; otherwise quite listless. There is great weakness of lower extremities, requiring support to enable him to walk. Both arms are quite strong. Excellent appearance; good appetite and digestion; full control of bowels and bladder. Freedom from headache. Last report says that general weakness is gradually becoming more marked. Mercury and iodides have been continued. The patient and his family have opposed any surgical interference.

CASE 2.—Tumor of cerebellum (?). Mrs. M.B., was admitted to the Polyclinic Hospital, Dec. 31, 1898, under the care of Dr. Spille, and Dr. Roberts.

*History.* Patient had been married twenty-six years, a widow, eighteen years; had two children, twenty-five and twenty years old respectively, at time of death. Emigrated to America five years ago. She had good health until previous to present trouble. Her present condition began two and one-half years ago with violent headache in the left occipital region. Her symptoms have gradually increased in number and intensity, until at present they consist of very severe headache in the left occipital region, great tenderness over the same region, extreme vertigo, especially when lying on the left side in bed or attempting to walk; very ataxic gait so that she staggers like a drunken person and falls to the left side or backward.

*Examination.* The patellar reflexes are absent; sensation in the legs is obtunded and movements of the lower extremities somewhat restricted (she cannot cross her legs). During the last few months she has been getting rapidly worse. A diagnosis of cerebellar tumor was made, and the patient was admitted to the wards of the Polyclinic Hospital for an exploratory operation. Urinary examination: color, amber; cloudy, reaction acid; specific gravity, 1020; no albumin or sugar.

*Operation.* On June 4, 1899, under ether, the skull was opened by trephine and lion-jawed forceps, a hole about one and one-half inches in diameter being made over the probable seat of the lesion as indicated above. The dura mater appeared normal, as did the bone removed; the dura mater was laid back, the brain exposed, the finger inserted and the surface of the brain palpated for an area of five inches or more in diameter, but no abnormality was detected. A puncture was

then made into the convolutions of the brain in several directions with a grooved director to the depth of three-fourths inch without finding any lesion. The dura mater was then sutured, and the skin flap brought into place and secured. The patient made a good recovery from the anæsthetic, but her temperature began to rise rapidly that night, reaching 101° F. at 7 P.M. Infection being feared, the dressing was removed, the sutures partially withdrawn, and the wound flushed with normal salt solution. The wound was re-dressed at frequent intervals since, all the sutures removed.

*Results.* June 30th. The patient has been slowly improving since the 20th, the temperature having been practically normal. The parietal region on the operated side has almost entirely lost its peculiar tenderness to touch, and the headache occurs only occasionally, is slight and is now located in the frontal region. The patient made a complete surgical recovery, and almost all her symptoms disappeared. After two or three years she returned to Europe. She has been seen recently and is in good health.

CASE 3.—Tumor of the pons. Mrs. G., aged forty-five years, was admitted to the University Hospital under the care of Dr. Charles K. Mills, October, 1903.

*History.* Tumor of the pons, probably second lesion in the parietal lobe; cyst evacuated; permanent disappearance of severe headache and facial neuralgia. This patient, a woman about forty-five years old, first came under the care of Dr. Mills in November, 1902. One year before coming under observation she had an attack of vertigo without unconsciousness and after this partial paralysis of the left third nerve was observed, ptosis, dilated pupil and paresis of the internal rectus being present, according to the physician then in attendance. From the history she also appeared to have had temporary paralysis of the left side of the face. She had subsequent similar attacks, some of these shortly before coming under observation. In one of the recent seizures she was found in the cellar, pacing up and down with her hands above her head, eyes dilated, and apparently struggling against suffocation. She was taken upstairs and put to bed; she tried to speak, moving her jaws without uttering a sound; her face was pale, her eyes were open. At the time of the first examinations she had paresis of the left side of the face, partial ptosis, pupils equal and responsive, the superior rectus not being as active on the left side as on the right.<sup>1</sup>

*Examination.* The patient was again examined by Dr. Mills and Dr. Spiller, Sept. 22, 1903. The left side of the face was paralyzed in the entire distribution of the seventh nerve. She complained of much pain, confined to the left side of the face and in the distribution

---

<sup>1</sup> The case is fully reported as Case 6 in a paper by Dr. Charles K. Mills, on "The Diagnosis of Tumors of the Cerebellum and Cerebello-pontile Angle, with Special Reference to their Surgical Removal," New York and Phila. Med. Jour., Feb. 11 and 18, 1905.

of the fifth nerve. The masseter and temporal muscles contracted well in chewing on each side. No distinct objective disturbance of sensation on the left side of the face was made out. The left external rectus seemed to be the only external ocular muscle distinctly paretic. Astereognostic conception as tested in the right hand was almost complete.

She complained of much pain on both sides of the forehead, extending down the left side of the face to the lower border of the lower jaw. The pain did not extend below the median line of the lower jaw; it extended to the mastoid process, but not beyond this on the left side; it did not extend into the neck. She had constant pain in both temples, but it was greater in the left than in the right. All points of exit of the fifth nerve were painful to pressure; as much so on the right side as on the left. Sensation for touch and for pain on the two sides of the face seemed to be normal; she felt a touch or pin-prick as well on the left side of the face as on the right. In such instances, as when chewing a hard crust of bread, the left masseter contracted, but not so well as the right; in opening the mouth the lower jaw did not deviate distinctly. She complained of a sense of numbness in the left side of the face; this involved the entire distribution of the fifth nerve and extended on the left to the temple, but not far beyond the border of the hair. There was considerable improvement in the paralysis of the orbicularis palpebrarum. There was complete paralysis in the lower distribution of the left facial nerve. The right side of the face was normal. She did not have any nausea and seldom had spells of vertigo, although formerly the latter occurred frequently. She showed at times a tendency to fall backward or toward the left, but did not stagger as much as formerly; closing the eyelids did not affect the gait very distinctly. Hemiasynergia was not present on either side.

As the patient was slowly getting worse and was suffering extremely with pain in her head and face, it was finally decided to remove her to the University Hospital for the purpose of having an operation, which might at least be palliative. Her pain increased until it became torturing, and for days before the operation it was necessary to keep her continuously under the effects of morphine or codein. No change of any movement occurred in her local symptoms after the above recorded notes.

*Operation.* The operation was performed by Dr. Frazier, Oct. 14, 1903, under ether anæsthesia. A musculocutaneous flap together with the periosteum was reflected and an opening was made in the skull with the chisel and enlarged with rongeur forceps. Nothing abnormal as regards pulsation nor consistency of the left lateral lobe of the cerebellum was noted. The dural flap was reflected; at one point this flap was adherent to the underlying brain. Cerebellar tissue bulged only moderately through the wound. On exploring with the index finger in the region of the cerebellopontile angle some adhesions were

separated on the lateral aspect of the cerebellum. This was followed by a gush of fluid which had evidently been walled off by adhesions. After the evacuation of the cyst the bulging subsided immediately and with a brain retractor it was possible to inspect the region of the cerebellopontile angle and to demonstrate to those present at the operation, the fifth, seventh, and eighth cranial nerves. It was noted on the blood pressure chart that when the dura was opened the blood pressure dropped thirty points and that on introducing gauze packing, or on compressing the brain with the retractor that the blood pressure rose forty points. The patient's condition was not depressed to any considerable degree by the operation; on her return to bed the pulse was 145; respirations were 40, and blood pressure was 115.

The interesting feature of the case was the ease with which the cranial nerves were exposed after the cyst had been evacuated.

The patient reacted well after the operation and passed a fairly comfortable night. There was very profuse oozing of blood and cerebrospinal fluid, necessitating frequent reinforcement of dressing. The patient was much nauseated, vomiting curds of milk and bile-stained fluid. She complained of pain in her temples. An incomplete examination showed that sensation was present on both sides of the face and no inequality of pupils was noted. On October 15th, the wound was dressed and found in good condition; the drainage was removed, there was a free flow of cerebrospinal fluid.

*Subsequent History.* An examination by Dr. Mills and Dr. Spiller on October 15th, resulted as follows: No cutaneous anæsthesia was present on either side; not even any hypæsthesia on the left. There was no great impairment of the motor division of the fifth nerve, the masseter and pterygoid muscles being tested. Complete paralysis in the muscles supplied by both the upper and lower branches of the seventh nerve was present. She was completely deaf in the left ear.

Slight paralysis in the right upper extremity was noticed. Astereognosis or pseudoastereognosis was present in the right hand. Anæsthesia for both touch and pain and hyperæsthesia were absent. She had had no pain in the face or head since the operation and had required no anodynes.

*October 19th.* The wound was again dressed and the stitches were removed; the wound was healed, with the exception of one angle; a small piece of gauze was inserted for drainage. The patient's general condition had been very good. Her pupils were normal.

*24th.* The surgical condition was entirely satisfactory; the wound was healed, with the exception of one spot, which was rapidly granulating. The patient's general condition had rapidly improved since last noted. She was regaining strength, had been sitting up and was quite comfortable.

*29th.* Patient was discharged, the surgical condition left nothing to be desired; the wound was completely healed; there was no bulging of the flap, no signs of inflammation or œdema of the scalp. She had

not had any pain in the head or ears; the only discomfort had been some irritation of the conjunctiva of the left eye, which was probably due to facial palsy.

*Results.* When the patient was last heard from two years after the operation, the relief from headache and neuralgia continued, although, as previously stated, the pain for some time before the operation was of the most intense character. In other respects her general condition has been good. She still continues to be partially paralyzed, with astereognosis and sensory changes on the right side and still has paralysis in the distribution of the left seventh nerve. It is altogether probable that a lesion of some sort is still present; not improbably she has more than one lesion, as the symptoms point both to the pons and to the left parietal lobe. The case is especially interesting as showing how the cerebellopontile angle can be exposed and how pain and other symptoms of brain tumor are sometimes relieved even when full success is not obtained.

CASE 4.—Tumor of the cerebellum or cerebellopontile angle. The tumor was not found, but great benefit was obtained by a craniotomy associated with excision of a portion of one lateral lobe.

*History.* C. E., aged twenty-three years, was admitted to the University Hospital, December 7, 1903, and was placed under the care of Dr. Charles K. Mills, who reported that his illness began several months prior to his admission to the hospital, the principal symptoms being dizziness and intense headache, starting in the occipital region and radiating toward the forehead. Five weeks later his sight began to fail and a week later some weakness of the left arm and leg were noticed.

At the time of his admission to the hospital he was suffering from the most distressing headache, which was almost constant, and from vertigo and ataxia to such an extent that it was almost impossible for him to walk alone or without support. Nor could he even stand alone unless leaning against some stationary object. His vision was so affected that he could not see gross objects and the examination of his eye-grounds revealed the presence of very marked choked disks and optic neuritis.<sup>1</sup>

*Operation.* The patient suffered so that it did not seem justifiable to postpone operation for further and more elaborate study of the case. Accordingly within a week of his admission to the hospital a left cerebellar craniectomy was performed by Dr. Frazier. The dura was noted to be unusually tense, and on reflecting the dural flap a considerable portion of the cerebellar hemisphere protruded through the opening. It was found to be almost impossible on account of the protrusion of

---

<sup>1</sup> This is Case 4 in Dr. Mills' paper, "The Diagnosis of Tumors of the Cerebellum and Cerebellopontile Angle, with Special Reference to Their Surgical Removal," New York and Phila. Med. Jour., Feb. 11 and 18, 1905.



cerebellar tissue to make further exploration, so the operator proceeded to remove from one-third to one-half of the lateral lobe. After this was accomplished, exploration was continued, but to no avail. No tumor could be seen or felt in any portion of the left cerebellar fossa.

*Subsequent History.* The postoperative record of this patient is one of unusual interest because of the remarkably rapid improvement which followed. Within one week of the operation the patient's headache had entirely disappeared; his vision was restored so that he could see minute objects on the ceiling as he lay in bed and his vertigo and ataxia had almost entirely disappeared. At no time during the convalescing period was the patient's condition such as to give any concern. He was kept under observation in the hospital for a period of two months, and inasmuch as there was not the slightest return



FIG. 3.—Showing the general robust appearance of patient one and one-half years after decompressive operation for tumor of the cerebellum.

of symptoms he was allowed to go home, with the understanding that he would return to the hospital if any of his cerebellar symptoms recurred.

*Present Condition.* He returned to the hospital for an examination March 5, 1906. About two years and four months had elapsed since the operation and his headache, nausea, and vomiting have never recurred. His vision is practically normal and he is now engaged as a laborer in the Pennsylvania Railroad shops at Altoona. It should be said, however, that he occasionally has some attacks of vertigo. His weight has increased to 184 pounds and he is in all other respects apparently perfectly well (Fig. 3).

CASE 5.—Tumor of the cerebrum; decompression operation affording relief from headache for a period of three years.

*History.* W. D., aged twenty-two years, was admitted to the University Hospital, Nov. 5, 1903, having previously been under the care of Dr. W. O. Hermance. He was admitted to the service of Dr. William G. Spiller, by whom the following history was elicited: He has been suffering from headaches since 1897 and for the past nine months they have been especially severe. He has furthermore often complained of nausea, vomiting, and dizziness and his sight is completely lost.

*Examination.* On examination there was found to be no involvement of either the fifth or seventh nerves. The movements of the tongue and of all the limbs were unimpaired. The biceps tendon and the triceps tendon reflexes were not specially active. The grasp of each hand was normal, as was the resistance to passive movements in all the extremities. There was no involvement of the bladder or rectum and no ataxia of upper or lower limbs. There was no deviation from normal as to stereognostic conception in either hand, the gait was normal, there was no tendency to sway or fall, there was no Babinski reflex on either side and the patellar reflexes were exaggerated. There was persistent ankle clonus on the right but none on the left side. There was no word deafness and no aphasia. His sister reported that about three months previously he was unable to speak at all for at least an hour, but that this was the only time he ever entirely lost the power of speech. He was at times delusional, and imagined he was being put into a hole. He had what he calls "sinking spells," in which he felt weak and his heart stopped beating.

About six months prior to his admission to the hospital he complained of stiffness (?), probably weakness, in the back, left side of the neck, in the left arm and left leg. He had never had any convulsions, but from April to August of the present year, his whole body would get stiff for about half an hour. His memory is better than it used to be. He listens attentively to what is read to him and remembers it better than the persons who read it. The headache had been frontal and bilateral until February of this year and it seemed to have become more localized to the left temporal region.

Dr. Thorington, who had examined his eyes, reported that there were no ocular palsies, but choked disk in both eyes, slightly more advanced in the left. There had been numerous hemorrhages, large and small, old and recent. Examination of the urine on one occasion prior to his admission to the hospital revealed a few hyalin casts and a small quantity of albumin. Since the examinations at the hospital, after repeated examinations, only on one occasion was a suspicion of hyaline casts, at no time was there albuminuria.

November 5, 1903, Dr. Shumway made the following ophthalmic report: No light perception. Right eye, atrophy following choked disk. Nerve head much swollen, veins tortuous, no hemorrhages. Left eye, nerve head still more swollen, some atrophy, hemorrhage on the nasal side of the nerve, numerous white points of exudation.

6th. It was noted on this date by Dr. Spiller that pupils were dilated,

there was no reaction to light and no ocular palsies. The ophthalmic reflex was present on each side. Patient closed the eyelids firmly and wrinkled the forehead well on both sides, the tongue was protruded straight, not wasted and there were no fibrillary tremors. His hearing was apparently not affected. He swallowed without difficulty. There was some tenderness to percussion over the left temporal region. There was no word deafness nor motor aphasia.

*Upper Limbs.* Movements of the upper limbs were free at all points. The biceps and triceps reflexes hardly obtainable on either side. Grasp of each hand and resistance to passive movements were normal. Sensation for touch and pain normal in all parts of the body, and the sense of position and stereognostic conception were unimpaired. There was no wasting.

*Lower Limbs.* Voluntary power normal, no hemiasynergy on either side and no wasting of the lower limbs. The sense of position was normal on both feet. The patellar reflexes were distinctly exaggerated on either side and more prompt on the left side. There was a slight indication of ankle clonus on the right side, although clonus was not as persistent as at the last examination. There was no clonus on the left side. The Achilles tendon reflex was exaggerated on each side, but more so on the left. The patient stood well with his feet together and the eyes open or shut. His gait was normal, although it was uncertain on account of his blindness. There was no Babinski on either side.

Further examination of the other organs including those of the thorax and abdomen proved negative.

*Operation.* Craniectomy was performed by Dr. Frazier under ether anæsthesia and an osteoplastic flap was reflected in the left frontal region. It was noted at the time that the skull and the dura were abnormally thick. There were no adhesions between the dura and the skull. Pulsation was visible and the brain did not bulge when the dura was reflected. Especially at the superior and anterior aspect of the opening the consistency of the brain seemed abnormally soft and an exploratory needle was introduced in various directions, but with negative results. The dural flap was replaced with sutures and the bony portion of the osteoplastic flap was removed for the purpose of relieving intracranial pressure.

*Subsequent History.* The patient remained under observation in the hospital until January 27, 1904, at which time it was noted that he had had no headaches since Dec. 28, 1903. His general condition had improved and he had gained in weight and strength. The last ophthalmic examination prior to his discharge from the hospital made Jan. 1, 1904, notes that the nerve is becoming more and more atrophied.

*April 15, 1904.* The patient was admitted to the hospital again with a history of having had no recurrence of headache after he had been discharged; from this time on the headaches recurred generally

on the right side of the head in the occipital region, accordingly was it deemed advisable to perform a second palliative operation and on April 16, 1904, Dr. Frazier performed an osteoplastic operation, reflecting a flap from the right temporoparietal region, removing a flap 10 cm. broad and 7 cm. wide. It was noted at the time that there was no visible pulsation and that the brain appeared to be under considerable tension. The bone at the margin of the upper aspect of the opening appeared abnormally dark in color and unusually porous. An exploratory needle was introduced into the pons at about the middle of the opening but no fluid was detected.

Following the operation the patient complained for a few days of a severe supraorbital neuralgia which was attributed to the pressure which had been effected by the use of a pneumatic tube applied for the purpose of controlling hemorrhage. The patient was discharged from the hospital April 28th, about two weeks after the operation. His headaches had not entirely disappeared, although they were comparatively mild in character and the patient no longer required hypodermic administration of morphia to which he had been accustomed heretofore.

*Present Condition, May 1906.* The last observation was made two years and six months after the first operation and two years and one month after the second operation, and at this time it was reported that the patient had enjoyed almost absolute relief from his headaches. He is able to perform the duties connected with the management of a cigar store and with the exception of his loss of eyesight he appears to be entirely well. The optic neuritis was so far advanced when the patient was first seen that the possibility of saving his sight was out of the question.

CASE 6. —Tumor of the cerebrum.

*Patient.* M. B., aged seventeen years was referred to the University Hospital, by Dr. R. Ross Jordan, Tyler, Clearfield County, Pa., and transferred from the service of Dr. Charles K. Mills, October 9, 1904.

*History.* He was struck on the back of the head nine months ago. He was not unconscious at the time he fell. About an hour later he became dazed, walking around aimlessly, remaining in this state for about half an hour. On Jan. 28, 1904, he was seized with shortness of breath, succeeded by tingling in the ears, and fell to the ground. It was said that during the convulsion his eyes were turned from side to side and that the whole body with the exception of the hands and wrists, fell into a state of spasm, lasting from five to seven minutes, with frothing from the mouth. Since that time he has had five attacks of this character, the later attacks having been preceded by violent occipital headache and vomiting.

*Examination.* He has marked optic neuritis, complains of intense headache and occasionally vomits. There is no hemiasynergia on either side. No paralysis of either facial nerve, the masseter, and temporal muscles contracting well on either side. Sensation for pain

and touch is equal on both sides, so that there is no involvement of either the sensory or motor root of the fifth nerve. The extraocular movements are normal, but there is a lateral nystagmus when looking from either the right or left. The tongue is protruded straight, moves freely and there are no tremors. The head is not tender to percussion.

*Upper Extremities.* Grasp of each hand is equal and strong; sensation for pain and touch normal in each upper limb and it is the same on both sides. Stereognostic perception is normal in both hands. Biceps and triceps tendon jerk are not distinct in either side. There is no muscular atrophy. Resistance to passive movements is normal in both upper extremities. In the lower limbs no hemiasynergia. Resistance to passive movements normal, patellar reflex normal on each side, and there is no Babinski reflex. Sensation for touch and pain are the same on both sides, gait and station are normal with the eyes open or shut. There is not the slightest trace of hemiparesis or disturbance of sensation on the left side.

*Ophthalmologic Report.* From the service of Dr. de Schweinitz. Ophthalmic diagnosis hemianopsia. Pupils react normally to light and accommodation, the muscle balance normal; eye-grounds, media clear; O. D. marked optic neuritis, 5 D. no change in macula; O. S. swelling of disk 5 D; a few small fresh hemorrhages in the fundi. No change in the macula.

*Operation.* Dr. Frazier, Oct. 10, 1904. Inasmuch as the symptoms pointed entirely to a lesion in the occipital lobe, an osteoplastic flap was reflected exposing this region. The dura exposed in the opening presented a mottled appearance as though the seat of an organized traumatic or inflammatory exudate. There was slight visible pulsation and there seemed to be considerable tension. When the dural flap was reflected the brain immediately bulged through the opening even beyond the level of the scalp. From the opening a jet of yellowish-red fluid spurted three or four inches. About 45 c.c. of fluid were evacuated in this way. In order to close the defect it was necessary to reflect a flap from the pericranium inasmuch as the brain still bulged considerably through the opening. This was taken from the section of bone contained in the flap and the bone itself was removed. The wound was closed with interrupted silkworm-gut sutures and drain introduced through counter openings.

*Subsequent History.* October 13th. Since the operation the headache had entirely disappeared and the patient is now able to see objects which he could not before the operation.

24th. On the date of his discharge from the hospital it was reported that the patient felt better than he had for some months and that the vision of both right and left eyes had improved.

R. E. V. before the operation 6/30, at the present time 6/22.

L. E. V. before the operation 6/30, at the present time 6/15.

There is still a left hemianopsia and the swelling of the disks has decreased from 5 to 3 D.

Dec. 21, 1904. The patient was readmitted to the hospital. He returned to the hospital chiefly owing to the fact that the hernia cerebri had increased and especially for the past two weeks his vision had been failing. During the past two months he had gained forty pounds. Examination of the eye-ground showed that the choked disk had entirely subsided, but that there was marked optic atrophy. There was left lateral hemianopsia for light only.

23d. The original field of operation was exposed and the dura was found intact. On reflecting the latter a canula was introduced and immediately a large quantity of blood-stained fluid escaped. Immediately after the evacuation of the fluid the hernial protrusion collapsed. The question arose at the time of the operation as to whether we were dealing with a cyst of the occipital lobe or the dilated horn of the lateral ventricle. No evidence could be detected of a neoplasm in the neighborhood of the operative field. The wound was closed in the usual way.

29th. Patient has made a satisfactory convalescence from the operation. There has been a free discharge of cerebrospinal fluid from the wound, requiring reinforcement of the dressing from time to time.

January 27, 1905. The patient was discharged from the hospital today, the wounds having healed *per primam* throughout. The hernia was not so prominent as it was before the operation. The patient's condition, with the exception of his impairment of vision, is entirely satisfactory. The optic atrophy which was discovered after the choked disk had subsided of course precludes the possibility of his recovering his vision. In a letter received from him, February, 1906, the patient reports that he is feeling very well, has had no bad spells, and is now in attendance at a school in Pittsburg, Pa.

CASE 7.—Tumor of the left lateral lobe of the cerebellum. Decompressive operation, followed by striking improvement.

*History.* Inasmuch as this case was reported in full,<sup>1</sup> it will be necessary to refer here only to the salient points.

*Patient.* F. M., aged ten years, was referred to Dr. Frazier's service at the University Hospital by Dr. D. J. McCarthy, March 7, 1904. The essential symptoms in the case were a gradual increase in ataxia and pronounced headache, vertigo, and vomiting. There was a marked degree of choked disk on both sides.

*Operation.* March 13, 1904. Dr. Frazier removed the bone overlying the left lobe of the cerebellum and proceeded to explore the hemisphere for a tumor. Exploration failed to reveal the presence of a tumor and before closing the dura, one-third of the cerebellar hemi-

<sup>1</sup> See Dr. Mills' paper "The Diagnosis of Tumors of the Cerebellum and Cerebellopontile Angle, especially with Reference to Their Surgical Removal," New York and Phila. Med. Jour., February 11 and 18, 1905, pp. 91-96.

sphere was removed. The effects of the operation were most gratifying. At his discharge from the hospital on March 27th, his condition was noted as greatly improved. His whole disposition had changed; he was bright and cheerful and complained neither of headache nor vomiting.

*Second Operation.* November, 1904, the patient returned to the hospital because of the recurrence of some of his symptoms. On the following day the cerebellar fossa on the affected side was explored and an infiltrating tumor about the size of a walnut was found and removed.

The value of the palliative operation in those cases in which the tumor cannot be localized is well illustrated by this case. Between the date of the palliative operation and the time at which the tumor was finally found and removed the patient had been comparatively free from any subjective disturbance.

CASE 8.—Suspected tumor of the cerebellum. Decompressive operation including removal of a portion of one cerebellar hemisphere, followed by considerable relief as to the vision, headache, vomiting, and vertigo. Death of the patient seven months later. No autopsy.

*Patient.* P. K., aged fifteen years, entered the neurological wards of the University Hospital in the service of Dr. William G. Spiller, May 9, 1905.

*History.* Eight months ago the patient complained of headache all over the head associated with vomiting. The attacks of vomiting were irregular, sometimes twice a day and again not oftener than twice a week; in the interval, however, he was occasionally nauseated. He complained for some time also of dizziness and difficulty in locomotion. He had never had any convulsions.

*Examination.* Dr. Spiller, May 12, 1905. Conjunctival reflex is distinctly impaired on the left side; corneal reflex normal, both cornea and conjunctiva are normal on right side. Movements of the face are normal on both sides and there is no involvement of motor or sensory root of the fifth nerve. Sensation for touch and pain is not impaired. Movements of the eyeballs in all directions are somewhat impaired, and somewhat inco-ordinate. Tongue is protruded straight, there is no atrophy and there are no fibrillary tremors. Hearing for the voice appears to be normal in each ear, speech and intelligence normal. When sitting up the patient holds his head fairly erect, possibly with a little tendency to incline it to the left.

The grasp of each hand is normal, finger to-nose test normal on each side. Neither biceps tendon reflex, triceps tendon reflex, nor the wrist reflexes are distinct on either side. Sensation for both touch and pain normal in both upper extremities. There is no wasting in the upper extremities.

In the lower extremities the voluntary movements are normal, and there is good resistance to massive movements. The patellar reflex is very prompt, even exaggerated on the right side, but not

quite so prompt on the left side. There is no ankle clonus. The Achilles jerk on the right side is prompt, but not so prompt on the left side. There is no Babinski reflex on either side, the smaller toes being drawn downward, the great toes remaining still. Sensation for touch and pain is normal in each lower extremity, the cremasteric reflex is exceedingly prompt on the right side and prompt, but not so markedly on the left. The musculature of the lower limbs is poorly developed, the patient has some difficulty in standing. On standing with his feet close together, even with his eyes open, he usually falls to the left and backward. His gait is very ataxic with a marked tendency to go backward, and to the left. Hemiasynergy is not present on either side.

Provisional diagnosis, cerebellar tumor, more likely on the left side because of the tendency to hold the head to the left, to fall to the left and backward and because of the impairment of the left conjunctival reflex, and of the less degree of exaggeration of tendon reflexes on the left side.

*May 12th, 1905.* Ophthalmic report by Dr. Shumway. Completely blind in the right eye, left vision about 1/100. Both pupils are widely dilated. The right pupil does not respond to light and the left responds sluggishly. There is some limitation of the movements of the eyes, particularly of inward movement, the left eye not approaching within 5 mm. of the inner angle; the movements are very jerky in character. There is a high-grade optic neuritis of the right eye which is going into secondary atrophy of the nerve. The veins are very tortuous and there is a small hemorrhage on the outer side of the nerve and an elevation of 6 D. In the left eye there is also an optic neuritis and of a milder degree with an elevation of about 4 D. The left nerve is also becoming atrophic. The patient was referred to the surgical wards.

*Operation. May 17, 1905.* Under ether anæsthesia, Dr. Frazier performed a decompressive operation. The exposure of the left cerebellar hemisphere was attended with unusually free hemorrhage particularly from those sinuses which have been described on previous occasions as existing in the occipital bone in the neighborhood of the occipital protuberance. When the dura was opened the cerebellar tissue bulged considerably but on the surface of the hemisphere and to a depth of about one inch, no pathologic condition could be demonstrated. About one-third of the hemisphere was removed and the cerebellopontile angle exposed but with negative results. A very good exposure of the seventh and eighth nerves was obtained, and they were demonstrated to the eight or nine physicians who were witnessing the operation. No further exploration was made and the wound was closed.

*Subsequent History.* The patient reacted from the effects of the operation. Dr. Shumway reports that the optic neuritis had subsided very much, the apex of the swelling in the right eye is now only 3



D. as compared with the 6 D. before the operation, and the left eye 2 D. as compared with 4 D. before the operation. The nerves are becoming somewhat atrophied. The patient's vision has improved particularly in the left eye, so that he can count figures at a distance of two feet.

*July 19th.* Reported to-day that the patient can walk around the ward without any assistance, although still somewhat unsteady, but, however, no tendency to fall in any particular direction. He has now no headache, and his vision has been so improved that he is able to distinguish faces and objects.

No opportunity was afforded to make any observations after the patient was discharged from the hospital, and in answer to a letter of inquiry written in January, 1906, we learned that the patient had died December 24, 1905.

CASE 9.—Suspected tumor of the cerebellum in which a decompressive operation entirely relieved the subjective symptoms.

*History.* S. L., aged twenty years, patient of Dr. T. H. Weisenburg and Dr. M. Radcliffe, was admitted to the University Hospital, Oct. 25, 1905, with the following history:

*Family History.* Father died of pneumonia. Mother is living and well. Two sisters and six brothers all in good health. No history of nervous disorders, tuberculosis, renal disease, cardiac disease or neoplasm.

*Social History.* Patient was born in Austria and came to this country when three years of age. Engineer by occupation. Uses alcohol and tobacco in moderation. Patient has a small urethral discharge at the present time of one month's duration. There is no syphilis.

*Previous Medical History.* Patient had measles during infancy; otherwise he has always been in excellent health. He was well until one year ago, when he began to experience nausea, followed by vomiting, with pain of a severe character, starting in the nape of the neck and shooting upward to the top of the head. At first these attacks were rather frequent, occurring every day or every other day, but they have greatly decreased in frequency. Two months ago the sight in the left eye began to fail and now he can distinguish only shadow and light. At about the same time he noticed that he was deaf in the left ear. On attempting to walk he feels giddy and staggers. This began about three or four months ago and has not increased much since then. Turning the head from side to side and backward causes some pain, but not severe. Lifting causes severe pain with blurring of vision. No motor paralysis.

*Examination,* by Dr. Weisenburg. Station with eyes open and shut good. Gait with eyes closed, good, though occasionally he has tendency to walk either to right or left.

*Eyes.* Pupils dilated with atropin. Convergence impossible with left eye, *i. e.*, on attempting to look at nose, the left internal rectus is

weakened. Associated ocular movements to right and left are perhaps affected; *i. e.*, he can look either to right or left to the normal extent, but in a short time the eyeballs have a tendency to jerk back toward the median line. Upward and downward associated movements are normal. No diplopia. Ophthalmoscopic examination shows marked choked disk on both sides, especially the left. Both optic nerves are much swollen and hemorrhages are profuse. The appearance is that of an albuminuric retinitis.

The fifth, the seventh, and the twelfth nerves are normal. Hearing seems to be diminished on the left side. There is no trouble in eating; no dysphagia; no dysphonia. Memory is good. Both upper and lower limbs are normal in form. Reflexes and sensation are normal. There is no ataxia on either side. No involvement of bladder or rectum. No hemiasynergy. Touching conjunctiva on either side does not elicit any movement of eyeball while corneal reflex is present. There is no Babinski. The results of the examination of the nose, throat, and larynx by Dr. Grayson and of the sense of hearing by Dr. Randall were entirely negative.

*Operation.* Oct. 26, 1905. A decompressive operation was performed by Dr. Frazier, which consisted in a suboccipital craniectomy, the bone overlying the left cerebellar hemisphere was removed. There appeared to be an increased amount of intracranial tension and the dura did not present its normal pale, bluish color, but in most places and particularly in the upper and inner angle, it was yellowish, opaque and dotted here and there with whitish-yellowish specks. The dura was not incised.

The operative recovery was entirely uncomplicated. The wound healed throughout *per primam*.

31st. Dr. de Schweinitz made an ophthalmic examination and reported a right choked disk, plus 10 to 11 D.; left choked disk, plus 9 D. and no fresh hemorrhages.

November 3d. Dr. de Schweinitz reports O. D. choked disk, plus 11 D., some fresh hemorrhages. Vision 6/22. O. S. choked disk, plus 9 to 10 D., but more contracted laterally; fresh hemorrhages.

December 22d. Dr. de Schweinitz reported as follows: O. D. 6/12 subsiding neuritis, plus 7 D. O. S., subsiding neuritis, plus 7 D. It will thus be seen that choked disks have subsided about 4 diopters since the operation.

December 23d. The patient was discharged from the hospital to-day. Since the operation his vision has improved considerably.

January 29, 1906. Patient reported at the hospital for examination and said that there had been no headache, nausea, or vomiting. O. D. the disk can be distinctly seen, slight swelling of the edges, only about plus 1 D. O. S. disk apparently normal. This is one of the most striking effects on choked disk after decompressive operations that we have observed and is particularly interesting in that the results were obtained without opening the dura.

*May 29th.* The patient now has some headache, but much less than he had before the operation. He is occasionally dizzy. The patellar reflexes are a little increased. Gait and station are good even with eyes closed. Dr. de Schweinitz reports: Subsiding optic neuritis. R. E., marked loss of capillarity, especially temporal half disk swollen, 5 D. (eyeground 3 D.), hence actual elevation 2 D.; vessels shrinking; some exudate in macula. L. E., well-marked subsiding neuritis and postpapillitic atrophy.

CASE 10.—Tumor of motor region.

*History.* P. S., aged twenty-five years, was referred to Dr. Spiller by Dr. de Schweinitz.

*Family History.* Father and mother living and well. No history of neoplasm, tuberculosis, liver or kidney disease. Cousin became insane and committed suicide. Mother says the whole family is very nervous.

*Social History.* Went to school until eighteen years of age, then studied law for three years, but was forced to give it up on account of his nervous condition, then became a fireman on a locomotive. Smokes to excess; drinks alcohol in moderation.

Note from Dr. de Schweinitz: "Double optic neuritis (choked disk), visual fields normal. No palsy of exterior muscles. Choked disk about 5 diopters."

Up to eight years of age had almost every infectious disease. When eleven years old he went to bed well one night and awoke blind and remained so for four months (treated at St. Agnes' Hospital). Sight gradually returned. According to his mother, "eyeballs were solid red, like clotted blood." Until seventeen years of age, he had fair sight and did not wear glasses. At seventeen, he began to be very nervous, and it was then that he began to take "weak spells." About once a month he would suddenly become weak, his knees would give way and he would fall to the ground, but would not lose consciousness. These fainting spells disappeared after a while and have not been present since he was eighteen years of age.

At twenty-one years of age he again wore glasses. His sight gradually diminished and he suffered severe pain in his eyes, especially behind the eyes. Temporary attacks of blindness, lasting a minute or a few seconds, occurred sometimes. He has always been a heavy smoker since he was seven or eight years old. He has averaged twenty to twenty-five cigarettes daily and also a pipe and a cigar a day. He had gonorrhoea three years ago, but has not had a chancre or other venereal sore. He has been always subject to headaches, but within the past year, pain has been almost constant, worse at night, preventing sleep, and associated with attacks of vertigo, weakness, nausea, and vomiting. The headache is chiefly in the vertex, but sometimes occipital and above the eyes. He had a severe fall and struck on the back of his head when a child. Weakness disappears at will; if he "were to give in to it he would go in a heap." He has

never had convulsions, but says that several times he has had attacks in which the whole left side, arm and leg, especially the leg, became numb, "as though dead;" the arm was only a little affected. He has no paralysis or paresis anywhere. He was a fireman on a locomotive three years and was so nervous that he gave up the work. Every little noise would make him jump, and he was always expecting something to happen, "lost his nerve," as he expressed it. Masturbated freely before sixteen years of age.

*Examination.* Sensation seems normal everywhere and to every form of stimulation, and there is no astereognosis and no loss of muscle sense. Ocular movements are good. Slight nystagmoid movement is seen on extreme lateral excursion, especially to the left. Reflexes are normal. There is no Babinski and no ankle clonus.

Cardiac condition: Irregular heart action without marked accentuation of either aortic or pulmonic sounds.

Patient states that the attacks of stiffness of left lower limb previously mentioned are usually preceded by much greater headache, a "sensation of something inside expanding and bursting out." They frequently occur at night and in them the left leg becomes very rigid and is drawn across the right, but it can be voluntarily moved. The left arm is to a less extent involved and still less the left face. During the attack, consciousness persists, but the whole left side feels as though "dead." He has almost constantly a blowing tinnitus aurium; only on the right side. He quit railroading in November, 1905, and since then has had only one or two attacks of spasm; previously had one or two weekly.

*March 20, 1906.* Yesterday morning, in getting out of bed he had headache. Between 10 and 12 o'clock he became weak in his knees, but did not fall. In the afternoon he vomited and complained of intense headache and became unconscious. The left arm was flexed on the forearm and was stiff. The left lower limb was stiff and probably the left side of the face was affected. He was unconscious all night and very noisy and hard to restrain. This morning he is perfectly conscious, but in an agony of headache, crying out at times and tossing about in bed, clutching at any one near him and begging for relief. There is no motor weakness in any of the limbs, but he has some slight disturbance of sensation in the right hand. Stereognostic perception, the sense of position and tactile sensation are normal in each hand. The spasms which he has had have been in the left side and have always been tonic (never clonic). The patellar reflex is exaggerated on the left side and possibly slightly so on the right. Achilles tendon reflex is not exaggerated and there is no Babinski reflex.

*Operation by Dr. Frazier. March 20 1906.* Under ether anæsthesia the usual motor opening was made, the flap measuring  $3\frac{1}{2} \times 4$  inches in width and length. When the osteoplastic flap was reflected it was noticed that at a point about  $2\frac{1}{2}$  inches from the front of the posterior

margin of the opening and just below the superior opening the dura had already been punctured by the neoplasm, and immediately overlying this point the bone had been almost entirely worn away by the tumor. There was no visible nor palpable pulsation. The exposed dura was of a greenish hue and gave the appearance as though there were beneath it numerous large vascular channels. There was a peculiar soft fluctuating sensation communicated to the examining hand. An exploratory incision was made in the dura, beginning at the point where it had ruptured spontaneously. A tumor was immediately exposed, apparently of the infiltrating character and filled with large vessels. Its removal was considered impracticable. The dural incision was closed and the lower half of the bone contained in the flap as well as a considerable portion of the temporal bone were removed. The wound was closed as usual with interrupted silkworm-gut sutures and the drainage introduced through two counter openings.

21st. The headache, of which he complained so bitterly before the operation, has entirely disappeared. Patient can move his left leg, but has no movement in his left arm, forearm, or fingers. Sensation is not impaired. There is some impairment of the left facial nerve.

22d. The movements of the left lower limb are still unimpaired. The left upper limb is completely paralyzed, as is also the lower part of the left side of the face, the muscles supplied by the superior branch of the facial nerve being weak. The tongue deviates a little to the left when protruded. The left biceps and triceps reflexes are not distinct; the left patellar reflex is exaggerated. There is no ankle clonus on the left side.

*Subsequent History. March 23d.* Drainage removed to-day and wound in excellent condition.

25th. Dr. de Schweinitz reports that in the right eye there is optic neuritis, a greenish-white swelling confined to the disk and covered with numerous particles, probably cholesterin. There are no hemorrhages. Swelling of the disk is plus 3 D. In the left eye the conditions are precisely similar; swelling of disk, plus 4 D. Vision O. D. 4/25, O. S. 4/12.

26th. Patient's general condition is excellent. The dressing has been removed and he is up and about the ward.

27th. For the first time the patient can lift the left arm and raise his hand over his head without any difficulty; he can flex his fingers.

30th. Patient still has some weakness in the lower side of the face, the left upper arm is still weak, although power is gradually returning. Tactile sensation, sense of position, stereognostic conception are normal in the left hand. He is able to walk unaided.

*April 1st.* Dr. de Schweinitz reports, under date of to-day, optic neuritis in right eye plus 3 D., in left eye, plus 4 D. O. D. V. equals 4/20 (?), O. S. equals 4/10 (?). Vision is very much blurred. Evidence of temporary blindness.

*April 4th.* The patient was discharged from the hospital to-day, having had absolutely no recurrence of headache.

CASE 11.—Tumor of cerebellum.

*History.* E. F., aged sixteen years, was referred to Dr. Spiller, July 16, 1904, by Dr. J. S. Baer and Dr. R. G. Curtin. The father of the patient possibly had had syphilis. The menses ceased about two years ago; having begun when she was fourteen years of age, they had, therefore, been present only a short time. For about one year she had had a severe sensation of pressure at the back of the head, as though someone were pressing her brain out, but this sensation is not felt now. She has had headache, not localized to any one part of the head, and has had "neuralgia" in the left side of the forehead about a year. Before December, 1903, the headache was severe. About a year ago she began to have nausea and vomiting, at first about every six weeks, but these symptoms gradually became more frequent until they occurred every two or three days. The vomiting had no relation to eating. About a year ago she began to be dizzy, but has not been dizzy since February, 1904. Dr. Risley has recently discovered optic atrophy, secondary to choked disks. She has never been unconscious. She has had difficulty in lying on her right side, but this sign seems to have disappeared. Lying on the right side caused her head "to kind of draw." She has never had convulsions. Sight has been failing about two years. Difficulty in walking was noticed about November 1903; she staggered, and the straggling seemed to be more to the left.

*Present Condition, July 16, 1904.* There is no involvement of either seventh nerve; masseter contracts well on each side, tongue protrudes straight, not atrophied and shows no fibrillary tremors. Movements of eyeballs are free in all directions, but distinct nystagmus is observed in turning the eyes far to the left or right, and probably is more intense in turning the eyes to the right. The right pupil may be a trifle larger than the left. The reaction of the pupil to light is preserved, also in convergence. Accommodation cannot be tested because of poor sight. She can count fingers with either eye, but the sight is more impaired in the left eye. She hears a low-ticking watch one or two feet from either ear, and has not noticed any deafness. She has had buzzing in both ears, especially in the left, but Dr. Baer states that she has had accumulations of wax in the ears. The face is somewhat puffy and expressionless. The exit points of both fifth nerves are sensitive, but the left supraorbital foramen is more sensitive than the right. She now holds her head straight, but says she formerly inclined her head to the left. Sensations of touch and pain are normal in each side of the face.

*Upper Limbs.* All the movements are free; the grasp of each hand is normal. The biceps and triceps reflexes are not distinct on either side. Sensations of touch and pain are normal in each upper limb. The finger-to-nose test with eyes closed does not show distinct ataxia.

*Lower Limbs.* Voluntary power is normal. The patellar reflex may be a little prompter than normal on each side. She staggers a little when standing erect with eyes closed, and the gait is uncertain, with a tendency to stagger more to the left. The gait is cerebellar in type, but the staggering is not intense. The Achilles jerk is not distinct on either side, nor is the Babinski reflex. Sensations of touch and pain are normal in the lower limbs.

Dr. W. H. Powell first examined the eyes in November, 1903. Vision of the right eye, 20/50; of the left eye, 20/50. Pupils react to light and accommodation. Peripheral vision normal; media clear, but fundus suggests a low grade of neuritis. In July, 1904, vision of the right eye was 20/100, of left eye 4/200, and she had optic atrophy and markedly contracted fields.

Chiefly because of the history of probable syphilis in the father, Dr. Spiller employed mercury and iodide, and by Aug. 16, 1904, her gait had become less ataxic. By May 5, 1905, headache had disappeared, but about once a month she still had a drawing sensation, as though the brain were being pulled out. Ataxia was slight. The patellar reflexes were about normal.

*February 22, 1906.* Dr. de Schweinitz found typical postpapillitic atrophy.

*Operation. March 9, 1906.* Suboccipital craniectomy was performed by Dr. Frazier under ether anæsthesia. The operation consisted in removing that portion of the occipital bone overlying the left cerebellar hemisphere.

*Subsequent History. March 28, 1906.* Since the operation was performed the condition of the patient has improved, but only to a moderate degree. The pain referred to the arms has been very much less severe and at times she has had none at all. Her headaches also have been less severe and less frequent. Although confined to bed for the past year, she is now able to get up in a wheel chair. Although the dura was neither incised nor removed at the operation, there is quite marked bulging over the left cerebellar hemisphere, showing that the dura has yielded to the pressure from within and that it is possible for a hernia to develop without opening the dura.

*Second Operation. April 4, 1906.* After consultation with Dr. Spiller it was decided that, owing to the fact that the headache and pain in the arms had not been entirely relieved, it would be advisable and afford greater relief to the increased tension to split the dura. Following an injection of  $\frac{1}{2}$  gr. of morphine, and under ether anæsthesia, the left cerebellar hemisphere was exposed by a muscle-splitting operation. A vertical incision was made through the middle of the original flap, the edges of the wound retracted and a crucial incision made in the dura about one and one-half inches in either direction. The cerebellar tissue bulged considerably through the opening, but the exposed tissue was normal in appearance. The musculo-aponeurotic layers of the wound were closed with catgut sutures and the scalp with interrupted silkworm-gut suture.

*April 16th.* The following notes were made by Dr. Spiller: The paralysis in the lower distribution of the right facial nerve supply is distinct, although the upper distribution of the nerve does not seem to be affected. She has slight weakness of the right upper and lower limbs. The patellar reflex is prompt on each side, but prompter on the right, and there is slight tendency to ankle clonus on the right side. The Babinski sign is present on the right side, but uncertain on the left side. There is no disturbance of sensation for touch or pain in any part of the body.

*May 23d.* For the first few weeks after the second operation the patient had occasional headaches and pain in the upper extremities. For the past two weeks, however, she has been almost entirely free from both these symptoms. She has gained in strength and is able to be up a considerable portion of the day. A hernia cerebelli has increased somewhat since the second operation (Fig. 4). She has recovered sufficiently from the effects of the operation and is sufficiently relieved to warrant her being discharged from the hospital. Her gait is still ataxic. She menstruated in May, 1906, the first time within a period of four years.

CASE 12.—Cerebellopontile tumor. Decompressive operation, followed by disappearance of headache, vomiting, and by subsidence of choked disk.

*History.* E. D., aged twenty-four years, was referred to Dr. Frazier by Dr. Sherman Voorhees, of Elmira, N. Y. She was seen in consultation also by Dr. Spiller. About two years ago the patient noticed that her limbs were weak, that she would stagger in walking, although she did not feel dizzy. About one year ago she began to notice that her vision was failing. At this time she would have attacks, when for a few minutes everything before her would seem black; following the attacks she could see perfectly well again. At the same time she began to have attacks of nausea and vomiting, and noticed that she was becoming slightly deaf in her right ear. For the past three months she has had considerable headache, sometimes dull, at others, sharp and shooting in character. At the time of her admission, Feb. 16, 1905, she is practically blind and unable to walk.

*Examination, February 17th.* It was noticed that in showing her teeth, the right corner of the mouth is not drawn up nearly so well as the left, and in drawing up each corner separately, the movements on the right side are distinctly less than the left. On closing her eyelids forcibly the resistance to passive movements is less on the left side than on the right side; the masseter muscle seems to contract equally well on one side as on the other. The ocular movements are normal and there is no distinct nystagmus. There is no disturbance of pain and tactile sensation in the face, although she complains of a "queer" feeling on the right side of the face and right side of the mouth and of the face feeling numb, as though it were asleep. Further examination gives the impression that both the left temporal and mas-



seter muscles contract a little more than the right, although it was subsequently found that on both sides the muscles respond equally

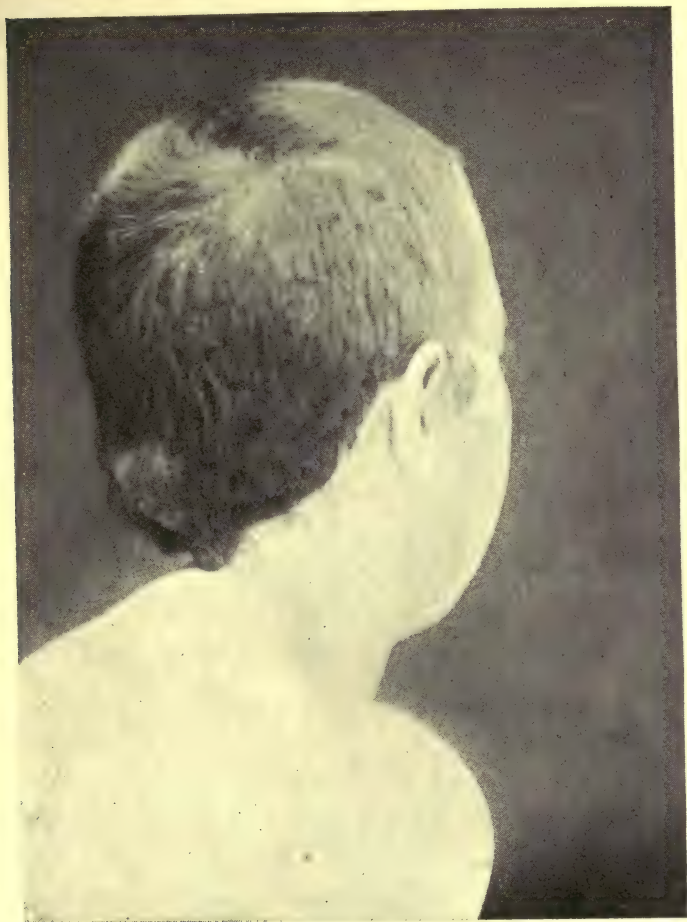


FIG. 4.—Showing a hernia cerebelli after a unilateral suboccipital craniectomy. The patient prior to the operation had been bedridden for over a year, is now able to be up and about and has been relieved almost entirely of her pressure symptoms.

well to Faradic current. The tongue is protruded straight and there are no fibrillary tremors. The right eyelid seems to be slightly more prominent than the left.

In the upper extremities the grasp of each hand is normal. Biceps reflex is normal on each side; the triceps reflex and wrist reflexes are not distinct on either side; sensations for touch and pain are normal on both sides. There is slight ataxia on each side, a little more on the right.

In the lower extremities the patellar reflex is a little prompter than normal on both sides. There is no ankle clonus. The Babinski sign is uncertain on each side, as she resents any attempt to irritate the sole of the foot. The Achilles jerk is absent on both sides; there is no hemiasynergy and no weakness of any of the limbs; gait is slightly ataxic, specially noticeable when she turns; in walking the patient staggers more to the left than to the right. She staggers when her feet are together almost as much when her eyes are open as when they are closed.

*Examination of Ear.* Dr. Randall finds little hearing in the right ear by air or bone, except for the Galton whistle. Tests are slightly contradictory, but indicate middle ear trouble on the right side, complicating semi-complete right acoustic paresis. Hearing on the left side is not impaired.

*Ophthalmic Examination by Dr. Shumway.* Pupils are dilated; right pupil responds when light is thrown in from the temporal side, in which position it is recognized. The left pupil does not respond to light and the eye is blind. There is choked disk on both sides; elevation on the right side is about 6 D. and on the left 7 D. The nerves are beginning to atrophy. The eye movements are carried out in a jerky manner, the muscles acting feebly, and the eyeballs return to primary position immediately. There is no paralysis of the ocular muscles.

*Operation. February 23d.* Under ether anæsthesia Dr. Frazier performed a suboccipital craniectomy, removing the bone overlying the right cerebellar hemisphere. Owing to the fact that bleeding was so profuse, it was decided to discontinue the operation at this stage until the patient had fully recovered from its effects.

A radical operation was performed two months later and was followed by death within five days (Figs. 5 and 6). After the decompressive operation the choked disk subsided from 7 D. to 3 D., although unfortunately, the optic atrophy was so advanced that it precluded the possibility of restoring the vision. The hearing improved somewhat after the operation and the nausea and vomiting ceased. Headaches disappeared almost entirely and the patient was able to get up and walk about the ward with but little assistance.

CASE 13.—Inoperable tumor of brain. Decompressive operation, followed by little or no amelioration of the symptoms, although prolonging the patient's life.

*Patient.* R. C., aged thirty years, was referred to Dr. Charles H. Frazier by Drs. Thomas O. Nock and Wharton Sinkler, March 15, 1906, the latter having seen the case in consultation.

*History.* There was a history of the patient having had an attack of vertigo while walking about three months ago, and had she not been caught by her husband, she would have fallen to the ground. At the same time she had some numbness in the left upper and lower limbs. Since that time she has had two attacks of numbness of the limbs, but no vertigo. She has had more or less persistent headache for the past year, occurring about three or four times a week, usually in the mornings. There have been no convulsions. Three weeks ago the symptoms became much more severe, headache more intense and numbness in the left extremities more marked. At this time it was noticed that the muscles of the left side of the face were gradually becoming weak, the muscles becoming paralyzed within a period of from four to five days. Up to this time there was no weakness in the

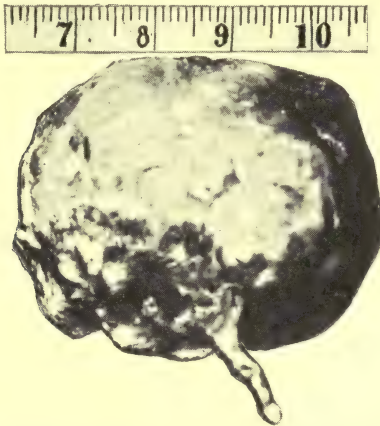


FIG. 5.—Photograph of fibroma removed at operation from the cerebellopontile angle.

extremities, but about a week after the involvement of the facial muscles was noticed the grasp of the left hand became weak, and about the same time weakness was noticed in the left lower limb. The upper extremity sometimes is flaccid, at other times spastic, but the lower extremity has never been spastic. The pulse has varied between 44 and 60. The respirations have been alternately shallow and moderately full, the respiratory rate ranging from 16 to 30 a minute. For the past four or five days her temperature has been subnormal. About eight days ago, for the first time, the patient became stuporous for variable periods of time. These periods of stupor have gradually increased, and during the past two days the patient has been almost comatose. This condition of mental hebetude was first noticed about two weeks ago.

*Examination, March 15, 1906, by Drs. Nock, Sinkler, Frazier and Spiller.* Stupor is so great that the patient can be roused but slightly. She lies in bed with her head turned to the right, but there is no deviation of the eyeballs. There is no tenderness on percussion of the scalp. She is able to move the eyeballs well to the right, although there

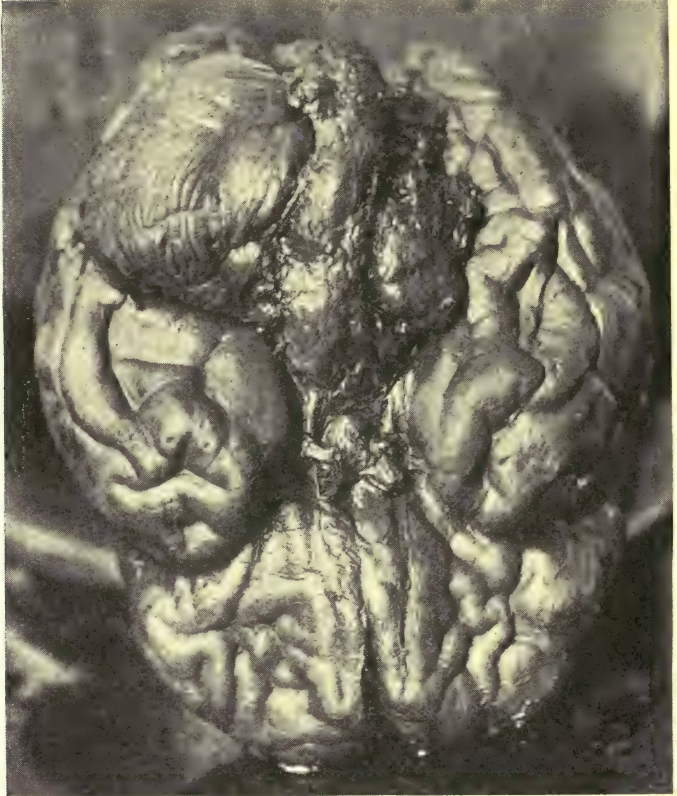

FIG. 6.—Photograph of brain showing portion of tumor remaining in the cerebellopontile angle after operation.

may be slight impairment of the left eyeball to the right, but probably not of the right eyeball to the left. The right pupil is larger than the left. Neither pupil reacts to light. It is impossible to tell whether there is any deviation of the tongue or to test the muscles of mastication.

*Left Upper Extremity.* The left extremity is very weak, although she has a little voluntary power in it and can flex the limb feebly

at the elbow. She cannot make a fist with the left hand. The biceps tendon and triceps tendon reflexes are present, but weak. Sensation is not disturbed.

*Left Lower Extremity.* The lower extremity is very weak, although she can move it slightly. The patellar reflex is present on the left side, but not very prompt. The Achilles tendon reflex is present on each side and about normal. There is no ankle clonus and the Babinski sign is very typical on the left side, as it is on the right, although not so pronounced. Pin-prick is perceived in the left lower limb.

*Examination of the Blood.* Systolic pressure, 165; hæmoglobin 65 per cent.; white blood corpuscles, 21,240.

*Urinalysis.* There is slight albuminuria, no sugar and a few granular casts.

*Ophthalmic Record by Dr. de Schweinitz.* This examination was made a week or more before the patient came to the hospital and disclosed a moderate optic neuritis of each eye, most marked on the right side. There are a few hemorrhages in the neighborhood of the optic disk. The neuritis appears to be in an early stage of its development; on the left side it is just beginning. The pupil reacts normally. There appears to be a divergent strabismus, usually more marked on the right side and probably dependent on paresis of the right internal rectus. Some examinations appear to indicate that there was failure in the movement of the eyeball upward, therefore some involvement of the right superior rectus. This was not certainly determined, as there did not appear to be much difference between the two sides; both lids droop to about an equal extent, but the droop is one probably due to weakness and not to paresis. The visual field, roughly taken by the hand, appeared to be undivided; at least there was no hemianopsia.

*Operation. March 15, 1906.* The date the patient was admitted to the hospital an osteoplastic operation was performed, in which the motor region was exposed. It was noticed when the flap was reflected that there was some bulging of the dura at the lower and posterior angle of the opening. An exploratory incision about one and one-half inches long was made at this point, at which the dura seemed very much thinner, as though undergoing atrophy from pressure. The brain contents bulged through the opening thus made, and an exploratory cannula was introduced for about one and one-half inches, as there was some reason for suspecting the presence of an abscess. It seemed as though the cannula entered a cavity; at first some brownish fluid flowed from the cannula and afterward pure blood. The exploratory incision was made about one-half inch behind the anterior margin of the opening and a small section of tissue removed for examination. Concluding the lesion was a subcortical one; we decided to discontinue any further exploration. A considerable portion of the bone in the flap was removed and the dural incisions and the incisions in the scalp closed.

From the date of the operation until the time the patient left the

hospital, ten days later, the patient manifested but little, if any, improvement as a result of the operation. There were times when she seemed to be a good deal brighter than she had been in the immediate past, and also times when she had a little more movement in the left upper extremity. Mental condition, on the whole, was better, but apart from this there was very little, if any, change. It might be noted that the leukocytosis, which existed before the operation, continued

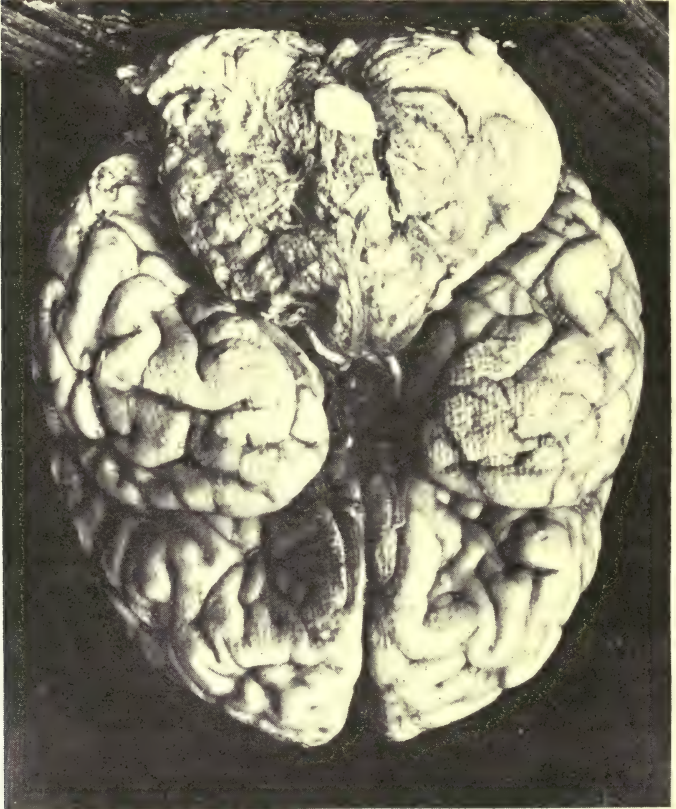


FIG. 7.—Tumor of the cerebellopontile angle.

afterward, and at one time the white blood corpuscles numbered 36,000. In a differential count that was made March 25, 1906, there were 94 per cent. of polymorphonuclear cells. The persistent leukocytosis in the absence of any wound infection was strongly suggestive of the presence of an abscess.

*Postoperative History.* May 24, 1906. A letter recently received from the patient's physician, Dr. Nock, says that her present condition

is about the same. There is complete paralysis in the left upper and lower extremities and now gradual weakening of the muscular power in the right arm and leg. When awake the patient talks intelligently and is interested in what is going on, although there is a tendency toward confusion of ideas at times. Her appetite is good and she takes enough food to maintain her nutrition. Her temperature varies from 99 to 99.3. Pulse is regular.

We include the following case, which was in the service of Dr. Mills and Dr. Martin and was studied also by us:

CASE 14.—Stafford, male, aged forty-six years, was under the care of Dr. C. K. Mills in the University Hospital, in 1902. He was seen also by Dr. Potts and Dr. Spiller

The patellar reflexes and Achilles tendon reflexes were lost; the gait was ataxic. Headache, dizziness, optic neuritis, nystagmus and paræsthesia of the left side of the face were present among other symptoms. The diagnosis of cerebellar tumor was made. A palliative operation over the cerebellum was performed by Dr. Edward Martin in 1902. The patient's condition was much improved. He died in 1906 and a tumor was found in the left cerebellopontile angle (Fig. 7).





## THE OCULAR SYMPTOMS OF TUMOR OF THE CEREBRUM.

BY G. E. DE SCHWEINITZ, M.D.,  
*Professor of Ophthalmology in the University of  
Pennsylvania.*

---

THE ocular signs of tumor of the cerebrum are chiefly concerned with changes in the fundus oculi, particularly the nerve-head, and in less important degree with anomalies of the visual field, the pupillary reflexes, the external ocular muscles and the movements of the eyeballs. The present paper is concerned only with papillitis or choked disk, and a brief reference to the visual field phenomena.

### PAPILLITIS OR CHOKED DISK.

(a) FREQUENCY. It is a well-established fact that papillitis or choked disk is, headache excepted, the most common general symptom of tumor of the brain. It is, however, not possible to obtain accurate statistics as to its frequency, because, as has been well pointed out by Bruns and other observers, the available material represents examinations of the eye-ground at different stages. Therefore, absence of intraocular optic neuritis at one examination does not exclude its presence at a subsequent one.

According to John E. Weeks,<sup>1</sup> an average of the frequency of optic neuritis in brain tumor, as recorded by Oppenheim,

---

<sup>1</sup> Transactions of the Section of Ophthalmology, American Medical Association, 1899, p. 322.

Gowers, C. P. Knapp, Dana, Bernhardt, Martin and Bramwell, is 78.2 per cent., although higher percentages are found in individual series, for example: Oppenheim 82 per cent., Annuske and Reich 95 per cent., Kampherstein 80 per cent. In my own experience, this symptom has been present in fully 85 per cent. of the cases examined.

Bearing upon this question and upon the relative frequency of papillitis in growths in various parts of the cerebrum, the analysis of the reports of 601 brain tumors by J. M. Martin<sup>1</sup> is important. He found that of the neoplasms in which optic neuritis was present at some time in the course of the disease, those which involved the corpora quadrigemina and the crura gave the highest percentage, namely, 100; next came tumors of the cerebellum and parieto-occipital region, with a percentage of 89; new-growths of the frontal region and those denominated "general" furnished a percentage of 84; following these were tumors of the basal ganglia, with a percentage of 75, of the pons and medulla and of the temporosphenoidal lobes, and "multiple," with a percentage of 68, of the centrum ovale, with a percentage of 67, of the pituitary body, with a percentage of 65, of the motor area, with a percentage of 62, and of the corpus callosum, with a percentage of 46. In his tabular statement of the growths in which optic neuritis was present excluding atrophic cases, those which involved the cerebellum gave the highest percentage, namely, 81; next the corpora quadrigemina, with 79 per cent.; the symptom was least frequently present in tumors of the pons and medulla and of the corpus callosum, viz., 36 and 25 per cent. respectively.

According to Oppenheim,<sup>2</sup> choked disk is relatively often wanting in tumors which proceed from the meninges and compress the brain, and in cortical tumors that do not sink deep into the white matter, while in growths of the pons, of the medulla and of the corpus callosum papillitis fails

<sup>1</sup> The Lancet, ii. 1897, p. 83.

<sup>2</sup> Die Geschwülste des Gehirns, Wien, 1896.

with tolerable frequency, or is late in its development. In so far as the failure of choked disk to appear in tumors of the pons and medulla is concerned, Bruns<sup>1</sup> is in accord with these statements, but he declares that it is apt to be lacking in tumors of the crura and of the corpora quadrigemina, in this respect differing utterly from Martin's statistics. J. M. Martin also draws attention to the comparatively small proportion of cases in which optic neuritis is found in tumors of the corpus callosum and of the pons and medulla, it being absent in nearly two-thirds of the cases.

According to the well-known analysis of Edmunds and Lawford<sup>2</sup> there is a comparative immunity from optic neuritis of the cases of tumor in the cortical motor area. Thus, they added all their cases (107 in number) in which the locality of the tumor was toward the convexity of the brain, that is, for example, in the anterior frontal convolutions, the motor convolutions, the occipital lobes, the hemispheres and the meninges at the motor convolutions, and found that they yielded 50 per cent. of optic neuritis, while those toward the base, that is, in the ganglia at the base, in the temporo-sphenoidal lobes, in the cerebellum, in the medulla and pons, and in the meninges not at the motor convolutions, yielded a percentage of 74 of optic neuritis.

The most recent contribution to this subject is by Kampherstein,<sup>3</sup> who has collected 76 cases of brain tumor with choked disk in which an autopsy was made. The situation of the tumor was as follows: Frontal lobe twelve times, temporal lobe six times, parietal convolution four times, occipital lobe five times, epiphysis twice, third ventricle twice, corpus callosum three times, optic thalamus twice, corpora quadrigemina seven times, hypophysis three times, fourth ventricle once, peduncle of the cerebellum twice, cerebellum twenty-three times.

---

<sup>1</sup> Die Geschwülste des Nervensystems, Berlin, 1897.

<sup>2</sup> Trans. Ophth. Soc. of the United Kingdom, iv. 172.

<sup>3</sup> Klin. Monatsbl. f. Augenheilk., Bd. i., 43, 1905.

(b) DATE OF OCCURRENCE AND CHARACTER OF THE NEURITIS AND NERVE-HEAD CHANGES. As may have been inferred from the previous paragraphs, and as is apparent from the investigations of Oppenheim, Bruns and others, optic neuritis or papillitis, if it does not fail entirely as a symptom of tumor of the pons, of the medulla and of the corpus callosum, is late in its development and this lateness of development is also to a certain extent true of tumors of the frontal lobe and the parietal convolutions. Indeed, papillitis of brain tumor, and by this is meant of the cerebrum and not of the cerebellum (for the latter portion of the intracranial contents is not now under discussion), is not an early symptom if the visual tracts at the base of the brain are excepted.<sup>1</sup>

It is not possible to predict how soon after a tumor arises optic nerve changes will appear. Sometimes the whole process from the beginning of papillitis to the height of its swelling is complete in a few weeks, sometimes several months may elapse. (Bruns.) I have known optic neuritis to be postponed until within a week of the patient's death, although all the symptoms of brain tumor had been present for more than a year. In general terms, however, it may be stated that, with the exceptions already noted, the process must have existed for some time and the increased intracranial tension have lasted for a definite period before either an engorgement œdema of the optic disk or an inflammatory optic neuritis develops.

In a certain number of cases it is possible to watch the development of neuritis from its very earliest stages. The first symptom is increased redness of the disk and obscuration, usually of its upper and lower borders, associated with a certain turgescence and inequality of the venous circulation.

---

<sup>1</sup> It must not be forgotten that the optic neuritis of cerebellar tumor is often an early symptom and develops with great rapidity. The Ocular Symptoms of Cerebellar Tumor, by G. E. de Schweinitz, New York Medical Journal and Philadelphia Medical Journal, Feb. 11 and 18, 1905.

Occasionally the nasal border is earlier and more obscured than the other margins in the form of the so-called hemineuritis. Usually within a week, the obscuration of the nerve edges increases and the temporal border becomes veiled, while a distinct swelling of the nerve-head appears and the darkness and tortuosity of the veins is decidedly more manifest. At this period the difference in level between the top of the swelling papilla and the eye-ground is usually not more than 1.5 or 2 D. Within the next week there is complete loss of the light spot and complete obscuration of the disk, the swelling increases, assumes a mound shape of mixed grayish-red color, and finally the form of the disk is entirely lost and its position can be inferred only by the convergence of the vessels. Not infrequently at this stage, and indeed at an earlier one, linear hemorrhages appear in the immediate neighborhood of the disk or on its swollen surface. The arteries, smaller than normal, pursue a moderately straight course and are difficult of recognition, being partly concealed by the swelling. The veins are dark in color, distended and tortuous, and pass along the slope of the elevation, often dipping into the infiltrated tissue.

The height of the papillitis varies, usually between 3 and 6 diopters. Occasionally it is as high as 8 or 9 diopters, and in a recent case, seen in consultation with Dr. Weisenburg, the swelling of the disk was 9 diopters. Indeed, some of the prominent vessels were still in focus when viewed through a 10 diopter convex lens. This is the highest elevation that I have seen in the choked disk of brain tumor. The exact position of this tumor was not located. It was probably in the cerebellum.

At some periods of optic neuritis, especially in the later stages, there may be very great increase in the number of hemorrhages, both on and in the immediate neighborhood of the disk. Exudates may also appear, white or yellowish-white in color, and white patches develop in and on the swollen disk.

To distinguish a true beginning neuritis or a congestion with œdema from a "spurious optic neuritis," or so-called "hyperopic disk," as it occurs in association with refractive error is often most difficult. There is, however, in the beginning of optic neuritis of brain tumor a certain quality which pseudoneuritis does not possess. The blurring of the disk edges is more complete, and even with the indirect method of examination the obscured margins are with difficulty seen; the surface congestion is more decided and gives rise to a "juicy" impression; the retinal veins, often only one division of them, are darker, more distended and more unevenly tortuous, indeed, decided tortuosity of the retinal veins, especially of one or two of the larger branches, may appear before any obscuration of the disk. At this stage, photometric examinations may give aid in diagnosis.

A swelling of at least 3 D. should exist before the name "choked disk" is permissible, but it is not worth while to enter into a discussion of the various aspects of neuritis or "choked disk." As Hughlings Jackson has said, there is one kind of optic neuritis from intracranial disease which may manifest itself under different appearances, sometimes with and sometimes without "swelling of the disk."

Ophthalmoscopic examination is not always made during the period of typical optic neuritis or choked disk; patients may come after the evidences of inflammation and œdema have begun to subside—at the period, in other words, when the veins grow less distended, new hemorrhages do not appear, previously obscured vessels reappear and the swollen nerve-head begins to be depressed and the grayish-red tint of the prominence becomes more uniformly gray and grows paler. The temporal edge of the disk is first to appear, and gradually the other margins emerge from the obscuration. Finally, all edges of the disks are clear, and the well-known symptoms of *post-papillitic atrophy* are present, quite distinguishable from either a *primary* or a *secondary atrophy* by the presence of the tissue which fills in the centre of the disk and obscures

the lamina cribrosa so prominently visible at the bottom of the shallow cupped, primarily atrophic disks. Both sets of vessels, too, are contracted and streaked with infiltrated perivascular sheaths. Areas of retino-choroiditis and patches of white marking the spots of former hemorrhages are often apparent.

In rare instances a *second attack of optic neuritis* takes place. A good example of this I observed in the Orthopædic Hospital and reported with Dr. A. G. Thomson.<sup>1</sup> In this case the patient was trephined for the relief of the symptoms of a tumor believed to be situated in the right motor area. It was not possible, however, to remove the tumor, although great relief followed the trephining. Three and one-half months after operation the double optic neuritis had subsided and there was post-neuritic atrophy. One year later the patient returned with all the symptoms of brain tumor re-established (from which he had previously been entirely free), totally blind and with double optic neuritis, the apex of each swelling being 6 D., or as high as it had been before the original operation.

As may have been inferred, the tendency of optic neuritis or papillitis is to cause atrophy of the nerve, but optic neuritis may remain stationary for long periods of time and finally disappear without leaving a trace of its presence. Naturally, as Oppenheim points out, such a state of affairs could be expected only if the original disease subsides, or there is relief of intracranial pressure by trephining. Exceptionally, however, as he notes, the original disease continues but the neuritis subsides.

In place of optic neuritis as a sign of brain tumor, *optic nerve atrophy* itself without indications of pre-existing neuritis may appear. This is particularly true in the case of basal tumors, for example of the hypophysis, and depends upon direct compression of the chiasm, the optic nerve tracts

---

<sup>1</sup> Archives of Ophthalmology, xxiv. 1905.

or the optic nerves themselves. It may also be produced by bulging of the lateral ventricles and the pressure thus exerted by them. This is the so-called *secondary atrophy*. The color of the disk is gray and assumes a tint not unlike that of primary or progressive atrophy. More often the color of the disk is whiter than in gray atrophy. Both sets of vessels are contracted. This secondary atrophy must be distinguished from the consecutive or post-papillitic atrophy, to which reference has already been made. I suspect that in a certain number of cases there is a period of congestion of the disks preceding the atrophy, which may or may not have been observed.

In discussing the ocular symptoms of cerebellar tumor,<sup>1</sup> it was stated that the papillitis of intracranial tumor is sometimes unilateral and that where there is a one-sided optic neuritis, or a marked difference between the two sides, it is suggestive of the fact that the cerebrum is the seat of the growth, and on the whole in favor of the tumor being on the same side as the excess of neuritis. J. M. Martin's investigations on this subject are important and show that the seat of the lesion is probably on the side on which the optic neuritis is more marked in the proportion of 71 to 29. Although unilateral optic neuritis, or, more accurately, excess of neuritis on one side, occurs in tumors of the cerebellum, it is a much less common symptom than in the cerebral cases.

(c) **RETINAL CHANGES.** A very interesting appearance is the so-called macular figure, in other words, a lesion simulating that seen in albuminuric retinitis. It is said to be more frequent in cerebellar growths, but has been observed a number of times with tumors having other situations. The most perfect figure of this kind which I have noted occurred with a subcortical tumor in the parieto-occipital region.

In thirty cases of tumor reported by Leslie Paton<sup>2</sup> these

---

<sup>1</sup> Loc. cit.

<sup>2</sup> Transactions Ophthalmological Society of the United Kingdom, xxv. 1905, p. 129.



macular changes were noted five times, one frontal case, one parietal case, two cerebellar cases and one extracerebellar case. Kampherstein found eight times in his two hundred cases of choked disk (one hundred and thirty-four of these were brain tumor cases) involvement of the macula, but only once a typical star figure, such as one sees in retinitis albuminurica. Therefore, the macular involvement is not always a star figure, due probably to œdematous infiltration, and is not necessarily associated with great depreciation of vision, but may be, as in Kampherstein's seven other cases, composed of smaller and larger hemorrhages or irregular white plaques of exudation. Indeed, Bruns refers to these as a not uncommon development in the macula at the height of choked disk, and believes that the appearance there of yellowish-white and fatty degenerated spots intermixed with hemorrhages is of serious import. In a number of cases I have seen these macular exudates quite distinct from star-shaped œdematous areas, both with and without hemorrhages, and have studied them at the height of the choked disk as well as in its later stages, both in cerebellar and in cerebral tumors.

Other retinal changes have already been referred to, particularly areas of atrophy, marking the position of former hemorrhages, sclerotic patches in the retinal vessels, perivasculitis, pigment-heaping, which are in no sense significant of the growth itself but only of other ocular lesions which have accompanied it.

(d) VISUAL ACUTENESS. Optic neuritis or choked disk caused by cerebral growths is perfectly compatible with good acuteness of vision. Indeed, as has many times been pointed out, perfect vision, in so far as test-letter examination is concerned, may exist for long periods of time, although there is well-marked engorgement of the nerve-head, or all of the signs of papillitis. Even where the visual acuteness appears not to be normal, but is reduced, for example, to one-half or one-third, or even one-tenth of normal, it may often be raised nearly or

quite to the normal standard if a suitable glass corrects any co-existing refractive error. A good example of this occurred recently in the University Hospital. A boy with moderate optic neuritis, probably the result of meningitis, following a fracture of the skull, apparently had a vision of only  $\frac{6}{30}$ , but as his eye was hyperopic 4 D. at the macula, this glass promptly raised his vision to  $\frac{6}{9}$ , in spite of the presence of 2 D. of neuritis. In other words, visual acuteness recorded without note of the refractive error and the effect of neutralizing lenses does not give a true indication of the real sharpness of sight.

An interesting fact often mentioned and again referred to by Leslie Paton is the rarity with which one finds optic neuritis or choked disk in eyes that are myopic. This accords exactly with my own experience, and in one notable instance with a myopia of 10 D., although all signs of brain tumor had been prominently present for nearly two years, there was no optic neuritis until ten days before the patient's death, when, preceded by marked venous engorgement, congestion œdema followed by rapid neuritis developed, so that the disks were swollen 2 or 3 D. at the end of that period. A not uninteresting research would be one which included a study of the exact refractive condition at the macula of eyes with optic neuritis associated with brain tumor, and of eyes exhibiting no neuritis, although other signs of cerebral neoplasm are present. It is possible that it might lead to an explanation of the lateness of the development of neuritis in certain cases, as for example in the one just mentioned.

Differences in the visual acuteness of the two eyes is not uncommon. The vision of one eye may be normal, while that of the other may be only one-half or one-third of normal. Usually this difference, if not caused by refractive error, depends upon the degree of the neuritis, or upon post-neuritic changes. A considerable atrophy of the nerve may exist in one eye and no apparent atrophy in the opposite eye, which possesses normal or nearly normal vision.

The relationship between the site of the tumor and the vision is discussed by Leslie Paton<sup>1</sup> in his important communication on optic neuritis in cerebral tumors. Of seven patients with frontal tumor, three retained normal visual acuteness during the whole course of the attack. In one, the sight at one period was reduced to two-sevenths of normal, but subsequently recovered. In three the sight of the eye on the side corresponding to the tumor was defective, while the eye was left in a normal condition on the other side. In ten cases of parietal tumor he records four as having retained good sight, three as having suffered from defective sight during the height of the attack, with subsequent recovery, while in three the sight was entirely lost, with no recovery. These recoveries were the result of the operations which were performed for the relief of the symptoms which the tumor produced, to which reference will be made in a later paragraph. In contrast to this, it may be mentioned that Paton records eleven cerebellar cases, and only one showed no marked loss of sight during the course of the neuritis.

*Temporary amaurosis in brain tumor* is a sign of decided importance. Although the visual acuteness in the presence of choked disk may be entirely normal, or reach close to the normal standard, the patient may have periods of temporary amaurosis which last from a few minutes to a few hours, and, it is said, may continue for several days, to be followed by a restoration of the visual power to that which existed prior to their occurrence. In a patient recently under my observation in Dr. Frazier's wards these amaurotic periods first called the patient's attention to his eyes, and led to their examination and the discovery of papillitis. In this case the periods of obscuration lasted usually from ten to fifteen minutes, according to the patient's statement. Those which I witnessed were not quite so long—five to six minutes.

---

<sup>1</sup> Transactions Ophthalmological Society of the United Kingdom, xxv. 1905, p. 136.

Form-sense was obliterated but light-sense still remained. It would seem that these amaurotic attacks are the result not of the neuritis but of compression of the chiasm by the bulged floor of the third ventricle.

Michel has stated that the amaurosis is related to pressure from the third ventricle, if it appears quickly in both eyes, or rapidly in one eye after the other. The patient before referred to experienced the most marked attacks in the left eye, that is, on the side on which the tumor existed. He declared that occasionally the amaurosis was unilateral; this statement, I did not substantiate by personal observation. There was, however, an appreciable difference in time between the development of the attacks, and the left eye was the first to suffer.

Paton's observations lead him to say that transient attacks of blindness may last for periods varying from a few seconds to half an hour. The symptom was noted twelve times in his series: six of these were cerebellar cases, three frontal, two parietal and one pontine. In another series of cases (thirty-eight) he found this symptom mentioned in four, all cerebellar tumors, and suggests that the condition may be due to interference with the blood supply of the occipital lobe, but because increased headache and attacks of giddiness accompany the symptom there is evident pointing to an increase in intracranial pressure as its most prominent etiological factor.

Mr. Gunn, discussing this matter, maintains that the occurrence of complete temporary loss of sight in one or both eyes under these conditions cannot be explained by a local effect upon the sight-centre. It must be due to sudden increase in intracranial tension and loss of function by pressure exerted on the optic nerve fibres.

Amblyopia and blindness without eye-ground changes have been observed by Curschmann, Gerhardt and others, and have been attributed to the bulging forward of the floor of the third ventricle and pressure upon the chiasm.

(e) **THE EFFECT OF OPERATION ON OPTIC NEURITIS OR PAPHILLITIS.** It is not the purpose of the present paper to discuss in detail the various theories which have been advanced to explain the development of papillitis or choked disk. In general terms it may be stated that a certain number of cases of papillitis represent a true engorgement œdema, and that the evidence of inflammation, at least in any decided degree, is lacking, while in others the inflammatory signs are decided. Where engorgement œdema is the marked feature the ophthalmoscope reveals the typical picture of choked disk. In other cases, however, the elevation of the disk is less decided and the inflammatory condition predominates, the process extending to the retina, where exudates and hemorrhages are visible; in other words, an inflammatory optic neuritis is present. Kampherstein, as the result of his own work and the review of the observations of others, declares that in our present state of knowledge there can be no absolute adherence to the mechanical theory, especially championed by Schmidt-Rimpler and Manz, a theory which is often known as the lymph-space theory; neither is it possible to explain all cases by assuming a descending inflammation which passes from the lesion in the brain to the end of the optic nerve, as many for example, Gowers, are inclined to believe, nor by adopting the theory that the papillitis is not the product of an œdema but is an inflammatory affection in the sense that the fluid distends the sheath of the optic nerve and possesses an irritative quality. He does believe that the condition often is best explained by a preceding œdema of the brain extending through the optic nerve to the lamina cribrosa, and thus causing choking of the nerve-head. As, however, the percentage of eyes in which there is neither œdema of the nerve nor distention of the interspace is a large one, it is impossible to accept alone the mechanical theory, and raised pressure sufficiently maintained must, in a certain number of instances at least, be the direct cause of choked disk.

The important fact remains, no matter which one of the theories is adopted, that there may be a subsidence of optic

neuritis after operation undertaken with a view to the removal of an intracranial tumor, even if the tumor is not removed. In other words, palliative trephining is of the utmost importance and is an operation which should be practised early. Much has been written upon this subject, notably by Horsley, Bruns, Erb, Taylor, Saenger and others, but in many respects the most satisfactory study of its great advantages, both when the tumor is removed and when it is not removed, is by Leslie Paton.<sup>1</sup> His material consisted of thirty cases in which he was able to trace the changes in the eye conditions subsequent to operation as they occurred in the National Hospital in Queen Square. In general terms, useful vision was saved in 22 out of 30 cases, and in 18 the vision at the time the last record was made was as good as it was before the operation. It is not quite clear from the records just how often the entire tumor was removed, but apparently in 18 of the cases, while in 5 of them the operation consisted either in simple trephining or in trephining with an effort, but an unsuccessful one, to find the tumor. In 7 of them it is not definitely stated whether the growth was removed or not. All of the operations were done in two stages, the first, consisting in removal of the bone and, if the intradural tension was high, incision of the dura, and the second one a week later, in which the tumor itself was removed if possible. Some examinations were made between the first and second stages with the result that little measurable alteration could be seen in the disks. Usually, within a week or a fortnight after the second operation, there was definite subsidence of the swelling, and this subsidence continued so that at the end of two months in most cases the swelling had disappeared.

I have studied a number of cases in the surgical practice of Dr. W. W. Keen, Dr. Edward Martin and Dr. Charles H. Frazier, and in general terms I can confirm the results recorded by Paton. My experience has been somewhat as

---

<sup>1</sup> Transactions Ophthalmological Society of the United Kingdom, xxv. 1905, p. 129.

follows: Usually there is no distinct change in the swollen nerve-head after trephining in which the dura has been opened, or after the removal of a tumor, until the tenth to the fourteenth day.<sup>1</sup>

After this period there is gradual subsidence of the neuritis, from six weeks to two months being required for its complete disappearance. The ultimate vision may be (*a*) better than that which existed prior to the operation; (*b*) equal to that which existed prior to the operation; (*c*) worse than that which existed prior to the operation. Sometimes total blindness results. In the cases with preservation of vision, either as good as or better than that which the patient possessed before the operation, the sight may be better in one eye than the other, or exceedingly defective in one eye and good in the other, or one eye may be blind and the other retain or regain excellent vision.

Naturally, the most satisfactory results follow the reduction of great intracranial pressure, provided the papillitis or choked disk has not so long existed that it has already destroyed the optic nerve fibres. Three cases illustrating the effect of operation on papillitis may be quoted:

1. Sarcoma of cerebellum; choked disks each eye 7 D. Tumor removed by Dr. Frazier. No change noted (daily examinations) until the fourteenth day after operation, when apex of disks was 6 D. During the next fourteen days there was rapid decline in the swelling, so that twenty-eight days after operation it was only 3 D., and the edges of the disks were beginning to appear. Within the next month all neuritis disappeared and post-papillitic atrophy was present. Blindness was complete, but vision had equalled only light perception prior to operation.

2. Cerebral tumor; choked disks each eye, 6 D. in right and 4 D. in left; vision,  $\frac{6}{1\frac{1}{2}}$ . Craniectomy and opening dura by

---

<sup>1</sup> Dr. Spiller informs me that marked subsidence of engorgement œdema has been seen at the end of forty-eight hours. I have not observed such an early change in any case.

Dr. Frazier. First distinct change noted in disk, thirteen days after operation, followed by rapid subsidence, ultimate vision,  $\frac{6}{12}$ .

3. Cerebral tumor (cerebellar?); double choked disk, right + 9 D., left + 7 D. Vision: O. D.,  $\frac{6}{15}$ ; O. S., blind. Trephining by Dr. Frazier. No change in disk until the eleventh day, then right, + 10 D., left + 10 D., showing slight increase in swelling on the blind side. Swelling then remained stationary for nine days, when rapid subsidence began, and at the end of six weeks most of the swelling had subsided. Vision: O. D.,  $\frac{6}{9}$ ; O. S., blind.

In a certain number of cases during the first day or two after trephining there may be a slight increase in neuritis, or, more accurately, a slight increase in œdema, associated with fresh hemorrhages. This is apparently of no importance, as the added œdema and fresh hemorrhages disappear in the subsequent general subsidence of the swelling. In some of these cases there are marked degenerative changes in the retinal vessels. An illustrative case is the following: Tumor of cerebrum; double choked disks: right, + 4 D.; left, + 5.50. Removal of the tumor by Dr. Frazier in two operations four days apart. Five days later increased neuritis and many fresh hemorrhages; marked sclerosis of retinal vessels. Patient had widespread arteriosclerosis.

Mr. Paton has also noticed in four of his cases fresh hemorrhages after operation, usually within ten days after removal of the growth, and in one case a month after operation. He has also in two cases observed a slight recrudescence of the swelling occurring usually within the first month. That a second attack of optic neuritis may occur, I have shown by a case already reported.

A matter of some importance which I have noted on several occasions is temporary depreciation of vision within the first week after the operation, probably due to shock, perhaps to hemorrhage, and which is apparently of no importance in the subsequent restoration, or rather preservation, of vision,



provided the primary vision has been good and the neuritis of comparatively short duration. In cases, however, in which very little vision exists prior to the trephining, for example, a vision reduced to hand movements, or even light perception only, this may rapidly disappear after trephining, especially if there has been much hemorrhage. For example, in three recent cases, namely, a tumor of the lobe of the cerebellum, a growth of the pontial angle, and a cyst of the left lobe of the cerebellum, all young women, vision had been reduced prior to operation to hand movements in two and to the ability to distinguish very large letters held close to the eye in a third, were completely blind, even to the abolition of light perception within the first week after operation, although in each instance the surgical success was a brilliant one.

In the discussion of Mr. Paton's paper, before referred to, Risien Russell stated that there was no doubt in his mind as to the value of trephining with the object of saving sight in cases of intracranial tumor, and that he never hesitated to recommend the operation, even when there was no chance of either localizing the growth or of removing it because the relief of intracranial pressure alone might be the means of preserving vision. He was quite sure, however, that it was necessary not merely to remove a piece of bone, but that the dura mater should also be opened. That palliative trephining for the sake of saving sight is a proper operation is abundantly confirmed by my own experience, and the earlier it is performed the better will be the patient's chances of retaining or regaining his vision.

*Significance of Optic Neuritis.* Although the presence of bilateral papillitis is highly significant of cerebral tumor, of itself it possesses no distinct localizing importance. In this connection, however, it is proper to quote from J. M. Martin's careful analysis of 601 brain tumors that optic neuritis is constantly present in cases of tumor of the corpora quadrigemina, that it is present in about 90 per cent. of cases of tumor of the cerebellum and posterior part of the cerebrum,

and that it is absent in nearly two-thirds of the cases of tumor of the pons and medulla and of the corpus callosum. Unilateral optic neuritis, or decided excess of neuritis in one eye, indicates, as already noted, that the tumor is on this side. Martin shows that the seat of the lesion is probably on the side on which the optic neuritis is more marked in the proportion of 71 to 29. The assertion of some observers that one-sided optic neuritis indicates a tumor on the corresponding side situated in the temporal lobes is emphatically denied by Bruns. That temporary amaurosis may have a localizing significance and indicate a tumor of the occipital lobe, as stated by Bruns, is doubted by Oppenheim, and is contrary to my own experience. Paton found the symptom most often in cerebellar tumors. In the most marked case I have seen the growth was in the left motor area. No positive conclusions as to the size of the tumor can be drawn from the intensity of the choking of the disk, because although great engorgement edema may be caused by a large tumor, the reverse is sometimes true, and a small tumor may be associated with great swelling of the nerve-head. Sudden increase in the neuritis or engorgement may be suggestive of sudden increase in the size of the lesion or of the intracranial pressure.

#### ANOMALIES OF THE VISUAL FIELD.

Changes in the visual field in optic neuritis are not uncommon. Thus, in Kampherstein's list of 200 cases some form of alteration was present in all but 17 cases, and 16 of these were quite recent ones. There may be irregular and concentric contraction of the visual field, increase in the size of the normal blind spot, which becomes correspondingly great in conformity with the amount of swelling, the formation of an abnormal blind spot or scotoma due to involvement of the axial fibres, and sometimes to destruction of the ganglion cells, the absence of half of the visual field (hemianopsia)

when the intracranial tumor which may have been the cause of the papillitis is so situated as to produce these phenomena. Finally, there may be defective color perception which may exist when there is no change in the central vision and no limitation of the form field: In one of Kampherstein's cases there was total color blindness. In this case, however, there was also contraction of the visual field.

Of more importance than any of the changes in the visual field are the various types of hemianopsia. Naturally, in bitemporal hemianopsia, sometimes called the localizing form of hemianopsia, it is usually fair to assume that there is obstruction in the conductivity of the crossed fasciculi, the non-crossed fasciculi remaining intact. Thus, in a recent case of typical bitemporal hemianopsia, which I studied in the practice of Drs. Mills and Tyson, a metastasis from mammary carcinoma was so situated that the optic chiasm was invaded and pressed by it. It is, therefore, a well-known sign of basal tumors and of tumors of the pituitary body, but it should be remembered that a growth at a distance from the chiasm may occasion a field simulating a bitemporal hemianopsia. For example, as Swanzy, Gowers and others point out, a tumor of the cerebellum by closure of the aqueduct of Sylvius may produce internal hydrocephalus and thus exert pressure on the chiasm. So far as I am aware, bitemporal hemianopsia has never been observed, as has cortical hemianopsia, as a distinct symptom. Destruction of the retinal ganglion cells in connection with papillitis may give rise to fields of vision which closely simulate hemianopsia.

A symptom of some importance which may be mentioned here is the so-called *chiasmal central amblyopia*, in which, according to Nettleship, "the loss of the central field in the earlier stages is more rapidly defined than in tobacco amblyopia, and the symmetry less precise both in time and degree than in the latter disease." In one such case the chiasm was involved by a cyst.

Tumors which press upon the optic tract or the visual pathway posterior to the optic chiasm naturally produce homonymous hemianopsia, which, hence, is a symptom of great importance in locating the tumor, but which is not now under discussion. Homonymous hemianopsia, however, may be a distant symptom and not give a true indication of the situation of the growth. In a very remarkable case, which I observed in the practice of Dr. H. C. Wood, and which has been reported by him, a large growth existed in the temporo-sphenoidal lobe, but what at that time was considered the most important localizing sign, namely, a lateral hemianopsia, was caused by a small cyst in the cuneus, not connected with the growth, the situation of which, indeed, was unsuspected until an autopsy revealed its presence.

Although anomalies of the ocular muscles and the movements of the eyeballs constitute an important part of the symptomatology of certain brain tumors, their consideration is omitted from the present paper because in so far as they assist in localization they are discussed elsewhere by Drs. Mills and Weisenburg.

There are no characteristic pupil-phenomena, and, as Kampherstein has shown, in the majority of cases of choked disk the pupil reaction is normal. Although with complete loss of vision due to atrophy the pupil is usually immobile to light impulse, it is not invariably so, as Kampherstein records normal reaction in five cases of total blindness, in three of which optic nerve atrophy was present. Such cases he regards as demonstrating how resisting are the fibres of the optic nerve which convey the light reflex, provided the degenerative process is local in the nerve and the central fibres are not destroyed.

# CONJUGATE DEVIATION OF THE EYES AND HEAD AND DISORDERS OF THE ASSOCI- ATED OCULAR MOVEMENTS.

IN TUMORS AND OTHER LESIONS OF THE CEREBRUM.\*

---

T. H. WEISENBURG, M.D.

Instructor in Nervous Diseases and Neuropathology, University of  
Pennsylvania; Assistant Neurologist to the Philadelphia  
General Hospital.  
PHILADELPHIA.

---

## VARIOUS VIEWS DISCUSSED.

Within the past two years the causes of conjugate deviation of the eyes and head have repeatedly been the subject of controversy, especially by certain French writers. In 1904, Bard<sup>1</sup> advanced the sensorial theory of conjugate deviation, although this had been spoken of previously by Roux.<sup>2</sup> This theory has since been ably supported, especially by Dufour,<sup>3</sup> and opposed by Grasset,<sup>4</sup> Dejerine and Roussy,<sup>5</sup> and others.

Chiefly through the kindness of Dr. Charles K. Mills and Dr. William G. Spiller I have had the opportunity to study 16 cases of conjugate deviation of the eyes and head, 15 of which are with necropsy, and I have attempted to come to such conclusions as to the causes of conjugate deviation of the eyes and head as the evidence in these cases will permit, together with the aid of cases in the literature.

Disorders of associated ocular movements occurring in lesions of the cerebrum will be discussed only in so far

---

\* Read in the Section on Nervous and Mental Diseases of the American Medical Association, at the Fifty-seventh Annual Session, June, 1906.

\* From the Department of Neurology and the Laboratory of Neuropathology, University of Pennsylvania.

1. Bard: *Semaine Médicale*, Jan. 13, 1904.

2. Roux: *Arch. de Neurol.*, September, 1899.

3. Dufour: *Rev. Neurol.*, April 15, 1904.

4. Grasset: *Rev. Neurol.*, July 15, 1904.

5. Dejerine and Roussy: *Rev. Neurol.* No. 3, Sept. 15, 1905.

as they occur in association with conjugate deviation of the eyes, and in cases of hemianopsia due to peripheral or central lesions. The importance in clinical diagnosis of paralysis of associated movements of the eyeballs has been discussed only recently by Spiller.<sup>6</sup>

The literature is replete with instances of conjugate deviation of the head and eyes as a result of lesions in almost every part of the brain. Experimental investigations on lower animals confirm what has been said of the pathologic evidence, for it has been shown that electrical excitation of any portion of the brain, if of sufficient intensity, is productive of deviation of the eyes, or of the head, or both.

There is good reason for this. Perhaps no function is more highly specialized than that which is concerned with the movements of the head and of the eyes. These are constantly moved for one reason or another; the auditory and the visual senses probably playing the most important part in the determination of these movements. Such specialization of function necessarily needs and acquires a most complex cortical representation.

With our present knowledge of cortical representation we should expect a motor center for the movement of the head, a separate center for the eyes, and still another for the combined movements of the head and eyes. Within the past few years the cortical centers for all, or nearly all, motor function have been placed in front of the central fissure. This has been borne out by experimental and pathologic evidence. We should expect, therefore, that there should be but one motor center for each function, and that center anterior to the Rolandic fissure. It has been shown that movements which are performed conjointly by corresponding or correlated muscles on both sides of the body have a cortical representation in each cerebral hemisphere. Therefore we should expect a bilateral cortical representation for the deviation of the eyes and of the head.

Any auditory, visual, or olfactory stimulus will cause conjugate deviation. Touch, pain, or temperature stimuli will also cause deviation. Besides it has been held that reflex or automatic and voluntary impulses initiated independently of these senses may cause such deviation.

---

6. Spiller: *Jour. Nervous and Mental Dis.*, July and August, 1905.

Taking up the subject of conjugate deviation of the eyes or of the head, or of both, as the result of anyone of the above-mentioned sensory stimuli, what is the cerebral mechanism of this conjugate deviation? Illustrating by the sensation of hearing, we presume that an auditory impulse is first transmitted to the auditory center in the temporal lobe, from here it is carried by means of association fibers to the motor-center, from which motor impulses are transmitted to the nerve cells which supply the muscles concerned with the function to be performed. In like manner a unilateral motor center for the conjugate deviation of the eyes and head should be in intimate connection by means of association fibers, not only with the auditory center in the temporal lobe, but also with the visual center in the occipital lobe and with the olfactory centers in the uncinata gyrus and the gustatory center wherever situated, and with the centers for touch, pain and temperature senses in the parietal lobe. In brief, sensory irritation in any portion of the body will cause deviation of the head and eyes in the direction of the irritation through the correlated activities of the sensory and motor centers concerned. Not only that, but the centripetal fibers which transmit these impulses from the periphery to the cortex must be intact for the proper interpretation of these stimuli; and the centrifugal motor tracts must also be intact for the physiologic performance of their functions. Should any portion of this most complex mechanism be disturbed, the result would be failure in normal deviation of the head and eyes, the deviation depending entirely on the nature and location of the lesion.

The most recent writers on this subject, Cantonnet and Taguet,<sup>7</sup> advance the idea of an automatic or reflex center for ocular movements in the optic thalamus. In support of this they quote cases of cortical lesions in which there was paralysis of voluntary ocular movement, but in which reflex or automatic movements were preserved. We have always regarded reflex movements of the eyes as best illustrated by the fact that the eyes will follow the moving finger or hand in different directions; and that similar deviation will take place in response to various sensory stimuli. It would, perhaps, be advisable if we were to define "reflex" and "auto-

---

7. Cantonnet and Taguet: *Rev. Neurol.*, No. 7, 1906. p. 308.

matic" movements more clearly. When the eyes deviate in a certain direction because of a noise, that is a reflex action, only in the sense that a movement is performed because of a sensory stimulus. If the sensory part of the reflex arc is disturbed, as in deafness, no amount of noise will cause deviation. Why should this be called an automatic movement?

It has been shown that in lesions of the thalamus, we sometimes have such symptoms as forced or involuntary laughing or crying, and in lesions of the superior cerebellar peduncle there may be incoördinate movements of some of the limbs. These are examples of automatic movements. If we assume that a similar automatic center exists for ocular movements in the thalamus, should not a disturbance of such a center cause forced or incoördinate ocular movements?

In his very able presentation of the subject of associated ocular movement, Spiller<sup>10</sup> agrees with others that paralysis of associated ocular movement laterally is due to lesions of the posterior longitudinal bundle, and asserts that a paralysis of upward and downward movement is probably the result of a lesion near the oculomotor nuclei. He believes that a tract similar to the dorsal longitudinal tract, and possibly a part of this fasciculus, situated near the oculomotor nuclei, connects these nuclei, and that an interruption of the tract causes failure of associated upward or downward ocular movements. He does not admit the need of a basal coördinating center for ocular movements, near the oculomotor nucleus.

When the eyes follow the finger, this is really an associated movement, and the result, not of a pure reflex action, but of a distinct sensory (visual) impression, in the same sense that a noise (auditory impression) will cause deviation of the eyes. If the sensory arc is interfered with as in blindness, the eyes will, of course, not be able to follow the finger as the result of a visual impression.

A voluntary movement is the result of a stimulation of a motor center. The question arises whether in a normal individual a pure voluntary impulse is possible without a previous sensory stimulation, the term sensory stimulation being used here in its broadest sense. When we will to move the eyes independently of any immediate sensory stimulus, as when in meditation, there is at least



a psychic stimulus to the cortical oculomotor center (that is, the center for the movements of the eyeballs). this stimulus may come, for example, from the higher psychic areas of the prefrontal lobe, but it is intimately dependent on stored impressions at one time or another received or accumulated by means of sensory mechanism, and moreover in the act of using the eyes in such circumstances as when one wills to read a book or to look at the stars, sensory impression takes part in the lateral and upward movements. It is probable, therefore, that a centrally initiated voluntary impulse is dependent on the functioning of a central reflex arc, and that any interference with this would cause deviation.

Summing up the views so far advanced, it is my opinion that the movements of the head and eyes are dependent on a most complex mechanism; that there is only one true or at least functionally important cortical motor center anterior to the central fissure; that this motor center is in immediate connection with the sensory portions of the brain; that whenever the head and eyes are moved it is the result of a sensory stimulation, and that any interference with the sensory-motor arc will cause impairment of this function. Let us now consider in order the embryologic, anatomic, physiologic and pathologic evidence in support of these views.

#### EVIDENCE IN SUPPORT OF VIEWS.

The well-known myelogenetic investigations of Flechsig<sup>8</sup> support these views. According to him, in his primordial zones or regions of early development are included exclusively projection fibers, sensory and motor, or, as he terms them, corticopetal and corticofugal. He believes that for every sensory path there is a corresponding motor path. In the primordial zones are included the motor and sensory regions, the visual or occipital lobes, the auditory or upper temporal regions and the olfactory and gustatory centers principally in the anterior temporal region. The myelogenetic differences between the primordial and the intermediate and terminal zones, according to Flechsig, are the result of successive development of different sense organs and their motor or centrifugal paths, and the development of long and short association systems.

---

8. Flechsig: "Gehirn und Seele." Leipzig, 1896.

In the main these views have received physiologic and pathologic confirmation. What appears to be the view of Flechsig that each primordial area is both sensory and motor can not be altogether agreed with, but it must be recalled that his views are only relative, for in his myelogenetic area No. 1, which corresponds with some closeness to the central convolutions, the tactile radiation is distributed mostly to the postcentral convolution, while the tract which is undoubtedly motor originates from the precentral convolution. This would argue for separate cortical representation for motor and sensory functions, and would accord with our present views.

With the auditory or cochlear myelogenetic area in the first temporal convolution Flechsig finds a corticofugal radiation, which he believes may be motor, although this has not as yet been demonstrated. The cells and fibers which constitute this radiation lie at the lower border of the first temporal and in the furrow which separates it from the second temporal convolution. He assumes that motion of the head and of the body following an auditory impression may be performed through the intermediation of corticofugal fibers which originate in or near this center. Similarly, Flechsig reasons that movements of the eyes and of the head consequent to visual stimulation are due to the intermediation of corticofugal fibers from or near the visual zone. Motion as a consequence to olfactory stimulation can likewise be explained.

According, then, to Flechsig's view, a movement of the eyes or of the head is the result of a sensory stimulation and may be due to an auditory, visual or other sensorial impression coming by way of the corticofugal fibers which originate in these centers. I do not agree, however, with the view that the corticofugal fibers coming from the special sense centers are purely motor projection fibers, as Flechsig appears to believe. Undoubtedly the corticofugal radiations associated with the corticopetal radiations in Flechsig's myelogenetic area No. 1, which corresponds to the sensory and the motor centers around the central fissure, are purely motor. The corticofugal radiations of the primary auditory and visual zones are probably not purely motor projection fibers, but in large part are fibers which connect these special sense areas with the oculomotor centers in the

main motor region. A sudden auditory stimulation will, of course, cause immediate turning of the head and eyes, but this is not because, or at least not usually because, a motor impression is transmitted by the corticofugal fibers directly from the auditory center to the nuclei which are concerned with the muscles necessary to perform that function, but rather because the auditory impression is transmitted by means of association fibers to the motor cortex and thence to the basal nuclei.

When an auditory impulse is received in the temporal convolution it may be stored up in the auditory memory center, it may be transmitted to the visual center and recall visual images associated with the sound produced, it may cause olfactory or gustatory stimulation or it may cause the movement of almost any portion of the body as the person wills. In the performance of all these possible functions it is necessary to have the auditory center in direct communication with the other sensory centers, and this is accomplished by means of associated fibers, the existence of which have been repeatedly demonstrated; similarly the visual centers are likewise in association with other centers.

Mills<sup>9</sup> believes that each sensory area has its motor correlative and that each of these has its separate cortical representation. He speaks of a sensory motor, visual motor, auditory motor, gustatory motor, olfactory motor and a possible equilibratory motor area. According to Mills, this conception does not do away with the importance of our old-time motor area, which still remains the great or main motor region. His view is that at least in the highly developed human being the centers for movements of the head and eyes and for other movements have largely taken the place of the motor projection fibers which exist in, or in close contiguity with, each of the special sense areas; in other words, the visual motor area, auditory motor area, olfactory motor area and gustatory motor area are largely, although probably not altogether, in abeyance in movement, although still retaining their importance to a greater or less degree in the animal scale below man. If this be the case, the arguments brought forward in this paper which are based on the idea of a single active functioning region for movements of the head and eyes are valid; in other

---

9. Mills: "Brain," 1889, and *Univ. of Penna. Med. Bulletin*, May, 1904

words, we can disregard all cortical motor areas except those which lie in front of the central fissure.

Experimental investigations also confirm my views, for it has been shown that electrical excitation of any portion of the brain, if of sufficient intensity, is productive of movements of the head and eyes. Four principal areas have been found in the brain of lower animals in which electrical stimulation will produce these movements: in the frontal lobe, in the so-called neck or head region, in the angular gyrus and in the occipital lobe. Partly because of the fact that stimulation of the posterior portion of the second and third frontal convolutions and the region near the angular gyrus is always productive of movements of the head and eyes, these two areas have been considered by various authors as the motor centers for these functions.

Landouzy<sup>10</sup> and Wernicke<sup>11</sup> were among the first to favor the area near the angular gyrus or the *pli courbi* of the French. The physiologic experiments of Luciani and Tamburini,<sup>12</sup> Ferrier,<sup>13</sup> Munk<sup>14</sup> and Obregia<sup>15</sup> supported their views, for stimulation of this region constantly caused deviation of the eyes and head. Against this view, however, were the extirpation experiments of Brown and Schäfer<sup>16</sup> on the brains of apes in which conjugate deviation was not obtained. Again Flechsig has shown that this area contains few projection fibers. It is probable that electrical stimulation of the occipital and parietal regions causes deviation of the eyes and head, not because of a motor center in these areas, but because of stimulation of the visual and auditory fibers, respectively. It has been shown that underneath the angular gyrus lie the fibers from the occipital and auditory lobes, and it is because of the combined involvement of these that any stimulation or lesion of this area causes such constant deviation of the head and eyes.

---

10. Landouzy: Thèse, de Paris, 1876.

11. Wernicke: Arch. f. Psychiatrie, 1888, vol. xx, p. 243.

12. Luciani and Tamburini: See Klaas' Dissertation, Marburg, 1898.

13. Ferrier: "Hirnlocalisation," 1890, Leipzig and Vienna.

14. Munk: "Sitzungsberichte der Kgl. akad. der Wissenschaften zu Berlin," 1890.

15. Obregia: Archiv. f. Anat. u. Physiol., 1890, p. 260.

16. Brown and Schäfer: Phil. Trans., Royal Society of London, 1888.

The work of Ferrier,<sup>13</sup> Mott and Schäfer,<sup>17</sup> Beevor and Horsley,<sup>18</sup> and lately of Sherrington,<sup>19</sup> has conclusively proved the existence of an oculomotor center in the posterior portion of the second and third frontal convolutions. The existence of a separate center for the movement of the head, for the eyes and a combined center for the movement of the head and eyes has been repeatedly shown in lower animals, and it is probable that such differentiation also exists in man. Beevor and Horsley<sup>18</sup> in apes (*Macacus sinicus*) found an isolated center for movement of the head, for the eyes and for the head and eyes in the posterior portion of the first, third and second frontal convolutions, respectively. Later these authors found in an orang-outang, in the precentral convolution, underneath the hand region, a center in which irritation caused deviation of the head and eyes, and, on the other side of the brain, deviation of the eyes alone because of irritation of the foot of the second frontal convolution.

A critical study of the evidence furnished by the physiologic experiments in lower animals favors the view that there is a separate center for the movement of the eyes in the foot of the second frontal convolution, that a separate center for the movement of the head exists in the lower part of the precentral convolution along its anterior edge, and that further stimulation of either area may cause a combined deviation of the head and eyes.

Normally, the head and eyes are moved together more often than separately, and the eyes more than the head in separate movement. We should expect, therefore, from developmental and physiologic reasons, that the oculomotor center should be better developed than the head center, and that stimulation of the head center should more often give conjugate movement of the head and eyes than stimulation of the eye center. This is proved by the experiments of Beevor and Horsley,<sup>18</sup> Ferrier<sup>13</sup> and Mott.<sup>17</sup> The experiments of Sterling<sup>20</sup> are of extreme interest in this connection. This author irritated the so-called neck region in young animals and found that he could obtain movements of the head alone

---

17. Mott and Schäfer: "Brain," 1890.

18. Beevor and Horsley: Phil. Trans., Royal Society of London, vol. clxxxI, 1890, p. 129.

19. Sherrington: Jour. Phys., 1894.

20. Sterling: Arch. f. Anat. u. Physiol., Phys. Ab., 1903, p. 486.

in dogs 8 days old, whereas associated movements with the eyes could not be obtained until the twenty-first day. He did not perform the converse experiment by irritating the ocular centers alone, which would be interesting. We can, however, argue from this that separate centers for the eyes and head exist, and that because of association between them irritation of one may cause movement of both. It is also for this reason that irritation of other portions of the brain besides the motor, cause in most instances combined movement of the eyes and head.

Our knowledge of the direction of the movements of the eyes and of the head is chiefly in regard to lateral deviation. Reasoning from analogy, we should expect a separate center for upward and downward movement, as well as for lateral movement. The experiments of Mott<sup>17</sup> proved that this exists in lower animals. By irritating, in apes, the posterior portion of the frontal convolution he obtained movement of the eyes in a horizontal direction, to the opposite side and upwards, and to the opposite side and downwards, the points irritated lying from the median to the lateral side, laterally, on the outer side and in the median portion, respectively. A similar order was present for the movement of the head. Schäfer was enabled to obtain somewhat similar results by stimulating different parts of the occipital lobe.

Permanent paralysis of upward or downward associated ocular movement is only rarely observed clinically, and, as Spiller has shown, is probably due to lesions near the oculomotor nucleus. In pathologic conjugate deviation of the eyes the deviation is sometimes laterally and upward or downward, as in Case 7 of my series; but I know of no reported case in which the conjugate deviation of the eyes was purely either in an upward or downward direction. There are several physiologic reasons for this. In the first place, lateral movements of the eyes are better developed than upward movement, but perhaps no better than downward movement. There is still another important factor: One side of the brain controls movements of the eyes and head in the opposing direction; the tendency for deviation would, therefore, naturally be in a lateral direction. This was well shown in the experiment of Mills,<sup>9</sup> who faradized in man the head center and obtained deviation of the head to the opposite side.

The functions of convergence and divergence are considered by the majority of authors as reflex phenomena with possibly basal centers. This I believe, however, to be an error. I am of the opinion that they are as much muscular movements and dependent on a similar mechanism as either lateral, upward or downward associated ocular movement. In convergence the internal recti muscles of either side are used, while in divergence the external recti are called into action. Should, for instance, an internal rectus be paralyzed, the corresponding eye will not be able to converge. This can be compared to failure of associated lateral movement of one eye, if the external rectus is paralyzed.

If we believe, as no one doubts, that there is a connection between the external rectus muscle of one side with the internal rectus of the other by means of the posterior longitudinal bundle, and if, as Spiller believes, there is a similar tract connecting the nuclei of the superior rectus and inferior oblique muscles of one side with the corresponding nuclei of the other side, and if this bundle is concerned with upward movement, and if there is another tract for downward associated ocular movement, why should not there be a similar tract connecting the internal recti nuclei and another connecting the nuclei of the external recti, these having to do with convergence and divergence?

It is true that the existence of such tracts has not been demonstrated, but neither have the tracts which are supposed to be concerned with upward and downward movement. There are, however, clinical facts which support this view. In the majority of cases of paralysis of associated ocular movement due to pontile lesions, either convergence or divergence is lost. In the statistics collected by Spiller, of 47 cases, the condition of convergence was noted in 26. Of these, convergence was impaired in 15 cases, and in 9, normal or nearly normal. In most of the cases in which convergence was said to be normal, the observations were made some time before death, and this function might well have been lost later.

It is more than probable that convergence and divergence have also cortical representation and that this is in the posterior portion of the second and third frontal convolutions. This subject will be fully discussed in a subsequent paper on paralysis of associated ocular movements due to basal lesions.

Let us now consider the pathologic evidence. Con-

jugate deviation of the head and eyes may occur as a result of lesions causing hemiplegia, in tumors of various localities, in areas of softening, in meningitis, in epilepsy; in fact, it can be shown that any lesion in any portion of the brain may cause deviation. Consider, for instance, the statistics collected by Grasset.<sup>21</sup> Of 104 cases, 48 with necropsy, in 2, lesions were shown in the frontal lobe; in 10, in the frontal and other areas; in 25, in the internal capsule and cerebral peduncles, and in 11 the lesions were diffuse.

In the 16 cases with necropsy reported in this paper, lesions were found in almost every portion of the brain. In Case 1 an area of softening was found in the frontal lobe. In Cases 3 and 4 there were diffuse cortical hemorrhages in the frontal, parietal and occipital lobes. In Case 5 a hemorrhage was found directly in the angular gyrus. In Case 6 a hemorrhage was found in the occipital lobe and an area of softening in the precentral convolution. In Case 7 (Fig. 1) a large fibrosarcoma occupied the whole of the occipital lobe. In Case 8 there was a thrombosis of the middle cerebral artery. In Cases 9, 10 and 11 there were hemorrhages in the posterior limb of the internal capsule and the neighboring parts. In Cases 12, 13 and 14 there were lesions in the lenticular nucleus and external capsule. In Case 15 there was a lesion of the lenticular nucleus alone. In Case 16 (Fig. 2) there was an area of softening involving the anterior limb of the internal capsule and lenticular nucleus, with a fresh hemorrhage underneath the angular gyrus. Besides in Cases 14 and 15, in which no fresh hemorrhages were found, there was dilatation of the lateral ventricles.

If we consider more minutely the location of the lesions causing conjugate deviation, we find three principal areas involved: 1. The frontal area. 2. The area of the angular gyrus. 3. The internal capsule. We can still further subdivide these regions. In the frontal areas there are recorded cases of lesions involving the posterior part of the second (Sahli,<sup>22</sup> Drummond<sup>23</sup> and Oppenheim,<sup>24</sup>) and others of the posterior part of the second and third frontal convolutions (Klaas,<sup>25</sup> Case 4 of my series, and others). Besides, there are a large number of recorded cases of lesions involving the pos-

21. Grasset: "Des Localisations dans les Maladies Cérébrales." Montpellier, Paris, 1880, pp. 215 to 238.

22. Sahli: Deutsch. Arch. f. klin. Med., vol. lxxxvi, No. 1-3, p. 1.

23. Drummond: Lancet, 1887.



terior portion of the second and third frontal convolutions, the adjacent precentral convolutions and other areas, as in the cases collected by Müller<sup>26</sup> and Klaas.<sup>25</sup> The important factor is that in all of these cases the posterior portion of either the second or third frontal convolutions or the adjacent part of the precentral convolution was involved.

Of the lesions in the region of the angular gyrus may be included any lesion in or near this area. Whatever in this region causes conjugate deviation must cause interruption of the fibers underneath the angular gyrus.

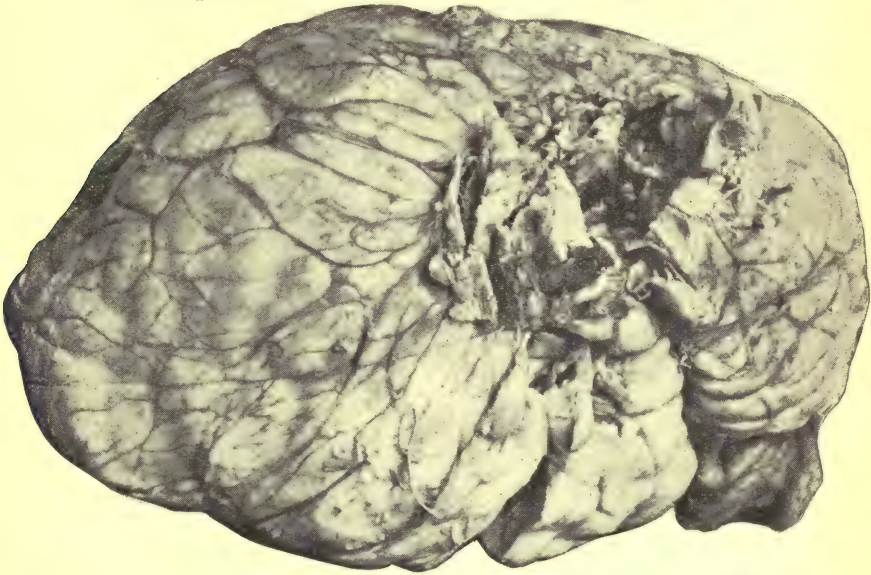

Fig. 1.—A fibrosarcoma of one occipital lobe, causing besides other symptoms, paralysis of associated ocular movements, probably as the result of the hemianopsia (Case 7).

If the lesion is posterior to this point, as in Case 6, there is only an interruption of the fibers from the occipital lobe. If the lesion is directly in the angular gyrus or beneath it, as in Cases 5, 12, 13 and 14, there is an interruption of the fibers both from the occipital and temporal lobes. In every one of these cases the

24. Oppenheim: "Charité Annalen," 1885.

25. Klaas: Inaug. Diss., Marburg, 1898.

26. Müller: Deutsch. Zeitschr. f. Nervenhlk., 1902, vol. xxii, p. 375.

lesions extended underneath the cortex and must have involved the fibers coming from both these lobes.

In the lesions involving the internal capsule, a differentiation can be made between those involving the anterior limb and those involving the posterior limb. In the former the projection fibers from the frontal lobes are involved, while in the latter there may be an involvement of the motor, sensory or optic fibers. It is the opinion of some French writers, notably Bard,<sup>1</sup> that to cause deviation there must always be an involvement of the optic radiations. This, however, is not correct, as in most of the recorded cases, also in mine, there was no such involvement.

From the pathologic evidence, therefore, the conclusion must be drawn that lesions involving the posterior portions of the second and third frontal convolutions and the adjacent precentral convolution cause conjugate deviation of the eyes and head, and that when lesions elsewhere in the brain produce conjugate deviation there is an interruption either of the projection fibers in or near the internal capsule or of the association fibers between the occipital and temporal cortex and the frontal lobe.

Consider now the pathologic evidence regarding the oculomotor center in the frontal lobe. It is the opinion of some, as of Sahli,<sup>22</sup> that in man there is no evidence that a separate center for the movement of the head and eyes exists. Müller,<sup>26</sup> on the contrary, believes that there are separate centers for these functions, and he places both in the posterior portion of the second frontal convolution, the center for movement of the head being in the under portion and that for the eyes in the upper portion of this convolution. From the pathologic evidence at hand, no one doubts the existence of the oculomotor center in the posterior portion of the second and probably the third frontal convolution. The principal reason why lesions of this area cause deviation also of the head is because the head center is so intimately associated with the oculomotor center that an irritation or lesion of one will most likely cause involvement of the other.

That a separate center exists for the movement of the head was beautifully shown in the faradization experiment of Mills<sup>9</sup> in man, in which a faradic irritation in the lower precentral convolution caused movement of the

head alone to the opposite side. This is proven also in Case 6, in which an area of cortical softening was found in the lower precentral convolution, causing Jacksonian convulsions limited to the face and partly to the hand, and also causing deviation of the head to the other side, but the eyes were not moved. Therefore, the center for movement of the head in the lower part of the precentral convolution should be placed below and probably a little forward of the hand center.

It is more than probable that the cortical oculomotor center in the posterior portion of the second and third frontal convolutions is subdivided for lateral and upward and downward movements. According to Parinaud,<sup>27</sup> the center for upward movement is in the lowest portion of this area; for downward movement in the upper, and for lateral movement in the median portion.

Mills and Frazier<sup>28</sup> obtained forward movement of the head by irritating the anterior portion of the head center in the precentral convolution. In another case in which the records have been lost, Dr. Mills distinctly remembers obtaining upward movement of the eyes alone. This most important evidence proves that cortical centers for upward and downward movements for the head and for the eyes exist. It is also probable that a separate center exists for the combined movements of the head and eyes, and this center is probably between the individual head and eye centers. This center may also be subdivided for lateral and upward and downward movements.

#### DIAGNOSTIC VALUE OF CONJUGATE DEVIATION.

So far we have not considered conjugate deviation in a clinical sense, or its value in diagnosis. Conjugate deviation of the eyes and head occurs most often in hemiplegia, and its occurrence is considered an unfavorable sign, as most such cases end fatally. Also it is most always accompanied by unconsciousness. Indeed, Grasset believes that it always is. The conjugate deviation involves mostly the head and eyes together, but it rarely involves the eyes alone, as in Cases 4, 12, 13, 14, 15, and in exceptional cases the head alone, as in

---

27. Parinaud: *Arch. de Neurol.*, vol. v, No. 14, 1883.

28. Mills and Frazier: *Univ. of Penna. Med. Bulletin*, July, August, 1905.

Case 6. More rarely still, the deviation of the head is in one direction and the eyes in the other, as in Case 1. The only similar cases recorded are by Roussy and Gauckler,<sup>29</sup> Dufour (cited by Roussy and Gauckler<sup>29</sup>), one case of Prevost's (cited by Grasset<sup>21</sup>) and a case of Gausse.<sup>30</sup>

The deviation is never permanent and, as a rule, does not persist longer than two or three weeks and in most cases about a week. The deviation of the head is not so persistent as that of the eyes and is the first to disappear. At times, instead of there being a complete deviation there are jerking movements of the eyes, these being mostly in a lateral direction, but occasionally as in Case 13 they are in a lateral and upward direction. The jerking movements of the eyeballs are always from the median line to the external canthus and never in the whole range of movement. These nystagmoid movements must be differentiated from the violent jerkings seen in the course of a convulsion, these lasting only during the convulsion and always being to the opposite side of the lesion, whereas in the other conditions the jerkings may be to either side, depending on the nature of the lesion.

Prevost<sup>31</sup> first showed that deviation is toward the lesions when the lesion is cerebral and away from the lesion when it is in the isthmus. Some years later Landouzy<sup>10</sup> advanced the view that irritation and paralysis caused deviation in opposite directions when the lesion was in the cerebrum, the patient looking at the lesion when it is a paralyzing one and at the paralyzed limb when it is of an irritating nature. Grasset<sup>21</sup> later showed that the opposite was true in lesions of the brain stem. The above facts have been repeatedly demonstrated. It must be remembered, however, that the same lesion may at different times cause paralyzing or irritating symptoms.

Wernicke<sup>11</sup> first advanced the view that the rapid disappearance of the conjugate deviation of the head and eyes was owing to the partial control of these movements by the cerebral hemisphere of the sound side and to the action of its oculomotor and head centers. It is also because of the action of the oculomotor center in the unimpaired hemisphere that conjugate deviation can

29. Roussy and Gauckler: *Rev. Neurol.*, 1904, p. 763.

30. Gausse: *Semaine Médicale*, May 18, 1904.

31. Prevost: *Thèse de Paris*, 1868.

be most readily explained. If one oculomotor center or the fibers in association with it are injured or destroyed they cease to perform their function, at least for a time; therefore, the center in the sound hemisphere causes the deviation to the opposite side, which would cause the eyes to look at the lesion. In irritative lesions as in tumors, this rule is reversed because as in experimental investigations irritation of one side causes movement to the opposite side.

In those cases in which the deviation of the eyes alone, or of the head, occurs, it must be that their respective centers or their associated fibers are separately involved. Similarly, in those rare instances in which the head and the eyes are deviated in separate directions, there must be an irritating lesion acting on one center and a paralyzing one on the other. These clinical facts also argue for separate cortical centers for the eyes and the head.

If we compare the pathologic lesions causing conjugate deviation with others in which no deviation occurs, as, for instance, in a hemorrhage which causes hemiplegia, we may find a most remarkable similarity in their location and extent. Naturally the question arises, why should conjugate deviation occur as a result of one lesion and not of another? As a matter of fact, to a certain extent, this does happen in every case; only in some the symptoms are more marked. The deviation in other words is of minor or partial degree, but nevertheless real. Leichtenstern and Hunnius (cited by Klaas<sup>25</sup>) have shown that in cases of brain apoplexy in which no deviation occurred there was difficulty in looking to the side opposite the lesion, while the patient could easily look to the side of the lesion. This fact has caused Brissaud and Pechin<sup>33</sup> to call this symptom an "ocular hemiplegia," an excellent term. It may be that conjugate deviation only occurs when the lesion is large and the patient unconscious, or it may argue, according to some, that there is a special tract concerned with conjugate deviation, the existence of which, however, has not been demonstrated.

In 1904 Bard<sup>1</sup> gave a new impetus to the study of conjugate deviation of the head and eyes. He then advanced the view that in the greater number of hemiplegics with conjugate deviation we have present a more or less degree of lateral homonymous hemianopsia, and

---

33. Brissaud and Pechin: *Rev. Neurol.*, 1904, p. 638.

it is because of an active movement subconsciously commanded by the sensory-motor centers of the sound side that the patient turns the head and eyes of the sound side to regard that which he sees. Bard also says:

The exterior excitations produced by reflexes are not indispensable, the fact that because of the suspension of activities of the one hemisphere, the spontaneous evocation of the sensorial images has not always no part there, is capable of causing the lateral deviation and it is without doubt for this reason that these sometimes persist, just as they may appear during sleep.

Bard also elsewhere says that the sense of sight plays the predominating rôle in conjugate deviation of the eyes and head. His view has been supported by Dufour,<sup>29</sup> but denied by Grasset.<sup>4</sup> The case of Dejerine and Roussy<sup>5</sup> effectively disproves the views of Bard,<sup>1</sup> for in this patient in whom conjugate deviation occurred there was blindness from birth, showing that there need not be hemianopsia in association with conjugate deviation, contrary to the views of Dufour<sup>29</sup> and Grasset,<sup>4</sup> who believe that hemianopsia is a most frequent symptom. This I also believe to be an error. In most of the cases here recorded it was not possible to demonstrate hemianopsia; in fact, it was only possible to do this in three.

There is still another source of error. In many instances following an apoplectic attack there seems to be what clinically can be more or less satisfactorily demonstrated as a homonymous hemianopsia, but at necropsy the lesion does not involve the optic radiations. This hemianopsia may be transient, and may be demonstrated only for a day or so, or may remain longer, and can be likened to the temporary hemianesthesia so often seen in capsular lesions. In other words, it is my view that many of the hemianopsias demonstrated in these cases are only temporary symptoms and are due either to shock of the hemorrhage or to a fleeting injury of the optic radiations, and that this hemianopsia is the result of the lesion as much as the conjugate deviation and not the cause of the latter.

This is well demonstrated in Case 16. When the patient was examined by Dr. McConnell and myself she had, besides a right hemiplegia, a deviation of the head and eyes to the left. She could look to the left and upward and downward, but could not look to the right past the median line. In testing her with the hand or with the feeding cup a homonymous right, lateral hemi-

anopsia was repeatedly demonstrated. This was not obtained the following day. At necropsy an area of red softening was found involving the anterior portion of the left lenticular nucleus and the caudate nucleus, and a small hemorrhage was found just underneath the left angular gyrus. The optic radiations or the posterior limb of the internal capsule were in no way affected (Fig. 2). The hemianopsia was undoubtedly the result of shock, although the patient was fairly conscious and could obey commands.

To a certain extent hemianopsia does influence the associated movements of the eyeballs, but it probably has no effect whatever in producing conjugate deviation. It is well known that in cases of hemianopsia, whether of peripheral or central origin, the patients have a ten-

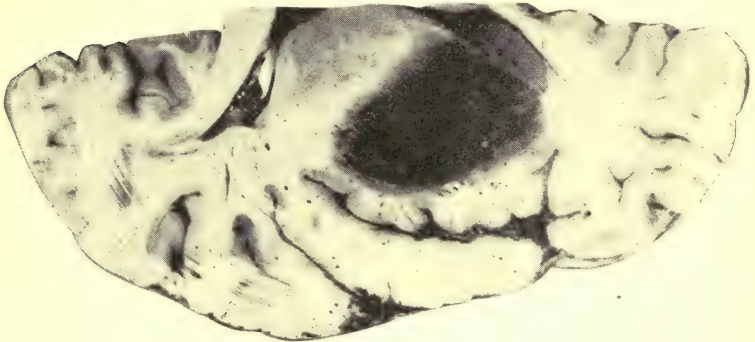


Fig. 2.—Area of softening involving the caudate nucleus and lenticular nucleus, with a fresh hemorrhage underneath the angular gyrus. Clinically, hemiplegia with temporary hemianesthesia and hemianopsia was demonstrated. The two latter symptoms were probably due to the shock of the hemorrhage (Case 16).

dency to deviate their heads, but here, instead of the head being deviated to the side in which one sees, the patient deviates the head to the hemianopic side because he desires to bring into use the part of the retina which is not diseased.

There is still another factor. If a patient has a hemianopsia of any duration he soon learns that he can not look to that side, and in a short time he will accustom himself not to deviate his eyes in that direction. If such a patient were to be suddenly asked to look in the direction of the hemianopsia, he would not be able to deviate his eyes immediately, or to deviate them so promptly as toward the sound side. This I was able to demon-

strate in two cases of hemianopsia due to a basal syphilitic lesion, and in one case was able to judge from this symptom on which side the hemianopsia existed.

In Case 7 paralysis of associated ocular movement existed to the hemianopic side, and this persisted until almost the time of death, for several months. This patient had a large fibrosarcomatous tumor, as shown in photograph (Fig. 1), which occupied the whole of one occipital lobe. This patient had first scintillating scotoma, then hemianopsia, hemianesthesia and hemiplegia. The paralysis of lateral associated ocular movement was not complete, and in this case was probably due to the hemianopsia.

During the active stage of conjugate movement of the eyes the patient can very easily rotate the eyes toward the side of the lesion, and also upward and downward, but in most cases can not deviate them toward the sound side. This paralysis of associated ocular movement is only relative and depends on the conjugate deviation. It is, of course, only temporary.

Irregular or ataxic movements of the eyeballs have been recorded as a result of lesions of the frontal lobe. Thus in a case of Dercum,<sup>34</sup> of trauma to the frontal lobe, ataxic movements were present, as were also in a similar case of Klien's.<sup>35</sup> These symptoms, however, alone are not diagnostic, but may be valuable when accompanied by other symptoms.

#### CONCLUSIONS.

The following conclusions can be drawn as a result of the studies in this paper:

1. Conjugate deviation of the eyes and of the head is dependent on a most complex mechanism.

2. In the human being there is but one oculomotor center, or at least one active functioning center, situated in the posterior portion of the second and third frontal convolutions, adjacent to the precentral convolutions.

3. A separate center exists for the movements of the head, probably in the lower anterior portion of the precentral convolution.

4. There is probably in man a distinct center for the combined movements of the eyes and head, situated in the area between the head and the eye centers.

34. Dercum: *Jour. Nervous and Mental Dis.*, Feb., 1905.

35. Klien: *Deut. Ztschr. f. Nervenheilk.*, vol. xxvi, 1904, p. 327.



5. It is probable that the cortical oculomotor, head and combined head and eye centers are subdivided for lateral as well as for upward and downward movements.

6. The oculomotor and the motor head centers are in connection by means of association fibers with the cortical centers for the special senses, in the temporal, occipital, uncinata and other lobes.

7. Any lesion in the motor centers for the eyes and head or in the related special sense centers or in the association fibers connecting the former with the latter will cause an impairment in voluntary deviation of the eyes or of the head, or of both, this depending on the nature and location of the lesion.

8. Lesions in the angular gyrus cause conjugate deviation because of involvement of visual and auditory fibers which lie underneath this area.

9. The theory of Bard<sup>1</sup> that conjugate deviation of the eyes and head is always or nearly always accompanied by homonymous lateral hemianopsia and dependent on this is an error, for in the majority of instances hemianopsia does not exist.

10. Hemianopsia may be caused by the shock or transient effects of the hemorrhage, this loss of half vision being only a temporary symptom and similar in nature to the temporary hemianesthesias sometimes observed in capsular lesions.

11. The occurrence of conjugate deviation of the eyes or of the head, or of both, is of no value as a focalizing symptom, because it may be the result of a lesion in any portion of the cerebrum. It may be of value, however, in conjunction with other localizing symptoms.

12. Conjugate deviation of the eyes and head probably occurs in every case of large apoplectic lesions, but in some instances it is a partial or minor form and of transient duration.

13. Paralysis or impairment of associated ocular movement may occur as a result of a hemianopsia. This, however, is only temporary.

14. There is at present no evidence of a center or centers for automatic ocular movements, but if such centers exist in the thalamus a lesion of these should cause forced or incoördinate ocular movements.

15. Convergence and divergence are probably not reflex acts, but associated ocular movements similar to lateral and upward movements. They probably have

cortical centers in the posterior portion of the second and third frontal convolutions. The movements of convergence and divergence are probably brought about by associating tracts in the pons and cerebral peduncles.

AUTHOR'S CASES OF CONJUGATE DEVIATION OF THE EYE  
AND HEAD.

CASE 1.—McL., a woman, aged 60, was admitted to the Philadelphia General Hospital, March 13, 1905, to the service of Dr. Spiller from the out-wards, with a history of a stroke of one day's duration, in the left side.

*Examination.*—The tendon reflexes of the upper limbs seemed to be absent. In the lower limbs the patellar and Achilles jerks were increased, more on the left side, and the Babinski sign was present on this side. Sensation for touch and pin prick was normal. The patient was not wholly unconscious and could respond to questions and would obey commands. A sweetish, urinous odor which suggested a uremic condition was present. The pupils were equal and larger than normal, and the response to light was sluggish on both sides. She could not be tested for accommodation and convergence, and ocular movements because of her mental condition. An occasional tremor was noticed which involved the whole of the left side of the face and the left thumb, this tremor being fine in character. The tremor was at times communicated to the lower part of the right side of the face. Besides, the patient had occasionally a distinct series of convulsive movements which were limited to the left side of the face, the muscles of the face twitching about twice a second, and with this there were twitchings in the muscles of the neck, most marked on the left side, the head being turned to the left with both eyelids closing and opening synchronously with the other contractions. The left thumb was also involved, no movement being apparent in the rest of the hand or of other portions of the body. These convulsions lasted about three minutes, after which the patient would take a long breath as though recovering from an attack of epilepsy.

When examined by me, on the date of death which was five days after stroke, the patient's head was constantly deviated to the left, the eyes deviating to the *right*, there being a constant horizontal movement from the left to the right, the eyes not going past the median line.

*Autopsy.*—No gross lesions were found in the brain. Two depressions were found on the lateral surface of the left cerebral hemisphere which were filled with fluid, one of these depressions occupying the area of Broca, and extending upward into the lower posterior portion of the second left frontal convolution. The other area was in the lower part of the intraparietal fissure. These areas presented the appearance of a pushing apart of the convolutions without the formation of sclerotic tissue. As they were filled with fluid there must have been pressure exerted on the surrounding brain tissue.

CASE 2.—W., a man, aged 60, had been in the Wills Eye Hospital because of glaucoma, under the care of Dr. S. Lewis Ziegler who referred the case to me. He had been blind for the past three years. While walking down stairs he suddenly became unconscious and fell. He was brought back to the wards and had two convulsions, irregular in character. He persisted in this comatose condition for two days, during which time the head and eyes were deviated to the left, but there was no paralysis noticeable in any of the limbs.

*Examination.*—When examined by me two days after his fall the head and eyes were strongly deviated to the left, the eyeballs being in a constant to-and-fro lateral movement, the movement being always from the right to the left and never past the median line. There was a distinct weakness of the lower part of the right face and to a less degree of the right upper limb. The right lower limb was very little if at all involved. Sensation seemed normal; the tendon reflexes on the right side were increased and the Babinski response on this side was obtained. Forcible deviation of the head to the right would cause immediate movement of the head back to the left.

*Clinical History.*—The patient soon became conscious and it was then found that he was motor aphasic, and that he could only answer "Yes, Sir" and the word, "Norah." The paresis of the right limb disappeared almost completely and nothing remained but the weakness in the right lower face, this being also less than it had been at first. The deviation of the head was not so marked, but the deviation of the eyeballs was still as marked as ever. He was then admitted to the University Hospital. Examination seven days after his attack showed almost complete disappearance of the paresis on the right side, including the face. The deviation of the head was entirely absent, but the eyeballs still had a tendency to deviate to the left. Voluntary associated ocular movements were well performed upward, downward and to the left, but to the right he could not bring his eyeballs more than just a little past the median line. Motor aphasia still persisted. It was not until about seventeen days after his attack that he was able to bring his eyeballs completely to the right in associated ocular movements. The motor aphasia was still somewhat present.

*Diagnosis.*—The patient evidently had a hemorrhage in Broca's convolution on the right side, this involving partially the center for movements of the head, and of the eyes in the adjoining posterior portion of the second frontal convolution.

CASE 3.—McJ., a woman, aged 62, was admitted to the nervous wards of the Philadelphia General Hospital, March 28, 1906, in the service of Dr. Spiller.

*Examination.*—She was mentally clear and answered questions logically and would obey commands well. She stated that she had had intense headache, some dizziness, nausea and vomiting for the previous three days. While lying passively in bed the head was deviated to the right and she was unable

to turn it to the left. On a forcible attempt to straighten her head the resistance to the movement was very noticeable. It could, however, be forcibly turned completely to the other side, but would immediately turn to the right. The eyes were also deviated constantly to the right. The patient unquestionably had right homonymous hemianopsia, as she was able to recognize all objects properly on her right side but failed utterly on her left. The pupils were unequal and seemed to react slowly to light. Efforts at convergence in looking to the right could only be tested, and when this was done convergence was normal.

During my examination, which lasted about three-fourths of an hour, the patient had five convulsions which would start as follows: There was first a slow turning of the head from the right to the left; at the same time or perhaps a second later there was an upward movement of the left arm as if the hand was held in gesticulation; the head was now held in violent tonic contraction to the left and the face was drawn to the left, the right face drooping; the eyeballs were in constant contraction to the left and were jerked to and fro violently to the left outer canthus. Almost immediately after the movement of the left upper limb the right upper limb was raised and the body was forcibly turned to the left. The tonic contraction of the left hand and face were now succeeded by a clonic contracture of all the limbs of the body. During the tonic contracture the left angle of the mouth was violently drawn upward, the eyelids were alternately opened and closed on both sides, but about three times as rapidly on the left side as on the right. The convulsions sometimes would start in the left side of the face, or again would start simultaneously in the left side of the face and left arm or the right limb. In the majority of instances, however, the convulsion would start with movements of the left face or the left hand.

There was present also a complete left hemiplegia, flaccid in character. The reflexes were increased on both sides, more on the left. The Babinski reflex was present on this side and not on the right. Sensation for all forms was lost completely over the left side. The sense of position was also lost in the left upper and lower limbs and she was unable to recognize any object placed in the left hand.

She was able to look upward and downward with both eyes equally and well. She could look to the right and when this was done the right eyeball was not brought to the outer canthus by one-fourth inch, the left eyeball, however, was fully deviated to the internal canthus. Associated ocular movements to the left were impossible.

Patient died three days after her admission to the hospital.

*Autopsy.*—Fracture of the cranial bone was found starting at about one-half inch above the ear and extending downward almost to the foramen magnum. The line of another fracture extended from a point between the foramen magnum directly

backward to the right of the lateral sinus. Extensive hemorrhages were found occupying the right frontal pole, this extending in its posterior aspect to the foot of the second frontal convolution and lower part of the precentral convolution. Small hemorrhages were also found involving the right angular gyrus and the right occipital point. Horizontal section of the brain showed the hemorrhage to be cortical in all these points and not involving the white substance in any portion.

CASE 4.—S., adult male, was admitted to Philadelphia General Hospital, Dec. 9, 1902, to the service of Dr. Mills.

Nothing could be obtained of his past history as he was admitted in a stuporous condition and his identity was unknown. A complete left hemiplegia was present. The tendon reflexes were exaggerated, more so on the left side. The Babinski reflex was present on this side. He apparently had a complete left hemiplegia with left hemianesthesia and left hemianopsia. The pupils did not react to light or accommodation on either side. Patient was unable to turn his eyes in associated movements to the right. He died three days after his stroke.

*Autopsy.*—Several large hemorrhages were found involving the greater portion of the right parietal convolution and extending forward beyond the Rolandic fissure into the back part of the frontal lobe and posteriorly in the occipital lobe.

CASE 5.—B., male, aged 60, a weaver, was admitted to the nervous wards of the Philadelphia General Hospital, in the service of Dr. Spiller, April 4, 1903.

*History.*—He had syphilis when 30, but otherwise his past history was of no importance. When admitted to the hospital he complained of weakness and stiffness in both lower limbs which he had had for the previous six months, and also some difficulty in talking and swallowing. There was no history of apoplectic attacks.

*Examination.*—His gait was stiff, his steps were short; station was normal with eyes open and closed; speech was bulbar, it being dull, monotonous and indistinct. He had dribbling of saliva, difficulty in chewing and eating and would even choke. There was no apparent weakness in any of the cranial nerves. The lower portion of the face seemed atrophied, but no tremors were present either here or in the tongue. The upper and lower limbs were weak and spastic, especially the left; all the tendon reflexes on both sides were exaggerated, especially on the left. Ankle clonus was present on both sides and the Babinski reflex was typical on the left and uncertain on the right. Sensation was normal for all forms everywhere. Some atrophy was present on both sides in the thenar and hypothenar eminences, especially on the left side. Some general atrophy was also present.

*Diagnosis.*—The patient was regarded as a questionable case of bulbar palsy; the slow progress and the absence of more

involvement of the cranial nerves and of fibrillary tremors, making the diagnosis of pseudobulbar palsy possible.

*Clinical History.*—The condition of the patient gradually became worse, the bulbar symptoms becoming more marked. Two days before his death he suddenly became unconscious and had convulsions, clonic in character, these being limited entirely to the right side. When examined by Dr. Spiller (who made the following observations) the patient was found in an entirely unconscious condition, paying no attention when his name was called; breathing was stertorous and the right cheek was puffed out as though that side of the face was paralyzed. The right upper and lower limb was raised, and dropped like a flail, and irritation of these parts did not elicit any movement. The reflexes were more exaggerated on the right side and this side was more spastic. The Babinski response was prompt on each side. The head and eyes were deviated to the left. If the head was forcibly turned to the right it would soon forcibly turn back to the left. Slight irregular lateral jerkings of the eyeballs were present. The right pupil was larger than the left and the reaction of the iris to the light was slightly present. The deviation of the head and eyes persisted until the following day, when the patient died.

*Autopsy.*—The case proved to be one of pseudobulbar palsy, as a scar of an old hemorrhage was found in each lenticular nucleus. Besides, a recent hemorrhage was found in the left occipito-temporal region extending to the cortex. This hemorrhage was in the posterior portion of the first and second left temporal convolutions and just below the angular gyrus. The area involved was 4. cm. deep, and 1.2 cm. in its greatest width.

CASE 6.—G., a woman, aged 80, a domestic, was admitted to the nervous wards of the Philadelphia General Hospital, Oct. 12, 1905, in the service of Dr. Mills. Nothing was known either of the family or of past history. She was admitted from the out-wards with a history of suddenly developing numbness of the left hand, followed by pain and convulsions limited to the left face and hand and weakness in these parts.

*Examination.*—When examined by Dr. McConnell, the patient showed a distinct weakness of the lower part of the left face and of the left upper limb, this weakness in the limb being more marked in the distal parts. The other limbs were not involved. Sensation for touch and pain were normal everywhere. The reflexes in the left upper limb were exaggerated, but the other parts were normal. During the examination the left side of the face and the left hand were the seat of intermittent convulsive movements, the head being drawn somewhat to the left and the left angle of the mouth upward and outward, closing both eyelids and wrinkling the brow, with dilatation of the left nostril. The left platysma muscle was also in contraction. There was no movement of the eyeballs during the convulsion (Dr. McConnell was positive of this, for he observed her especially with this purpose in view). The convulsion

would last for two minutes and did not involve any other portion of the body. The patient was perfectly clear in mentality during the attacks and would answer questions and obey commands directly after the convulsions were over.

Examination of the eyes showed the pupils to be moderately dilated and round, the response to light and accommodation being normal. The left ocular and palpebral conjunctivæ were greatly inflamed. Associated ocular movements upward and to the left were greatly impaired, being in fact almost entirely lost, the loss of upward movement being more marked in the right than in the left eye. The paralysis of associated ocular movements persisted until her death, which occurred four days after her admission to the wards.

*Autopsy.*—An area of softening was found in the middle of the right precentral gyrus, this softening extending downward as far as and not involving any of the frontal convolutions. A fresh hemorrhage was found in the posterior portion of the occipital cortex, this hemorrhage being 2.5 cm. from the occipital bone. It was 2.5 cm. wide and 2. cm. deep, extending into the white matter and possibly involved the outer part of the optic radiations. The hemorrhage was posterior and inferior to the angular gyrus and very close to it.

Dr. Mills recorded the complete history of this important case before the American Neurological Association, in Boston, June 4 and 5, 1906, in a paper entitled, "Focal Encephalitis."

CASE 7.—McC., a woman, about 50, a patient of Dr. Crothers, of Chester, was seen in consultation by Dr. Mills and myself.

*History.*—Some notes were obtained from one of her relatives who had been with her constantly for a year or two. This relative stated that the first symptom of which the patient complained were flashes of light which she always saw from the left side. Later the niece observed that she would stumble against objects which were placed on the left, as the left side of the door through which she was passing. This tendency grew worse as time went on and probably indicated a left homonymous hemianopsia. She began to suffer from agonizing headaches, and still later developed nausea and vomiting. It was not until nearly a year after the visual symptoms appeared that she began to develop weakness in the left arm and leg.

*Examination.*—When she first came under observation patient had a left hemiplegia, the limbs being somewhat contracted. The tendon reflexes were prompt on both sides, but more so on the left, and the Babinski response was present on this side. The patient's mentality was not of the best and it was impossible to tell the state of the sensation. The associated ocular movements were normal to the right and downwards; upward movements were limited, but associated ocular movement to the left was impossible. The pupils were equal and the iritic reflexes were normal.

Eye examination by Dr. C. I. Stiteler showed vision, O. D., 5/9; in O. S., 5/12. The pupils reacted normally, the media

in O. D. was slightly hazy and the outline of the nerve head could clearly be seen only at the upper temporal border, the rest of the nerve being very indistinct and somewhat swollen, especially at the lower border where the margin could not be seen. The retinal vessels were enlarged. In O. S., the media was slightly hazy; the nerve head was normal.

*Operation.*—There were besides, intense headaches, and some nausea and vomiting. Because of these symptoms of brain tumor an operation was decided on in the motor area. After the operation the patient became considerably better and lived comfortably for two months. In this period homonymous hemianopsia (left lateral) was clearly apparent. Dr. Crothers, under whose care she was, stated that she would never voluntarily look to the left, but that she could look upward, downward and to the right normally; but that towards the last he was able to get her, after violent effort, to look to the right.

*Autopsy.*—A large tumor was found filling up the whole of the right occipital lobe, extending very nearly to the surface but not breaking into the cortex. The convolutions and fissures over this tumor were much flattened. The tumor extended to the posterior part of the corpus calossum and displaced forward the structures anterior to this. Just at the anterior border of the tumor the wound made by the surgeon at the time of the operation could be found. The angular and supra-marginal gyri were involved in the tumor.

CASE 8.—H., woman, aged 60, a cook, was admitted to the Philadelphia General Hospital, Dec. 15, 1904, in the service of Dr. Mills.

*History.*—Five days before admission to the hospital the patient suddenly became unconscious and developed a complete right hemiplegia.

*Examination.*—She was unconscious on admission; the paralysis on the right side was complete and flaccid in character. The reflexes on each side were diminished, but the Babinski reflex was present on the right. The patient soon recovered consciousness and was able to obey commands; sensation was not disturbed and there was no hemianopsia. Motor aphasia was well marked. The following notes were made by Dr. Pemberton, the resident physician: "The right pupil is contracted and apparently immobile to light. The left pupil is dilated and fixed. The media of both eyes is very cloudy, especially the left, which shows a cataract and a marked arcus senilis; accommodation seems to be impossible. The patient looks straight ahead and she cannot apparently move her eyes in any direction when told to do so, although she evidently understands commands and makes an effort to obey, as shown by slight turning of the head."

The patient died nineteen days after the appearance of the apoplectic symptoms.

*Autopsy.*—A thrombus of the left middle cerebral artery was found, with softening of the brain in the precentral, postcentral



and the whole of the parietal convolutions, that is, in the area supplied by the middle cerebral artery. The softening extended to the lenticular nucleus, but did not invade it, as the thrombus was beyond the point where the arteries to the basilar ganglia arise. The posterior portion of the second frontal convolution was not involved.

CASE 9.—H., a woman, aged 70, was admitted to Philadelphia General Hospital, June 23, 1903, to the service of Dr. Spiller, with a history of right hemiplegia, one day in duration.

*Examination.*—The paralysis on the right side was complete and flaccid in character. The patient was stuporous and could not be aroused. The reflexes were diminished, this being more so on the paralyzed side. The Babinski reflex was obtained on the right side; not on the left. Pin prick seemed to be perceived on the paralyzed side, as shown by the movements of the opposing limbs. There was decided conjugate deviation of the head and eyes to the left. When the tongue was protruded it was also protruded to the left.

**Patient died eight days after her stroke.**

*Autopsy.*—A recent hemorrhage was found in the left optic thalamus, destroying the greater part of the thalamus and extending into the posterior limb of the left internal capsule, but apparently not invading the lenticular nucleus or involving the optic radiations.

CASE 10.—H., a tailor, aged 80, was admitted to Philadelphia General Hospital, March 6, 1906, from the out-wards, to the service of Dr. Spiller.

*Examination.*—A complete right hemiplegia was present, the paralysis being flaccid in type. The tendon reflexes were increased on the right side and the Babinski response was prompt. On the left side the reflexes were normal. Pin prick was not recognized on the right side, but on the left side any irritation would cause prompt movement. It was impossible to tell whether hemianopsia was present. There was also incontinence of urine and feces. The patient's head was deviated to the left and when it was forcibly turned to the right or to the median line it was immediately turned back to the left. There was also a conjugate deviation of the eyes to the left.

Examination two days later showed practically the same condition, the deviation of the head and eyes being as marked as when examined the first time. There were present besides, constant horizontal movements of the eye, this being perceived with the eyes open, and also when they were shut, the movements being transmitted to the lids. These lateral movements were also to the left. Irregular and jerking movements were also present in the left limbs. Examination two days after this and six days after his stroke, still denoted the same condition, the head not being deviated so strongly. The deviation of the eyes, however, was as marked as ever. Any movements of the head would always be to the left and never to the right, no matter where the irritation was made. The pupils were small and equal; the light reaction was normal. All movements of

the eyeballs were to the left and not to the right. The patient died seven days after his stroke.

*Autopsy.*—A recent large hemorrhage was found filling up the posterior horn and descending horn of the left lateral ventricle, but not into the anterior horn, and also involving a large part of the lenticular nucleus, doubtless disturbing the function of the left optic radiations and involving also the posterior limb of the internal capsule and the optic thalamus.

CASE 11.—D., a man, aged 52, with a history of syphilis and alcoholism, was admitted to the nervous wards of the Philadelphia General Hospital, Sept. 17, 1902, in the service of Dr. C. S. Potts, to whom I am indebted for the material of this case. A day before his admission the patient had an apoplectic attack, with a resulting left hemiplegia.

*Examination.*—The paralysis was complete and flaccid, the tendon reflexes were not exaggerated on either side, but the Babinski response was obtained on the left side. A hypesthesia for touch and pain was apparently present in the paralyzed side. The patient had conjugate deviation of the eyes to the right, with inability to turn the eyes to the left.

*Autopsy.*—An area of softening was found in the lenticular nucleus of the right side, and extending into the posterior limb of the internal capsule, but not invading the optic radiations.

CASE 12.—R., a man, aged 77, was admitted to the nervous wards of the Philadelphia General Hospital, July 19, 1904, in the service of Dr. Spiller.

*History.*—A sudden attack of unconsciousness the day before, resulting in a left hemiplegia.

*Examination.*—On the following day examination showed a complete left hemiplegia, the paralysis being flaccid. The tendon reflexes were lost on the paralyzed side and were diminished on the sound side. The Babinski response was obtained on the left side. Pin prick was not recognized at any portion of the left side, but was promptly recognized on the right side. The patient was not totally unconscious, as he would obey commands, as sticking out his tongue and lifting up his limbs of his sound side. There was also present incontinence of urine and feces. The eyes were distinctly deviated to the right, but there was no deviation of the head. It was impossible to tell if hemianopsia was present.

The patient died six days after his stroke.

*Autopsy.*—A large hemorrhage was found destroying the posterior portion of the right lenticular nucleus, extending backward beyond the nucleus almost to the angular gyrus and destroying the posterior part of the posterior limb of the internal capsule. This large hemorrhage did not involve the cortex at any point, although in one part minute hemorrhages were found in a portion of the cortex about the island of Rheil.

CASE 13.—S., a man, aged 51, was admitted to the Philadelphia General Hospital, Sept. 21, 1903, into the service of Dr. Mills.

*History.*—He had been admitted to the hospital several years previously with a history of right hemiplegia, from which he partially recovered.

After being in the hospital for two years he suddenly had an attack of unconsciousness. The resident physician, Dr. Maier, found him in a stuporous condition, the right arm and leg being completely paralyzed and the right face drooping. Some spasticity was present on this side and the reflexes were exaggerated. The head was not deviated to either side; the eyes were turned up and oscillated slightly from the right to the left. He died two days afterwards.

*Autopsy.*—A lesion was found in the left lenticular nucleus not extending apparently into the internal capsule, and reaching and invading the claustrum, extreme capsule and not reaching the cortex. The lesion must have involved the fibers underneath the angular gyrus.

CASE 14.—A. was an old right hemiplegic, who had for a long time been in the nervous wards of the University Hospital. His previous records were lost.

One morning he suddenly became unconscious and had convulsions, which were limited to the left upper and lower limbs and the left side of the face. The eyes were turned in conjugate deviation to the right. Both upper and lower limbs were flaccid, there being, however, more tonicity in the left side. The tendon reflexes were lost in all the limbs, but the Babinski response was distinct on the right side. The patient died the same day.

*Autopsy.*—The ventricles were found to be considerably dilated and the scar of an old cyst was found in the external portion of the left lenticular nucleus and involving the extreme capsule.

CASE 15.—C., a woman, was admitted to the nervous wards of the Philadelphia General Hospital, July 12, 1904, into the service of Dr. Spiler.

*History.*—The patient then had a paresis on the left side of the body. Feb. 22, 1905, she suddenly became paralyzed, about seven months after her first stroke.

At this time Dr. Spiller made the following dictation: "The patient is in a deep stupor and is unable to understand anything said to her. The eyeballs are deviated to the right and there are frequent irregular jerky movements to the right, the left edge of the cornea going but very little beyond the median point of the palpebral fissure during these movements. These clonic movements of the eyeballs are suggestive of an irritation of the left cortical center of the ocular muscles."

When she was seen by Dr. Pemberton, the resident physician, somewhat previously, but on the same day, the eyes were turned to the left, and there were no jerky movements of the eyeballs. She had therefore conjugate deviation of the eyes to the left, but this was at the time when there was no irritation of the eye muscles, and therefore would seem to indicate

that she was looking at her lesion. The head was not stiff and remained where placed; there was also a slight tendency of the eyeballs to be drawn upward as well as to the right. The pupils were dilated, and equally so, and did not respond to light. Occasionally an involuntary jerking of the left upper limb was observed. Both upper and lower limbs were flexed and the reflexes were diminished, the left more than the right. Babinski response was present on the left but not on the right. She died the following day.

*Diagnosis.*—Left hemiplegia.

*Autopsy.*—A limited area of sclerosis of the anterior portion of the right second frontal convolution was noted. There was also a cyst in the anterior portion of the left lenticular nucleus. An area of softening in the right frontal lobe at the frontal point was found. The lateral ventricles were also somewhat dilated.

CASE 16.—C. a woman, aged 35, was admitted to the Philadelphia General Hospital, Dec. 1, 1905, to the service of Dr. Hirst.

*History.*—Patient was delivered of a child four weeks previously, since which time she had been having a temperature and had apparently been septic. Two days before her admission she suddenly fell, became unconscious, and has not been able to speak since.

*Examination.*—She was examined five days after her admission by Dr. McConnell and myself. The patient then had a complete right hemiplegia, the limbs on the paralyzed side being spastic and contracted in the usual hemiplegic position, the reflexes were exaggerated on both sides, the right more than the left, and the Babinski response was present on this side. The patient was not unconscious and would obey commands. The head and eyes had been deviated since her admission constantly to the left. Pin prick or touch on the right side could not be recognized anywhere, but on the left side sensation was promptly recognized. Objects were not recognized in the right visual fields of either eye, as was demonstrated by the feeding cup and other tests, therefore, right homonymous hemianopsia was present. The patient was aphasic, but could understand questions and would nod responses. The right masseter muscle was in a constant state of contraction, causing the right jaw to be locked. She was able to turn her eyeballs upward, downward, and to the left, but could not turn them to the right. When examined a day after this the patient could turn her eyes a little to the right, but not normally so. She died a few days afterwards as the result of a double pneumonia.

*Autopsy.*—An area of red softening was found, involving the left caudate and the left lenticular nucleus. A small hemorrhage was also found in the cortex of the upper portion of the first temporal convolution just below and anterior to the angular gyrus.

THE SIGNIFICANCE OF JACKSONIAN EPILEPSY  
IN FOCAL DIAGNOSIS, WITH SOME DISCUS-  
SION OF THE SITE AND NATURE OF THE  
LESIONS AND DISORDERS CAUSING THIS  
FORM OF SPASM.\*

BY CHARLES K. MILLS, M.D., PHILADELPHIA.

*Professor of Neurology in the University of Pennsylvania; Neurologist to the Philadelphia General Hospital, and Consultant to the Philadelphia Orthopedic Hospital and Infirmary for Nervous Diseases.*

WITH the exception of monoplegia or hemiplegia, probably no single symptom or symptom complex is so often made use of by the diagnostician in his efforts to fix the site of a tumor for the purpose of operation as Jacksonian epilepsy. This term is used here in a broad sense as meaning monospasm or hemispasm due to cortical or cortico-subcortical discharge, a spasm which usually exhibits, if closely studied, an initial symptom and a serial order of phenomena. As originally and as commonly employed, the mere use of the term is supposed to predicate the existence of a focal lesion of the motor cortex, and it is sometimes defined as a spasm limited to a single group of muscles, or at least to a few muscular groups. Irritation or instability of portions of the cerebral

\* Read before the New York Academy of Medicine, April 19, 1906. From the Department of Neurology, University of Pennsylvania.

motor area, in by far the largest number of cases of Jacksonian spasm as here defined, is a direct or indirect cause of this form of epilepsy, but it is by no means true that it is always or even nearly always due to gross lesion of the motor zone. The greatest care should, therefore, be taken not to attribute to local spasm erroneous diagnostic value. While in many cases it is a most important guide, in others it may be misleading.

A distinction needs sometimes to be made between Jacksonian epilepsy and hemi-epilepsy. Some of the cases of hemi-epilepsy belong in the Jacksonian category, but they are not all to be relegated to it. The convulsive attacks following hemiplegia are frequently unilateral, but they may begin on the paralyzed side and become general. Occasionally they are confined to a portion of one side of the body. Frequently, probably usually, they are of cortical origin. When as is so often the case, the hemiplegia, especially in childhood and youth, is due to softening from thrombosis, the convolitional areas surrounding or in the neighborhood of the parts destroyed are often the seat of deep congestion and punctiform hemorrhages. These render the cortical centers unstable and convulsive discharges ensue, which may be confined to the limbs and face of one side, may be unilateral

or may become general. The monospasm or unilateral convulsions which occur in cases of this description sometimes simulate very closely those which are due to brain tumor in the motor cortex or subcortex. They have the same mechanism as the Jacksonian spasms of tumor or other lesion, namely, irritation or instability of cortical motor cells. Hemi-epilepsy may, however, in some instances be due to an irritative lesion well removed from the cortex or to some toxic state.

It is scarcely necessary to present, as could easily be done, a large number of cases in which Jacksonian spasm has been an important or a deciding symptom in successfully fixing the site for operation in the case of a cerebral tumor. Many such cases have been recorded, and not a few by the writer. I shall refer only, and that briefly, to the histories of a few such cases.

Dr. C. H. Frazier, May 2, 1903, operated successfully for tumor of the motor region in a case under the care of Dr. Wm. G. Spiller,<sup>1</sup> which was seen by me in consultation. This case had the typical features of a neoplasm of the motor region, including Jacksonian spasm. The patient was a motor aphasic and agraphic with paresis of the right side of the face, right

<sup>1</sup> Spiller, Wm. G.: A Report of Five Cases of Tumor of the Brain, with Operation. *The American Journal of Medical Sciences*, February, 1904.

arm and right leg, exaggerated reflexes, and most of the general symptoms of brain tumor. Sensory symptoms were absent. He had had frequent attacks of spasm confined to the right side of the body, chiefly to the face and arm. According to the notes of the case, he always knew when these attacks of spasm were coming on by a twitching in the right eye for about five minutes before the spasms developed. The attack began by a peculiar sound in the throat, the eyeballs then rolled about, and the right arm and hand became implicated in the convulsive movements. Sometimes the right lower limb was affected, but never the left side. Consciousness was not lost, and the man did not fall into sleep after the convulsions. The attacks occurred usually when the man was awake, but several times when he was asleep. The convulsions lasted about three minutes, sometimes longer.

I have had under observation a number of cases of cyst of the motor region in some of which unilateral convulsions or monospasms have been present, these being evidently due to the unstable condition of the cortex surrounding the cyst. In several such cases Dr. C. H. Frazier has operated, exposing the cyst, and in some instances cutting away its roof with some benefit in the direction of lowering the frequency and severity of the attacks.



A tumor largely limited to the motor region was removed by Dr. W. W. Keen from a patient seen by me in consultation with Dr. M. Behrend and Dr. Keen. This patient's symptoms began with weakness in the left upper extremity about eight months before the operation. She had an attack of vertigo with monospasm about six or seven weeks before operation. She gradually developed almost complete paralysis of the left upper extremity. She had absolutely no power in the limb below the elbow. The left lower extremity was also almost completely paralyzed. The knee jerk and the deep reflexes on the left side were all exaggerated. Ankle clonus was persistent. The same reflexes on the other side were prompt, but not abnormal. The Babinski response was present on the left; on the right the plantar response was prompt, but not abnormal. Examination made for sensation showed no sensory loss or impairment.

The Jacksonian spasm from which this patient suffered was observed in one attack by a trained nurse who reported that the spasm began in the arm by a lifting movement of the entire limb, and quickly extended to the hand and leg, and sometimes to the left side of the face. The operation was osteoplastic and was so planned that the opening included an exposure of the brain two thirds in front and one third behind

the central fissure. A large sarcomatous tumor was successfully removed, the patient making a good recovery. This case, which I give only in its broad outlines, although reported to one or two societies, has not been hitherto published.

In one case of tumor of the motor region seen by me in consultation with Dr. T. C. Potter and Dr. Wharton Sinkler, the growth after accurate localization, was removed by Dr. Wm. J. Taylor.

The patient had no objective sensory symptoms although she at times complained of a numb feeling in the left side of the face, left arm and left leg, which were paretic, the loss of power being marked in the lower extremity. She had several convulsive seizures, chiefly affecting the limbs of the partially paralyzed half of the body. All the deep reflexes on the left side were increased, persistent ankle clonus being present. The Babinski phenomenon was elicited on the left side. Headache was not conspicuous, but vomiting occurred, and double optic neuritis was present.

One of the most interesting of my motor region cases was that in which successful operation was performed by Dr. W. J. Hearn at the Philadelphia Hospital, Oct. 21, 1902. This was a case of localized pachymeningitis and gumma of the cortex. The patient was a man twenty-seven years old, who had been struck in the left parietal

region eleven years previously and who also probably had syphilis. Vertigo, headache, vomiting and optic neuritis were all marked symptoms during the development and progress of the case. His chief symptoms just before the operation were, extreme pain in the left parietal region, frequent spasmodic seizures beginning in the right hand and arm, and later involving the right leg and right side of the face, with temporary loss of power in the right arm and leg after the seizure. Tenderness was extreme over the left parietal scar and over the surrounding region for a distance of three inches or more. Grip in the right hand was slightly impaired. Sometimes immediately after a spasm loss of power in the right arm and forearm was marked. Biceps jerk in both arms was slightly increased, but triceps jerk was normal in both. Tactile, pain, and thermal senses and stereognostic conception were normal. Voluntary and resisted movements in the right leg and foot were slightly impaired. Knee jerks were exaggerated on both sides, more markedly on the right. Ankle clonus was present on both sides. The Babinski response could not be obtained on either side.

In connection with these cases on which operation was performed, and several of which have been published in detail, I am able through the courtesy of Dr. C. W. Burr and Dr. R. L. Lavenson,

to present the notes of an unusual case of Jacksonian epilepsy due to small cortical lesion. It will be seen that this patient had for a long time a continuing clonic spasm of the upper extremity, preceded by a marked Jacksonian spasm with unconsciousness. For a time the clonic spasm was intermittent. A few similar cases have been reported under the title of *epilepsia continua*. This interesting case will later be published in full. The following are notes furnished by Dr. Burr:

“ The patient was a woman, fifty-five years of age, who, four years after amputation of the breast for carcinoma, began to have convulsive twitchings in the left arm. At first the spasm continued for a few minutes to a half hour and would recur from ten to twenty times a day. About a week later quite violent convulsive movements commenced and were persistent. They decreased but did not cease during sleep. There were flexion and extension of the fingers, and flexion and pronation of the forearm. If the muscles were tapped the spasm increased greatly. Voluntary movement in the arm also increased the spasm. There was only slight loss of power. The patient did not complain of the left leg at all. On examination, however, there was seen a coarse, persistent, clonic, spasmodic tremor. She was able to walk and there was no palsy of the leg.

The left knee jerk was increased, the right normal. There was no ankle clonus, no Babinski sign. She had no headache or vomiting. Once, before the spasm became persistent, the patient had a localized fit with unconsciousness, following which there was loss of power and sensation in the arm for a few minutes. This was the only time in which the sensation or consciousness was affected.

“The brain showed the following: The whole organ was somewhat atrophied. In the ascending frontal convolution of the right side, at about the hand center, was a spheroidal tumor about one third of an inch in diameter, arising from the pia and deeply compressing the cortex so that the tumor was buried in a socket. On microscopic examination it proved to be a carcinoma. There was another small tumor about the same size in the pia on the inferior surface of the left lobe of the cerebellum. I do not think that the latter had anything to do with the symptoms.”

These cases have been given, omitting many details, to show the importance of Jacksonian spasm in gross lesions of the cortex, especially in tumor and localized meningitis. In such cases a few features would seem to point with comparative certainty to gross lesion. In these and in a large number of similar cases, other

evidences of gross lesion in addition to the spasm were present. They were chiefly monoplegia or hemiparesis with exaggerated reflexes on the side of the body in which the localized spasm occurred. In most cases close investigation of the conditions of motility and of the reflexes shows this persisting impairment of power and abnormality of reflexes.

So important is this question of Jacksonian epilepsy in the focal diagnosis of brain tumors, that it will be advisable to consider at length the seat and nature of various lesions and conditions producing this symptom. The diagnostician must bear in mind (1) that tumors situated in other parts of the brain than the motor cortex may cause Jacksonian epilepsy; (2) that other lesions besides tumors situated in the motor cortex may cause this form of spasm; (3) that it may occur in toxic and other disease in which no demonstrable focal lesions are present; (4) that a spasm closely counterparting the Jacksonian type may be observed as a reflex or a hysterical disorder; and (5) that Jacksonian epilepsy may be simply an integral part or the entire expression of a case of idiopathic epilepsy.

Jacksonian epilepsy due to cortical discharge may occur as the result of tumors in other parts of the brain than the motor zone. The irritation owing to its intensity, spreads to the motor

cortex. It is probable also that in some of these cases unusual instability of the motor cells plays some part. Cases of this kind, in which the lesion is in the cerebrum proper, and absolutely outside of the motor zone are comparatively rare, and the focal diagnosis can only be made in them by a full consideration of the non-motor symptomatology.

These cases in which Jacksonian epilepsy is a so-called distant symptom are not to be confounded with the comparatively common cases in which the spasm is an invasion symptom. A midfrontal or even a prefrontal tumor not infrequently invades caudally until the motor region is grazed or implicated, Jacksonian spasm of typical form showing itself after psychic, graphic and speech disorders have become prominent. In these cases, if the tumor be meningocortical in position, spasm may precede paresis or paralysis, although sooner or later, in accordance with the amount of pressure or destruction of the motor region, the patient will become monoplegic or hemiplegic. Tumors invading backwards from the prefrontal towards the motor region are, in my experience, much more likely to cause Jacksonian epilepsy than those which originate in the parietal lobe and advance forwards. I have recorded several cases of parietal tumor in which the motor cortex

and subcortex were invaded and in which Jacksonian epilepsy was not present even at a late stage of the disease. Destruction of the sensory cortex and subcortex, before involvement of the motor projection fibers or cortex, would seem to give a certain immunity from such spasm. A case beginning and continuing for some time with such symptoms as cutaneous hypesthesia, ataxia of the upper extremity and loss or impairment of the muscular sense and of stereognostic conception, frequently has paresis and then profound paralysis among its later or terminal symptoms, but this is not often accompanied by Jacksonian spasm.

In some instances, Jacksonian epilepsy, apparently of the usual motor area type, is observed in tumors of the cerebellopontile angle or of the cerebellum. In two cases which have come under the writer's observation, cerebellopontile tumors caused Jacksonian epilepsy or what appeared to be this affection. The first of these cases has been reported in detail by Dr. T. H. Weisenburg.<sup>2</sup> The tumor sprang from the eighth nerve, and the chief focal symptoms were one-sided deafness, tinnitus, facial monospasm, hypesthesia of one

<sup>2</sup> Weisenburg, T. H.: *New York Medical Journal and Philadelphia Medical Journal* Feb. 11 and Feb. 18, 1905. This paper is one of a series of contributions by Drs. Mills, Frazier, de Schweinitz, Weisenburg and Lodholz, published in the above numbers of the *New York Medical Journal* and reprinted in a monograph on *Tumors of the Cerebellum*.



side of the face, nystagmoid movements, slight paresis of the right abducens, and vasomotor and cardiac disturbances. Severe headache, nausea, vomiting and optic neuritis were also present. I examined this patient many times and on several occasions witnessed the facial monospasm which usually showed the same features. In this spasm the mouth was drawn as far as possible to the left and the eyelids were brought together. Only the left side of the face was involved in the seizure. On one occasion it was thought that the facial spasm was accompanied by some spasmodic movements of the left hand, but this was doubtful, and even the observer thought it may have been a voluntary movement.

In a second case seen by me recently,<sup>3</sup> one in which a tumor was successfully removed by Dr. John H. Gibbon from the cerebellopontile recess, Jacksonian epilepsy, or at least facial or facio-brachial spasm, was one of the most striking features in the symptom complex. In this case the general symptoms of brain tumor, including headache, vertigo, nausea and vomiting, and optic neuritis with atrophy were present, the chief focal symptoms being deafness in one ear, and on the same side facial and abducens paresis

<sup>3</sup> This case will later be published in detail by Dr. John H. Gibbon and the writer.

with nystagmoid movements and the spasm above described. In the convulsive seizure the face was markedly drawn to the left, and the spasm in some instances passed to the arm and hand of the same side. Spasmodic attacks occurred at intervals for several months. In at least one or two of them observed before the operation tonic spasm involved both sides of the body.

Some discussion was had as to whether this case could be a prefrontal one invading the face and arm areas, or, as it proved to be, a cerebello-pontile growth. The diagnosis was not as easy as might at first sight appear, as abducens paralysis occurs in tumors variously situated; and at first there was some question as to the central origin of the deafness. Decision was finally given, however, in favor of the cerebello-pontile angle, and the operation was the most successful which has as yet been performed for a tumor situated in this locality.

Collier<sup>4</sup> calls attention to two cases in which a tumor of the cerebellum caused Jacksonian attacks. Local convulsion of slow spread and confined to the arm and face was repeatedly observed. Some bilateral spasticity was present in these cases. No lesions except the cerebellar

<sup>4</sup> Collier, James: *The False Localizing Signs of Intracranial Tumor*. Brain, part iv, 1904.

tumors were present, but the ventricles were considerably distended. Hemi-epilepsy is noted by Collier as having occurred in one case of tumor of the pons and in one case of tumor of the cerebellum. General convulsions occurred in other cases. Collier is inclined to attribute the local spasms, in some cases at least, to hydrocephalus. He warns against confounding Jacksonian spasms of ordinary type with Hughlings Jackson's lower level fits. Grainger Stewart and Gordon Holmes<sup>5</sup> direct attention to this point in the same number of *Brain* as that in which the article by Collier appears.

In considering Jacksonian epilepsy in its relations to the focal diagnosis of a cerebral tumor, the question of spasm due to dural irritation must not be overlooked, especially as certain forms of neoplasm commonly grow from the inner surface of the dura. Convulsion, local or general, due to intense dural irritation may occur as one of the symptoms of a brain tumor situated anywhere within the cranial cavity as has been demonstrated by clinicopathological observation corroborated by physiological experiment. Galvanization or faradization of the dura sometimes causes intense and generalized convulsive attacks. On two occasions I have

<sup>5</sup> Stewart, T., Grainger and Holmes, Gordon: Symptomatology of Cerebellar Tumors, A Study of Forty Cases. *Brain*, vol. xxvii, 1904.

seen such spasms produced by faradic applications to the dura while tests were being made during operation. The experimental investigations in this field are well known. One point of distinction between cortical Jacksonian spasm and the convulsive affection due to dural irritation is that in the latter the spasm, if observed at the start, will be found usually to begin in the face or limbs of the side of the irritation, spreading however rapidly to both sides of the body; so rapidly that the initial spasmodic phenomena may pass unobserved. The spasms almost always become generalized, and tonic spasticity is prominent. Such spasms are really reflex in character, the irritation being transmitted to the bulbar centers of the same side, and thence to those of the opposite side. In addition to the peculiarities of the spasm just noted, the diagnosis from cortical Jacksonian epilepsy will, of course, have to be made by the other focal symptoms present, as by those indicating parietal, occipital, temporal or midfrontal disease.

In some cases in which tumors grow from the agglutinated dura and pia in the motor region, a confusing picture of more or less generalized convulsions is presented. I have seen such cases in which it was possible, especially with after-knowledge, to pick out that part of the spasmodic outbreak which was due to irri-

tation of the motor cortex, and that which was dependent on dural irritation.

The nature of the lesion of the motor area causing localized spasm next requires attention. That other lesions situated in the motor cortex besides tumors may cause Jacksonian epilepsy is, of course, well understood, but the fact is not always given as full consideration as its importance demands when the question of operation is under discussion. Decision as to the nature of the irritative lesion is particularly difficult in those cases, not inconsiderable in number, in which such general symptoms of brain tumor as persistent headache and optic neuritis are absent. I have known both of these to be absent in tumors of considerable size, while vertigo and nausea and vomiting have been so little marked as not to direct decided attention to their probable cerebral origin.

The gross lesions of the motor area which cause monospasm or hemispasm, counterparting that produced by neoplasm, are, (1) depressed fractures; (2) localized meningitis; (3) meningeal or cortical hemorrhage; (4) focal hemorrhagic encephalitis or cortical polio-encephalitis; (5) focal necrosis occurring from embolism or thrombosis, including cases associated with generalized arteriosclerosis.

It would, of course, only be in the case of an

old fracture of the inner table with slight or no outward evidences of the traumatism, that the mistake would be likely to be made of holding that Jacksonian spasm was due to a tumor. It occasionally happens that an injury to the head which leaves only a small scar in its wake results after a considerable time in the development of Jacksonian spasm. Usually in such cases both headache and vertigo, more or less severe and persisting, are present and a tumor may at first be inferred. Close investigation into the history of the case and as to evidences of injury will usually clear up the diagnosis. A mistake is not necessarily of serious import in such a case, as tumors sometimes develop at the site of old injuries, and in any case operation is indicated for the relief of the lesion causing the irritation. Localized meningitis with adhesions or even an abscess may, of course, occur at the site of such a traumatism.

With regard to localized meningitis not of traumatic origin, and not connected with neoplasm, this is usually of syphilitic origin. The case referred to in which Dr. Hearn operated successfully was one of localized pachymeningitis, or rather of conjoint gummatous inflammation, of the dura and pia arachnoid with exudate of sufficient extent and consistence to constitute a tumor mass. It is in this form

of gummatous meningitis, more or less amenable to active specific treatment with mercury and the iodides, that too hasty decision in favor of operation is occasionally given. On the other hand, operation is undoubtedly indicated in some cases with a syphilitic history and with clear evidences of vascular and meningeal specific disease, but in which the case does not respond even to the most energetic medicinal treatment. In some of these cases occlusion of vessels takes place and deposits become organized so that they cannot be influenced by absorbent remedies, and the lesion, although at first simply an active localized meningitis, becomes an inert and irritating mass which should be dealt with by the surgeon.

Little needs to be said about Jacksonian spasm due to meningeal or cortical hemorrhage in connection with our study of the focal diagnosis of brain tumors. Supradural and subdural hemorrhages are so constantly due to traumas, and their symptoms so frequently acute in onset, that the spasm which is sometimes present in the subdural variety, and may be largely confined to one half of the body, is not likely to be confounded with the spasm of a brain tumor. The diagnosis will be decided by the history of the case and by the well-known phenomena of dural hemorrhage, such as con-

tralateral paralysis, dilated pupil on the side of the lesion, varying conditions of consciousness, and peculiar changes in pulse, temperature and respiration.

Cortical hemorrhage of slight depth and irregularly distributed sometimes occurs in cases of sinus and venous thrombosis. Horsley<sup>6</sup> has reported a case of this sort in which Jacksonian spasm clearly defining certain subareas of the motor zone was the most characteristic symptom. In such a case the history of acute or subacute onset, and the symptoms of sinus and venous thrombosis would guide. A hemorrhage or a cyst remaining after a hemorrhage from one of the branches of the medicerebral artery may give rise to Jacksonian epilepsy and other symptoms simulating somewhat those of a tumor. The diagnostician is usually not called upon to differentiate in such a case until weeks, months or years have elapsed after the original lesion, and as the history is sometimes imperfect or confusing, and as the patients who suffer from such attacks are usually victims of arteriosclerosis, they may have some headache and vertigo, which may be regarded as general symptoms of a neoplasm. Associated with the paresis or paralysis commonly present in such cases, may be recurring Jacksonian seizures. Close study

<sup>6</sup> Horsley, Victor: *Ibid.*, April, 1888.



of the clinical phenomena will, as a rule, be sufficient to throw the weight of opinion in such cases against tumor or localized meningitis.

A rare form of cortical disease which causes Jacksonian epilepsy and may be regarded as a tumor of the motor zone in an early stage of its development is focal hemorrhagic encephalitis. Such cases are now and then observed, both in children and in adults. Recently a case of this kind died in my wards in the Philadelphia General Hospital. The patient was an aged woman, who had a number of carefully observed Jacksonian spasms involving the arm and face. Consciousness was retained in the convulsive attacks. The different parts of the arm and face were usually involved in about the same order. The hand, for instance, was drawn somewhat to the left, and the angle of the mouth was drawn outwards and upwards; the eye was closed and the brow wrinkled, but without any frowning movement or movements of the eyeballs or jaws. Dilatation of the left nostril and movement of the platysma took place. In the spasm the movement was confined to the deep extensors of the fingers and thumb and group of ulnar extensors, there being no movement of the upper arm and shoulder muscles. Examination showed that the patient was distinctly paretic in the left side of the face and arm, but not in the leg.

She had no affection of sensibility and the reflexes were not altered to any marked extent. She was probably hemianopsic, although this was not clearly determined owing to the mental condition of the patient.

The necropsy showed many interesting pathological conditions in various parts of the body, including a circumscribed area of hemorrhagic encephalitis in the motor cortex, this evidently having been the cause of the Jacksonian spasm.<sup>7</sup>

One of the forms of focal cerebral disease which must be taken into full consideration when the question of operation, and especially for operation for brain tumor in the motor region, is presented is that of arteriosclerosis which has caused either local instability or local softening with symptoms which simulate those which are exhibited by neoplasms. The cases of this kind most difficult of decision are those in which Jacksonian epilepsy is present. In such a case the history will be that of gradual cerebral failure dependent usually upon generalized arteriosclerosis with its renal and cardiac accompaniments, and a record of seizures and of progressive loss of power of the limbs, or the limbs and face of one side. Instead of the motor manifestations, or in addition to them, the symptoms may be loss or impairment of

<sup>7</sup> This case will be reported in full in a paper which will be presented at the meeting of the American Neurological Association, to be held in Boston, June 4 and 5 1906.

different forms of sensibility or of stereognostic conception or some disturbance of speech and writing, according to the parts involved outside of the motor region. The patient may have an attack of transient dazing or of vertigo at one time, and at another, with this or independently of it, some form of localized tonic or clonic spasm; the face may twitch on one side or the fingers and hand may be clinched, or the arm may lift or the toe may be extended. Still later this illy defined Jacksonian attack may merge into a facial, brachial, brachio-facial or hemispasm. In brief, the record is one of Jacksonian attacks slowly and irregularly developed to their full stature, usually with late coming on one-sided paresis or paralysis.

Such a case is to be differentiated from one of brain tumor by a close study of the manner in which the symptomatology has developed, by the exclusion of the general symptoms of brain tumor and by taking into consideration the evidences of renal, cardiac and general arterial disease. Optic neuritis is practically always absent, and a very skillful ophthalmoscopic examination will often show evidences of sclerotic disease of the vessels and of some grade of optic nerve atrophy. Headache if present is not that which is often characteristic of brain tumor. Nausea and vomiting are generally absent.

Examination of the urine may show albumin or casts or both. Dilatation with hypertrophy of the heart is present, and arterial tension is nearly always high. The possibility of the co-existence of arteriosclerosis and brain tumor must not be overlooked.

As in this connection I am chiefly concerned with the discussion of Jacksonian epilepsy, the interesting general subject of arteriosclerosis and focal cerebral lesions will not here be discussed in detail. I have had under observation several cases of necrotic lesion in which the diagnosis of brain tumor was made at some period in the history of the case, and in which operation was performed.

In one of my cases in which the localizing symptoms were astereognosis, diminution in pain and temperature senses, word deafness and word blindness, amnesic aphasia, paraphasia, lateral homonymous hemianopsia and late hemiparesis, operation was performed and revealed an area of necrotic tissue. A study of the history of this case shows how mistakes may be made with regard to what appear to be the general symptoms of brain tumor. At one period a most skillful ophthalmologist reported in effect that while optic neuritis was absent, the conditions present might indicate that it was imminent. Demonstrable neuritis was never present, neither

before nor during the several years which intervened before death and after the operation. The patient complained at times of headache, but this was not severe. His first marked symptoms were initiated with an attack of dizziness and numbness, but this dizziness proved not to be the vertigo of brain tumor, but that which is associated with arteriosclerosis and spreading vascular lesions. Nausea and vomiting were not present.

In another case which I saw in consultation with Dr. J. H. W. Rhein, and in which an osteoplastic operation was performed by Dr. A. C. Wood, an area, probably of necrosis, was found situated largely in the motor zone. The patient was a woman fifty-seven years old, whose train of serious symptoms was ushered in by a convulsion. Later she developed recurring aphasic attacks preceded by incoherence, excitement and fright; still later paralysis of the arm and leg and paresis of the face appeared. The reflexes were increased on the paralyzed side, including slight ankle clonus and the Babinski response. Sensation was everywhere preserved. Ophthalmoscopic examination showed moderate pressure signs where the arteries crossed the veins; otherwise the eye grounds were entirely normal. Some albumin was found in the urine, and at one examination one granular cast.

While true Jacksonian epilepsy was not a manifestation in either of these cases, they belong to the class of cases in which vascular lesions give a symptomatology somewhat closely simulating that of brain tumor. Cases with similar general symptoms and Jacksonian epilepsy are occasionally regarded as tumors of the motor region.

The diagnostician must not lose sight of another class of cases in which vascular lesions occur with brain tumor, but in other locations than that of the tumor.

The occurrence of hemorrhage or necrosis due to thrombosis or embolism, and especially the former, with brain tumor may, as Collier points out, give false localizing signs. He records one case in which operation revealed an area of necrosis which had evidently caused the localizing symptoms which guided in the choice of a site for operation, and in which subsequent necropsy showed the presence in addition of a large tumor. Hemorrhage is not very uncommon in the progress of a case of brain tumor, and may be in, around or at a distance from the site of the growth. The concurrence of vascular lesions with neoplasms is what might be expected when it is considered that tumors are so frequently observed after middle life, and in those who exhibit senile or presenile arteriosclerosis.

Hemi-epilepsy, or Jacksonian epilepsy of smaller range, is sometimes observed as a toxic or diathetic affection. One of the most striking cases of Jacksonian spasm ever seen by me was in a patient suffering from diabetes who had an attack of spasm while consulting me in my office. He remained conscious during the attack and even succeeded in talking a little about his feelings, although he did this with difficulty. The arm and face were the parts affected, the spasm beginning in the distal portion of the limb and extending to the other parts. It is now well known that monoplegias and hemiplegias sometimes occur in the course of nephritis, and in some of these cases necropsy has shown that all forms of gross lesion were absent. A few such cases have fallen under my own observation, necropsy showing no gross lesion. In other cases, however, where the toxic form of uremic monoplegia or hemiplegia was diagnosed, necropsy has shown a hemorrhagic or embolic lesion or local cerebral edema. Uremic convulsions occasionally are of Jacksonian type, and more frequently begin in the limbs or face of one side, the attack later becoming general. Jacksonian epilepsy is also sometimes observed in Korsakoff's disease or as an acute alcoholic manifestation, and may indeed be present in any form of toxic or infectious disease. These

toxic spasms need only passing reference in the discussion of tumors of the cerebral motor zone. It is only in extremely rare cases that the diagnosis is not evident, — cases in which the vertigo and headache are present, or in which an optic neuritis of toxic origin is regarded as due to cerebral neoplasm. The diagnosis is, of course, to be made by a study of the history of the case, by examinations of the urine and blood and by the absence of the typical general and focal symptoms of a brain tumor.

The dural epilepsies which have been considered on the previous pages are reflex epilepsies; in fact, they probably afford the best possible illustration of a severe convulsive attack due clearly to reflex causes. A tumor situated in the dura, or a galvanic or faradic current applied to this membrane, stimulates the sensory branches of the fifth nerve distributed towards its inner surface, and this excitation conveyed to the bulb produces the severe and characteristic spasmodic symptoms to which reference has been made. The broad assertion may be made that peripheral irritation almost anywhere in the body may cause, in rare cases, a convulsive attack, and that this may in still rarer instances assume the Jacksonian type. In such a case, as in the toxemic convulsive disorders, the spasm indicates cortical discharge, and it is probable that the



occurrence of the attacks is conditioned by unusual inherited or acquired instability of the motor cortex. It is only in a very unusual case that the diagnosis of brain tumor would be considered in such reflex spasms. Some years ago I reported a case of this kind in which the spasm, typically Jacksonian in its initiation and spread, was due to a fibroma of the palmar surface of the hand. The attacks became frequent and severe. They continued for some time after the operation for removal of the palmar growth, but eventually disappeared entirely. The patient was of a neurotic constitution and the intense peripheral irritation in this case undoubtedly affected the unstable cortex. The history of the case and the discovery of the source of peripheral irritation are sufficient to guide the diagnostician.

Some hystero-epileptic attacks bear a close resemblance to Jacksonian epilepsy. The presence of hysterical stigmata and the absence of the symptoms, general and focal, indicative of organic brain disease are sufficient to prevent error in diagnosis.

The question of the differential diagnosis of Jacksonian epilepsy due to tumor or other gross, and possibly operable, lesions of the motor zone, from idiopathic epilepsy is one of great moment. Collier goes so far as to say that the commonest

cause of Jacksonian spasm is idiopathic epilepsy. In several cases in recent years I have known operations to be done without revealing any tangible lesion, the diagnosis of the nature and site of the lesion having been chiefly made because of the characteristics exhibited by the Jacksonian spasm which was the chief feature of the symptomatology of the case. In some of these cases a small undiscoverable growth was present in the subcortex or just outside of the limits of the cerebral surface exposed, this being demonstrated by subsequent developments of a second operation or by necropsy. In other cases observation of the patient over a considerable time, as well as a more thorough consideration of all the features of the symptomatology of the case, have made it clear that the Jacksonian spasm, although apparently typical, was in reality simply an integral part of the attack of true idiopathic epilepsy. In rare instances the idiopathic case shows almost restricted Jacksonian manifestations, at least the spasm continues to be largely a hemi-epilepsy. It is extremely rare in an idiopathic case for the spasm to remain limited to one limb, or to one side of the face, although this is not unknown and patients, as is well known, may have abortive attacks of epilepsy with a sensory or sensorimotor manifestation of a very transient character in a part

to which the aura of a completed attack is commonly referred. In some cases in which Jacksonian spasm occurs as a part of the manifestation of an idiopathic epileptic attack, the Jacksonian spasm occurs, so to speak, inside the general convulsion; in other words, the patient during the seizure has clonic and tonic spasm which involves more or less irregularly all parts of the body, but in which the spasm shows itself most pronouncedly in the limbs or in the face and limb or limbs of one side of the body.

Every neurologist has had frequent occasion to confirm the truth of Dr. Hughlings Jackson's well-known opinion that almost every case of idiopathic epilepsy, if studied carefully enough, will be found to have had local spasm as the initiating phenomenon of the general attack. It is true that it is almost impossible in many cases to get a clear record of the initial local spasmodic phenomenon by questioning those who observe the attacks, and even the trained physician or nurse may fail to make this observation largely because of the speedy manner in which the spasm radiates to many parts of the musculature.

In a case recently observed, a convulsive attack began with a somewhat suffused appearance of the face, the head and eyes turning to the left conjointly with a spasmodic movement not very pronounced in the right upper extremity,

chiefly affecting the forearm, hand and fingers, which were held in a partially flexed position. The spasm did not, in the attack observed, become entirely generalized, but the left lower extremity was spasmodically extended. It was reported to me that in other seizures the spasms were or became general. In a second case spasm began with a movement performed by the pterygoid and masseter muscles of one side, and facial twitching, the patient becoming unconscious, with generalized tonic spasticity. In a third case the spasm, which soon became general, was in its earliest stage confined to tonic spasticity of the extremities of one side. An opinion in favor of operation was refused in these cases, the evidence pointing to idiopathic epilepsy. With the exception of the localized spasms, other signs of a growth or of localized meningitis were absent. These cases could be readily multiplied, and probably more striking illustrations of initial Jacksonian spasm in cases of idiopathic epilepsy, furnished. I refer to them simply because of their recently having come under notice and because they were under observation for the purpose of a decision with regard to surgical procedure. Among the operative cases of which I have notes are two in which osteoplastic operations were made by Dr. C. H. Frazier, and to which brief reference might

be made. In the first of these cases it is probable that the true solution of the case is that it is one of the idiopathic epilepsy very closely simulating a case of brain tumor with Jacksonian signs. In the other it is probable that sooner or later a subcortical neoplasm, at present small, will appear on the surface or in some position close to the limits of the exposed portion of the cerebrum.

The first of these cases was a man thirty-four years old, many of whose spasmodic seizures were carefully studied in the hospital of the University of Pennsylvania. These attacks usually began with a frequently repeated trisyllabic sound, the patient's head was turned somewhat to the right, his face drawn on this side and the right arm flexed at the elbow. During four or five months before the patient came under observation, he had had a series of attacks, about half a dozen in all, some of which were mild and others severe. The patient knew when the attacks were coming on by a feeling of confusion and dizziness and by a movement of the right forearm, which flexed and extended on the arm. He remained conscious long enough to experience and observe these phenomena. The light attacks passed off without the spasm becoming general. He had on one or two occasions what appeared to be the epileptic status, or at least a series of spasmodic attacks extending over three or four hours, and after one of these periods he remained unconscious for two days. In the severe and recurring attacks the spasm became general, although almost in-

variably beginning in the same way and always being more marked on the right side of the body.

Examination for all forms of sensation was negative; the grip of the right hand was not quite as good as that of the left, but no other evidences of paresis of the limb were present. Voluntary movement of the right side of the face was weaker than that of the left. The right knee jerk was exaggerated, but ankle clonus and the Babinski reflex were absent. Optic neuritis was also absent, and the patient did not suffer much from headache.

Operation was performed in this case, an osteoplastic flap being made over the midfrontal and the lower two thirds of the motor region. No lesion was discovered except that the dura seemed unusually thick and dense. This patient had a specific history, and the question of a gumma or gummatous meningitis was considered, but in the light of the operation and with the history which has only been briefly sketched, the case may have been one of idiopathic epilepsy. Of course it is possible that a subcortical prefrontal growth developing backwards may later be revealed.

The second case was that of a man thirty-two years old, of healthy appearance, without any history of specific disease or alcoholism. He said that he had been perfectly well until four weeks before he came to the hospital, to which he was referred by Dr. M. H. Fussell under whose care he had been as a private patient. Some three months before his admission he had given himself a sudden strain in attempting to get on a moving car, but otherwise had no history of injury. Four weeks before admission he noticed for the first

time feelings of numbness in the thumb and finger of the left hand immediately followed by twitchings of the left eyelid. Later he began to have frequent attacks of localized spasm which affected the left upper extremity alone, the left side of the face alone and both the left side of the face and the left upper limb. These were observed by various members of the neurological staff. The patient kept an account of his attacks which became very frequent before the operation. He remained conscious in them and described the peculiar sensations felt by him and would often detail the manner in which the attack was progressing, saying, for instance, "Now it is in the fingers, now in the arm, now in the eyes, now in the face," etc. The spasm was distinctly Jacksonian, being either brachial, facial or faciobrachial in form. In one of his seizures the patient first complained of numbness of the thumb and index finger of his left hand. In a few seconds a distinct twitching of the left side of the occipito-frontal muscle was noticed, followed quickly by movements of the orbicular and levator palpebræ, and next by movements of the left side of the mouth and face. Finally the right occipito frontalis took part in the spasm. The patient remained conscious, and in this spasm no part but the face was affected.

In another seizure first a fine clonic spasm of the thumb and forefinger was observed, quickly followed by supination of the hand and forearm, flexion of the hand on the forearm, then by biceps, anconeus and deltoid spasm. When the spasm began to affect the flexors of the forearm, the left occipito-frontal and

the left side of the face become involved also after the manner described in the previous notes. At the close of the main attack movement of the subscapular muscle could be distinctly felt, although not observed during the main attack. No movement of the eye-balls was observed. At no time during the attack was the patient unconscious. Many other attacks were observed, these recurring with great frequency, even as often as twelve or thirteen times in one day. In all either facial or brachial spasm or both were present, the details of the twitching differing considerably as regards the movement of the musculature involved, especially in the upper extremity. I had the opportunity of showing a portion of one of these attacks at one of my clinical lectures, the patient walking into the arena during the seizure. The occipitofrontal, orbicular and facial movements were still evident as he entered. The spasm in the arm was passing off, but the hands still slowly flexed and extended, the forearm being held semi-flexed on the arm.

Examination showed some slight general weakness of the left upper extremity, and in the thumb and fingers marked impairment of power. Weakness was marked in pronation and supination and in flexion and extension of the hand and fingers. Extension of the second and third phalanges and flexion of the first phalanx of the index finger were almost lost. He was unable to oppose the thumb to any of the fingers or to abduct the thumb. The musculature of the left arm was distinctly flabby as compared with that of the right, and slight wasting of the muscles of the left forearm was evident. Movements of the fingers and hand were



awkward, and attempts to make the finger to nose test caused some coarse tremor of the hand. The muscles affected by the spasm in the left side of the face, like those of the upper extremity, showed some impairment of power, but this was not marked. The deep reflexes in the left upper extremity were exaggerated.

Other parts of the body than the left side of the face and left upper limb showed no abnormal conditions although the knee jerks and deep reflexes generally were rather over-prompt. No loss of cutaneous sensation was anywhere present, and the patient was not astereognostic. Hemianopsia was absent, as were also all disorders of ocular movements. Repeated examinations of the fundus showed no optic neuritis, although some blurring of the disk was present. The patient complained at times of dull headache, but pain in the head was not that characteristic of a brain tumor. It was decided, however, that the symptoms probably pointed to a small growth in the cortex or subcortex of the arm and face areas.

Dr. Frazier performed an osteoplastic operation, uncovering the arm and face areas in the usual manner. No tumor was found. At one spot the coloration of the surface seemed somewhat lighter in appearance but incision here revealed nothing, and it was decided not to explore the subcortex any further. The patient made a good surgical recovery. He had a few left-sided spasms during a day or two after the operation, but these ceased, and at the time of writing, between six and seven weeks after the operation, he had had no recurrence of them. The arm is, however, considerably

more paretic, but it has improved in this respect since the first few days.

This case seemed to present in almost every respect the characteristics of a small gross lesion, and it is not improbable that a subcortical tumor will eventually make its appearance on the surface. The case is similar to one which came under my notice at the Philadelphia General Hospital in the service of my colleague, Dr. Wm. G. Spiller, and which will later be published in full by Dr. Spiller and Dr. Edward Martin who operated. This patient was a man sixty years of age who had had convulsions confined to the left side for eight years. The spasm implicated the left upper and lower limbs and left side of the face, and the face and eyeballs were drawn to the left. The attacks had become more severe during the past four or five years, and five were observed by Dr. Spiller within an hour. An operation was performed and a peculiar appearing area was uncovered, but it was not distinctly pathological. The patient died two days after the operation. A very small sarcoma was found in the right second frontal convolution, just in front of the pre-central convolution and immediately beneath the cortex.

Just as this paper was approaching completion an article by V. Plavec on minor (smaller) motor

epilepsy appeared in the *Neurol. Centralbl.*, Nos. 3, 4 and 5, Feb. 1, Feb. 15 and March 1, 1906. The author contributes the history of a case of a boy eleven years old at the time of the first observation. At this time the diagnosis of facial tic was made. Some years later the patient again fell under the attention of Plavec, when the diagnosis of abortive epilepsy was made, and still later it became clear that the case was one of ordinary idiopathic epilepsy with the minor or local seizures being similar in character to the Jacksonian attacks which are observed to occur during the progress of a true idiopathic convulsion. The not very extensive continental literature of the subject of Jacksonian epilepsy is reviewed by Plavec, especial attention being given to articles by Féré,<sup>8</sup> Binswanger,<sup>9</sup> Burnhardt,<sup>10</sup> Sarrailhe,<sup>11</sup> Liebert<sup>12</sup> and Kjelmann.<sup>13</sup>

He defines smaller motor epilepsy as that form of attack in which a local spasm occurs without disturbance of consciousness and without an aura. The differential diagnosis of hysterical attacks, reflex spasms, seizures due to cortical

<sup>8</sup> Féré: *Revue Neurolog.*, 1901, S. 143; also *Épilepsies et épileptiques*, Paris, 1890, Alcan., S. 104.

<sup>9</sup> Binswanger: *Die Epilepsie in Nothnagel's Pathologie u. Therapie*, xii, S. 148

<sup>10</sup> Burnhardt: *Erkrankungen der peripheren Nerven. Ibid.*, xi, S. 41.

<sup>11</sup> Sarrailhe: *Revue neurolog.*, 1903, S. 668.

<sup>12</sup> Liebert: *Deutsche med. Wochenschr.*, 1885, No. 37.

<sup>13</sup> Kjelmann: *Berliner klin. Wochenschr.*, 1894, No. 13.

lesions and idiopathic epilepsy is considered at some length in the light especially of the valuable contributions of Binswanger and Féré. In connection with what has been said in this paper, the conclusions of Féré, that cases of so-called tic are often in reality of epileptic nature, are of interest. Cases are cited to demonstrate the truth of this position. So-called attacks of myoclonus probably occur in about 5% of the cases of idiopathic epilepsy. The reader is referred to the paper of Plavec and also to the contributions of Binswanger, Féré and others for some interesting points in the diagnosis of Jacksonian epilepsy and its counterfeits.

A few of the differential points brought out by these writers might be presented here in addition to those to which attention has been called in previous pages.

The aura in idiopathic epilepsy is not as common as that occurring in organic epilepsy and in those cases of epilepsy due to reflex causes. Idiopathic epilepsy is liable to occur at night; true tics and hysterical attacks scarcely ever at night, although one or two cases are noted in the literature in which severe cases of tic were said to have occurred at night. Reflex epilepsy and true Jacksonian attacks may occur at night. Féré and Binswanger believe that idiopathic epilepsy may be of organic origin and that Jack-

sonian attacks may be only part of the idiopathic attacks, a point which I have already somewhat fully considered. Jacksonian attacks do not come on as often at night as do the idiopathic attacks.

Féré states that in Jacksonian or cortical epilepsy the patient is always awakened from sleep so that he is compelled to lie awake during the whole attack; in idiopathic epilepsy the patient is only awakened from sleep in those attacks which, during the day, would not cause him to lose consciousness.

An important symptom of minor motor epilepsy is more or less paralysis of the part after an attack. This occurs most often after cortical or organic epilepsy, but cases are on record in which after a reflex or idiopathic attack this has been present. The paresis may be overlooked, as it may last only a few minutes after the attack. At times instead of the convulsion the epileptic attack may be manifested by weakness, temporary in character, and this may occur without loss of consciousness. Instead of paresis there may be sensory changes, as diminution of the visual fields and disturbances of cutaneous sensation.



Reprinted from the University of Pennsylvania Medical Bulletin,  
July-August, 1905.

---

THE MOTOR AREA OF THE HUMAN CEREBRUM,  
ITS POSITION AND SUBDIVISIONS, WITH  
SOME DISCUSSION OF THE SURGERY  
OF THIS AREA.

BY CHARLES K. MILLS, M.D.,

*Professor of Neurology in the University of Pennsylvania ;  
Neurologist to the Philadelphia General Hospital ;*

AND

CHARLES H. FRAZIER, M.D.,

*Clinical Professor of Surgery in the University of Pennsylvania ; Surgeon to the University Hospital, the  
Philadelphia General Hospital, and  
the Episcopal Hospital.*

---

HISTORY AND LITERATURE.

The subject to which attention will be directed in the present communication is of continuing interest to the physiologist, neurologist, and surgeon. It first claimed particular attention through the suggestions based upon clinicopathological observations of Hughlings Jackson, and the physiological researches of Hitzig and Fritsch, and of Ferrier. While a *résumé* of the history of the subject would be of much value, such a historical summary would divert interest from the practical matters which it is our particular design to emphasize. We shall, therefore, pass at once to a consideration of our subject as designated in the title of this paper, and shall try to strictly limit ourselves to the points indicated by that title.

The first electric investigations of the human brain were made by Bartholow.<sup>1</sup>

The patient, a woman aged thirty years, had an epithelioma of the scalp which had destroyed the bone and exposed the dura. Experiments were made with both the faradic and galvanic currents with insulated needle electrodes, which were applied to the dura and also passed into the substance of the brain. Decided results were obtained from the dura and the cerebral stimulation. These were not of a character to indicate the position of separate motor centres. The method of investigation used by Bartholow was much criticized, and he afterward expressed regret at having employed it. It was objectionable in that the needles were inserted into the brain substance, and this in the days when antiseptic and aseptic precautions were not commonly used.

The early contributions to our knowledge of faradization of the human cortex were chiefly made by American neurologists and surgeons, and the observations of our countrymen have continued to hold first place in this field of practical research.

In 1897 Lamacq,<sup>2</sup> of Bordeaux, published a valuable paper on the cortical motor centres of the human brain, as determined by faradic excitation of the cerebral hemispheres of man.

This paper has not as yet been followed by any other of the same scope and importance. Lamacq collected chiefly from American and English medical literature the recorded observations up to the time of the appearance of his contribution, and, in addition, included a series of unpublished notes of cases furnished to him by Dr. W. W. Keen. The previously recorded cases summarized and reviewed by him included observations by Bartholow, Sciamanna, Horsley, Keen, Lloyd and Deaver, Mills and Hearn, Nancrede, Kam-

<sup>1</sup> American Journal of the Medical Sciences, April, 1874.

<sup>2</sup> Arch. Clin. de Bordeaux, November and December, 1897, vol. vi.



merer, Mills and Keen, Ransom, Sachs and Gerster, Steiglitz, Warnots, Laycock, Diller and Buchanan, Parker and Gotch, Vierordt and Schlesinger.

Lamacq also reviews observations bearing upon the subject by Starr, Angell, Bidwell and Sherrington, Dana, Guthrie, Hochenegg, Horsley, and Horsley and Beavor. For the bibliography of these investigators the reader is referred to the paper of Lamacq. Most of the contributions have been studied in the original by us, and will be used in drawing our conclusions, but it is apart from our purpose to elaborately discuss the literature of the subject.

Since the date of Lamacq's publication, contributions on the subject of human cortical faradization have been meagre, but attention should be directed to the recent articles by Krause,<sup>1</sup> Rothmann,<sup>2</sup> and Brodman.<sup>3</sup>

Highly important papers by Grünbaum and Sherrington,<sup>4</sup> recording the results of electric experimentation on the motor region of the higher apes, should be referred to in connection with the subject of cortical faradization of the brain of man. These physiologists, as is well known, hold, as the result of their experiments, that the motor region, at least in the anthropoids, is situated cephalad of the central fissure.

We shall first call attention briefly to three of the earliest cases in which cortical faradization was employed in Philadelphia, this being in 1888. They are of interest historically and also because of the striking results obtained, and are included in Lamacq's series of cases. They are the only recorded cases to which any detailed consideration will be given.

---

<sup>1</sup> Concerning the Pathology of Jacksonian Epilepsy and its Operative Treatment; remarks at Berliner medicinische Gesellschaft, February 22, 1905, referred to in Berl. klin. Wochensch., March 6, 1905, p. 272.

<sup>2</sup> Berl. klin. Wochensch., January 23, 1905, p. 101.

<sup>3</sup> Ibid. Remarks made in the discussion of Rothmann's paper, Brodman in these remarks referring to observations made conjointly with Krause.

<sup>4</sup> Proceedings of the Royal Society of London, November 21, 1901; February 27, 1902, and May 25, 1903.

In the first case, recorded by Keen,<sup>1</sup> trephining and cortical excision were performed by him May 30, 1888, the position of the hand centre having been fixed by means of bipolar faradization. Three convolutions running somewhat in the direction of the central fissures were at first exposed. No response was produced when the two most posterior of these gyres were touched by the electrodes, but when they were applied to the most anterior the hand instantly moved in extension on the wrist to the mid-line and to the ulnar side at different touches, the fingers being extended and separated.

From the description, the opening in this case was first so made with a one and one-half inch trephine as to probably only expose the postcentral and precentral gyres at about their middle part. The opening was enlarged, chiefly forward and downward, till it measured two and one-half inches anteroposteriorly by two and one-quarter inches vertically. The centre pin of the trephine was placed presumably about one-eighth inch behind the central fissure and one inch above the temporal ridge. The opening extended forward one and three-eighths inches, backward one and one-eighth inches, upward one inch, and downward one and one-quarter inches. After excision of what was believed, as the result of the faradic excitation, to be the hand and wrist centres, another application of the current was made just above the excised area, with the result that movements of flexion and extension of the left elbow and of the shoulder, which was raised and abducted, were noticed.

Exciting the convolution below the excised portion, an upward movement of the whole left face occurred, no one muscle being noticeably in isolated contraction. The movements performed by the platysma and the depressors of the mouth were not called forth. Finally, movements of the hand were evoked by touching the white matter at the bottom of the excised area.

---

<sup>1</sup> American Journal of the Medical Sciences, October and November 1888, vol. xcvi., n. s.

This case is worthy of special citation here because of the care with which the position of the central fissure was determined, the precision with which the faradic investigation was made, and the exact and well-defined responses which were obtained. The positions for extension of the hand at the wrist, the abduction of the hand, and the separation and extension of the fingers were obtained. Excitation of a centre above that for movements of the hand at the wrist, and of the movements of separation and extension of the fingers, caused movements of the elbow and of the shoulder, while faradization below the excised area caused an upward movement of the entire opposite side of the face. The results of the first faradic applications were re-enforced by touching the white matter at the bottom of the excised area, this causing movements of the hand. In this one well-studied and well-recorded case, the relative positions, from above downward, of the shoulder, elbow, hand, and face centres were demonstrated. The entire series of observations also indicate that the centres for the movements evoked were, in all probability, situated cephalad of the central fissure, as it will be recalled that no response was obtained when the applications were made to the two most posterior of the gyres in view.

The case of Lloyd and Deaver<sup>1</sup> was one of focal epilepsy, successfully treated by trephining and excision of cortical motor centres. The operation was performed June 12, 1888, by Dr. J. B. Deaver. One of us, Dr. Mills, was present at the operation. Following Reid's and Horsley's lines, an area was first exposed by an inch and a half trephine. This was supposed to be on both sides of the central fissure at about the junction of its middle and lower thirds. After the trephine opening was made the area was much enlarged, especially in an anterior direction, by a rongeur.

As it was not possible to locate the centre for excision by inspection of the convolutions, bipolar faradization was

---

<sup>1</sup> American Journal of the Medical Sciences, November, 1888, vol. xcvi., n. s.

resorted to for this purpose. This was presumably begun at a point back of the central fissure, the effort being made to apply the electrodes at Ferrier's wrist centre in the post-central gyre. The result was muscular contractions, causing turning in of the thumb on the palm, flexion of the fingers, and flexion of the wrist, extending to flexion of the elbow. Lloyd says that while the point of application was behind what appeared to him to be the Rolandic fissure, the difficulty of identifying fissures and convolutions in a small trephine wound is extraordinary. At a point farther below and in front of a fissure, probably the central, seen in the middle of the wound, faradic stimulation caused marked contraction of the face muscles of the affected side. The mouth was drawn toward the left side with a tremulous motion, and soon the tongue began to protrude toward the left corner of the mouth. Next the left thumb was adducted into the palm, then the fingers were contracted into the palm, and about the same time the face muscles began to contract more actively, while the head was drawn to the left side, and the left eyelid began to work. The hand was gradually closed, and contraction of the forearm and arm began, while the latter was drawn from the side to an angle of forty-five degrees (deltoid action), and contraction of the biceps occurred. No contraction of the leg muscles occurred at any time.

The case of Mills and Hearn,<sup>1</sup> in which operation was performed July 28, 1888, by Dr. W. J. Hearn, was one of trephining and cortical excision. The region intended to be exposed was the lower two-thirds of the arm area, the upper anterior portion of the face area, the hinder upper part of the speech area, and a posterior strip of the area for movements of the head and eyes.<sup>2</sup> The convolutions uncovered

<sup>1</sup> Transactions of the Congress of American Physicians and Surgeons, 1888, vol. i. ; also *Brain*, 1890, vol. xii. p. 273.

<sup>2</sup> In speaking of these areas for movements of the arm, the face, the head, the eyes, and for speech, they are of course referred to as understood at the time, and as outlined in the scheme of Dr. Mills, published in 1888. In this scheme the postcentral as well as the precentral gyre and parts anterior to it were included in the motor region.

were therefore presumably nearly the lower halves of the two centrals, the posterior extremity of the second frontal, and the posterior superior corner of the third frontal. Four distinct responses were obtained on careful bipolar cortical faradization: (1) in the most anterior position at which movements resulted, distinct conjugate deviation of the head to the opposite side; (2) a little behind and below this point, drawing of the mouth outward and upward; (3) about half an inch above this spot for movement of the angle of the mouth, extension of the wrist and fingers; (4) behind and above the latter point, distinct flexion of the fingers and wrist. Continuing and increasing the faradic application at this last determined point, the fingers, thumb, wrist, and forearm were successively flexed, and the whole extremity assumed the "wing-like" position, the order of events, according to three persons who were present and who observed the spasms for the relief of which the operation was done, being exactly that which had been noticed in the beginning of the patient's convulsive seizures.

A study of the above description of the opening and of the points at which applications were made shows that they were all cephalad of the central fissure. The position of the head and the eyes given in the diagram published in 1888 was in the caudal portion of the second frontal gyre at about its junction with the precentral. Starting with the application made here, a point a little below and behind this would evidently be in the precentral convolution, near the junction of its lower and middle third; a spot one inch above would still be in the precentral and a position behind and above this point probably reached only to the central fissure at the most.

Passing by the other observations collected by Lamacq, these three cases are recalled in some detail to illustrate the exact manner in which the bipolar faradization was used as early as 1888 and subsequently by Philadelphia surgeons and neurologists; and also because of their unusual value

and their important bearing upon the questions of the pre-central localization of the entire motor area.

We shall next give a series of hitherto unpublished observations; in the first seven cases the operations were all performed by Dr. Frazier, the cases, as indicated in the summaries, having been under the care of Drs. Mills, Spiller, or McConnell, or having been directly in the service of Dr. Frazier.

#### NEW OBSERVATIONS.

OBSERVATION 1. This case is reported in full by Dr. J. W. McConnell, in the issue of the UNIVERSITY OF PENNSYLVANIA MEDICAL BULLETIN in which this article appears. The case was studied by Dr. Mills and Dr. Spiller in consultation, and the operation was performed by Dr. Frazier, May 21, 1903. The patient was a young man who had a tumor lying athwart the posterior portion of the first and second frontal convolutions.

The base of the flap was parallel to the Sylvian fissure; both its anterior and posterior boundaries were practically vertical. The opening was in front of the central fissure, except at about its lower fourth. During the progress of the operation the opening was increased in front and upward with the rongeur.

The electric applications were made over apparently uninjured cerebral substance between the posterior limit of the tumor and the posterior limit of the opening. The upper margin of the opening was one inch from the mesal line. The first application was made one and one-half inches from the upper margin of the opening and one and one-half inches anterior to its posterior margin; it caused a twitching of the upper eyelid on the right side, followed by spasm of the right face. The second application was made two-fifths of an inch above the first and gave closure of both eyelids. The third application, two-fifths of an inch below the first, gave contraction of the right upper eyelid and of both masseters;

the left eyelid did not move. An application one and nine-tenths inches posterior to the anterior edge of the opening and one and one-half inches from the superior border of the opening gave contraction of the right upper eyelid and of the right masseter. The next application, made four-fifths of an inch from the anterior edge and one and one-half inches below the superior edge, gave forward movements of the head and contraction of both masseters and of both temporals.

All of these applications, with the possible exception of one, were well forward of the central fissure.

OBSERVATION 2. The patient was a boy, aged eleven years, with epilepsy, in whose case the diagnosis of dural adhesions over the motor area had been made. He was under the care of Dr. Spiller.

The operation was performed May 6, 1905, by Dr. Frazier, an osteoplastic flap being made in the usual manner. It was designed to have the opening two-thirds in front and one-third behind the central fissure. Its upper border was one-half inch from the mesal line, and was four inches in length, as measured by the incision in the scalp. The anterior and posterior heights of the flap were also about four inches. The length of the base line was two inches, and this was situated one-half inch above the line of the Sylvian fissure and parallel with it.

After the dura was raised, a fissure, apparently the central fissure, was seen at about the middle of the opening, although its identity was, of course, uncertain.

Six applications were made with the faradic current of the strength usually employed, but no response was obtained. Three of these were at different heights in the postcentral and three at different heights in the precentral gyre. The first response obtained was at the seventh application, which was made one inch below the superior and one and three-fourths inches in front of the posterior margin of the opening, and therefore unquestionably in front of the central

fissure. The movements resulting were those of the jaw and an uncertain movement in the right arm. A final application, made one inch below and three-quarters of an inch in front, resulted in flexion of the right arm on the forearm and a movement in the right face.<sup>1</sup>

This last result was probably due to stimulation of the postcentral convolution, but a considerable faradization of the cortex had taken place before it was obtained.

OBSERVATION 3. The patient was a girl, aged seven years, who was under the care of Dr. Spiller. The diagnosis of traumatic epilepsy had been made.

The operation was performed by Dr. Frazier April 16, 1905. The usual osteoplastic flap for exposure of the motor region was made, with the view of uncovering the cortex two-thirds in front and one-third behind the central fissure. The upper limit of the incision was one-half inch from the mesal line. The length of the superior scalp incision and the length of both the anterior and posterior sides were as nearly as possible four inches. The base line, which was two and one-half inches in length, corresponded to the line of the Sylvian fissure.

Responses to the faradic applications made were obtained three times: the first was with a weak current, the electrode being applied one-half inch below and three-quarters of an inch in front; movement of the jaw resulted. A fissure, apparently the central, was visible, and the electrode, although applied three-quarters of an inch by measurement in front of the posterior bone line, was placed directly over this fissure. The second response with the same current was obtained one-half inch below and one inch in front, this causing movements of the shoulder and in the face. The current was now made somewhat stronger, and when an application was made two inches below and one-half inch in

---

<sup>1</sup> As in the other cases recorded, when the expression below and in front is made use of, it means in every instance below the upper margin and in front of the posterior margin of the opening.



front, movements of the right shoulder and of the jaw occurred.

OBSERVATION 4. The patient was a man, aged thirty-seven years, with a diagnosis of traumatic epilepsy. The case was under the care of Dr. Spiller.

The operation was performed by Dr. Frazier March 4, 1905. The opening was made on the right side of the head. The scalp incision, which was parallel with the mesal line and one-half inch below it, was three and one-half inches in length. Each anterior and posterior boundary was three inches in height. The base line was two inches in length. The flap was made on the usual plan.

Four unipolar applications with the usual current used at the beginning of the trials gave no response, three of these being behind and one in front of the central fissure. The fifth application, which was made one-half inch in front and one inch below, caused elevation of both shoulders. Another application, one-half inch in front and one and one-half inches below, gave a similar response. Another application, one-half inch in front and two inches below, gave response in both shoulders and in the right side of the neck. The next application, one and one-fourth inches in front and one-half inch below, gave no response. The next application, one and one-fourth inches in front and one inch below, caused response in both shoulders, the right and left upper arm, and the right pectoral muscle. The succeeding applications and their results were as follows: Two inches in front and one-half inch below, response in the left and right shoulder; two inches in front and one inch below, response in the left and right shoulder; two inches in front and one and one-half inches below, response in the right shoulder, left shoulder, and left forearm.

At first we were at a loss to account for the response in both shoulders, but it may have been due to the large-sized electrode which was applied to the back, reaching to both sides of the mesal line.

OBSERVATION 5. The patient, a man aged thirty-two years, was under the care of Dr. Mills. The diagnosis of brain cyst or tumor had been made.

Dr. Frazier operated May 23, 1905, exposing the motor area with the usual flap, the upper border of the opening, three and one-half inches long, being one-half inch from the mesal line. The anterior and posterior boundaries were three inches in height and the base line two inches. The operation was planned to have the opening one-third behind and two-thirds in front of the central fissure. A subcortical cyst was found in the anterior part of the opening.

Several unipolar faradic applications were made, or at least were attempted to be made, the current being gradually increased. No response was obtained, and it was found that one of the electrodes had become detached. The connection having been made, an application was made at a point just behind the central fissure, at about the middle of the opening, which resulted in a very marked response. The right arm flexed at the elbow at an angle of about 130 degrees, complete flexion at the wrist taking place almost simultaneously and immediately afterward flexion of the fingers. This was followed by twitching or clonic spasms of the entire upper extremity, the parts of the limb being retained in the position above described. The spasm in the right arm was followed by some twitchings in the leg and face of the same side, and eventually by a spasm in the left upper extremity, the left forearm being flexed on the arm at nearly a right angle.

This case is presented to indicate that a strong current applied even behind the central fissure may cause convulsive response, which, beginning in the parts controlled by the centres nearest the electrode, may extend to other portions of the same side of the body or even to the opposite side. It is probable that the extension of the opposite half of the body is brought about by way of the bulbar or spinal commissures.

OBSERVATION 6. The patient was a girl aged nine years. The diagnosis of adhesions over the face area was made. The case was under the care of Dr. Spiller.

The operation was performed March 31, 1905, by Dr. Frazier, the opening being made on the left side of the head with the usual osteoplastic flap, the scalp incision being one-half inch from the mesal line.

This case is recorded simply as showing that unipolar cortical faradization sometimes results negatively. Six applications of the current, usually producing some response, were made equally in front and behind the central fissure. A much stronger current was applied with the same negative results. The conditions were the same as in the preceding cases.

OBSERVATION 7. The patient was a boy, aged fourteen years, who had been shot in the left temple, and was under the care of Dr. Frazier. At the time of admission to the hospital his main symptoms were impairment of muscular and cutaneous sensibility, astereognosis, etc., in the right upper extremities, indicating a probable lesion of the post-parietal region, where the position of the bullet was fixed by the *x*-rays.

The operation was performed March 17, 1905. The opening, somewhat irregular in shape, was two and three-quarter inches in its superior limit or length and two and three-eighths inches in height. It was chiefly posterior to the central fissure, but included portions of the leg and arm centres of the precentral convolution. The bullet was not found.

A series of faradic applications were made to the cortex posterior to the central fissure without any response. The strength of the current was increased until it was as great as that employed in the other observations here recorded.

This case is recorded to show that faradic applications made over the postcentral and the superior and inferior parietal convolutions when the precentral area was unstimulated did not cause response in movement.

For the three following observations we are indebted to Dr. W. W. Keen, who has kindly furnished us with the notes of the cases, these not having been previously published.

OBSERVATION 8. The patient was a young woman, B., who was supposed to have a tumor in the motor region, but this was not found, faradic excitation having been employed to corroborate the correctness of the position of the opening with regard to the parts supposed to be involved.

The operation was performed February 9, 1898. A bipolar electrode was used. The first application was made in the postcentral gyre, two and three-fourths inches from the mesal line; no movements resulted. The second application was in the precentral gyre, one and nine-tenths inches from the mesal line; the left fingers were flexed and the hand was partly flexed. The third application was at a point in the precentral convolution, one and one-half inches from the mesal line; the proximal phalanges and the wrist were partly flexed. A fourth application, made over a convolution in front of the precentral convolution, presumably at the same level, produced the same movements as the previous excitation.

Dr. Keen expresses some doubt in his report as to which was the precentral and which the postcentral convolution, but we have given his notes as they were originally made by him.

After an incision into the brain substance, exploration was made for a tumor, and it was believed, owing to the resistance offered, that the growth was present, but it was too deep-seated to remove. The dura was now closed, some brain tissue being lost. The bone was not replaced.

OBSERVATION 9. The patient was a man, aged twenty-eight years, in whose case the diagnosis of epilepsy following fracture of the skull was made by Dr. Keen. As he had had only two epileptoid seizures, and these both began by twitching in the left foot and leg, the case was thought to be a favorable one for relief by operation. Dr. Keen performed the operation November 30, 1898.

The skull was chiselled with gouge and hammer over a depression on the right side of the head, two and three-eighths inches from a point one and one-tenth inches back of the middle of the inio-glabella line, this opening being nearly one inch in diameter.

When the bipolar faradic electrode was applied at the anterior part of the opening at about its middle, contraction of the left hand occurred. When thrust upward toward the middle line under the skull a slight contraction took place in the left leg.

A small opening was made in the dura to discover whether there was any clot or other lesion. As none could be found, the opening was closed by a single stitch and the incision then closed without replacing the bone.

From the description of the points of application, these were probably just in front or along the line of the central fissure.

OBSERVATION 10. The patient in this case was a young man, aged twenty-one years, upon whom Dr. Keen operated January 20, 1903, for the relief of epilepsy.

As the spasms always began by a peculiar sensation in the left foot, which extended up the leg and body to the head, it was decided to expose the leg area for exploration. The opening was osteoplastic, of truncated shape. Its upper border was two-fifths of an inch to the right of the mesal line. The length of the superior scalp opening was three and nine-tenths inches. The two oblique incisions for the sides of the opening converged to a base of one and seven-tenths inches. This base was placed somewhat obliquely in front of the first incision, so that in truncating the opening its posterior side followed approximately the direction of the central fissure.

The operation was planned to have the central fissure traverse the opening from above downward, so as to about bisect it.

The bipolar faradic electrode was applied to the brain at

the upper margin of the wound, in what were believed to be the precentral and postcentral convolutions. The report states that the left arm was immediately thrown into spasm (presumably after the first application and also after the second). The opening not being high enough to expose the leg centre, the bone was gnawed away to the sagittal suture and the flap of the dura was extended almost up to the margin of the longitudinal sinus. Both the precentral and the postcentral convolutions were faradized at this level. No response was gotten from the postcentral, but immediately when the precentral was touched with the electrode the left leg was thrown into a general spasm, lasting about the same time as the spasm from the previous application, which was from one-third to one-half a minute. After exploring the leg centre to the depth of one and one-half inches without result, the wound was closed.

This case is of much importance as indicating, first, that the area for the lower extremity is close to the mesal line, and, secondly, that it is probably situated entirely in front of the central fissure. It also shows the great importance of using cortical faradization in order to be sure that the proper level of the motor area has been uncovered.

#### POSITION OF THE MOTOR ZONE WITH REGARD TO THE CENTRAL FISSURE.

In order to get some data of value with regard to the position of the motor area with relation to the central fissure, we have made an analysis of the results of faradic applications in 25 cases, these including, as nearly as we could determine, 138 applications. The cases made use of were, in the first place, those published for the first time in the present communication, 10 in all; the 15 previously published cases included cases recorded as follows: By Keen, 7; by Mills and Keen, 1; by Keen and Sinkler, 1; by Lloyd and Deaver, 1; by Mills and Hearn, 1; by Nancrede, 1; by Ransom, 1, by Steiglitz, 1; and by Parker and Gotch, 1.

In preparing these data the cases recorded by Lamacq from unpublished notes furnished by Keen were used, the original manuscript of these cases having been examined through the kindness of Dr. Keen.

The result of the analysis was as follows:

Number of cases . . . . .	25
Number of applications . . . . .	138
Responses in front of central fissure . . . . .	62
Responses behind central fissure . . . . .	20
Responses in uncertain position as to the central fissure	14
No response in front of central fissure . . . . .	14
No response behind central fissure . . . . .	28

It was sometimes difficult to determine the number of applications and the exact position at which the electrodes were applied. It is for this reason that the responses in fourteen instances are recorded as having been in uncertain position with reference to the central fissure. Most of the applications included under this statement were made close to or along the line of the central fissure. It would probably be as nearly fair as possible to regard half of them as having been in front and half behind, remembering that we include those applications made along the anterior slope of the fissure as in front and those along its posterior slope as behind. In some instances in the recorded cases the statements were such as that a series of applications were made behind the central fissure or in the postcentral convolution without any result. It is probable, therefore, that the whole number of applications made in the 25 cases was somewhat larger than is given, but the results of the tabulation and analysis can, we believe, be relied on as accurate in their teachings. It will be seen that the data are overwhelmingly in favor of the view that the motor region is in front of the central fissure.

We might cite here as having some historical interest in connection with the question of the precentral position of the motor region from the paper on "Cerebral Localization in its Practical Relations," published by one of us, Dr. Mills,

in 1888: "Keen estimated the portion of the convolution as containing the hand centre as about one and one-fourth inches long, and he places the centre for the wrist and fingers in the pre-Rolandic gyrus, its lower limit being at three-eighths of an inch above the temporal ridge, and its upper end where it fused with that of the elbow 32 mm. higher up. The shoulder he placed still higher, while the centre for the upper face was in the same convolution below. These results correspond closely with those of Horsley. These facts of experiments on man would seem to uphold the view that the motor zone, in man at least, is much more extensive in front of than behind the fissure of Rolando. These results of Keen were all produced by excitation of the cortex anterior to the fissure of Rolando, supposing of course his determination of that fissure to have been correct."

#### MAIN SUBDIVISIONS OF THE MOTOR ZONE.

Accepting the view that the motor area is situated in front of the central fissure, what are its extensions and its main subdivisions? We believe it is largely limited in man, as in the anthropoids, to the precentral convolution projecting to some extent forward in one position. This forward projection is so situated as to include contiguous portions of the posterior extremities of the second and third frontal gyres. The chief subdivisions of the motor region are, from below upward: 1. The face area. 2. The area for movements of the eyes and head (the prefrontal projection), the centre of which is about on a line with the junction of the areas for the face and the upper extremity. 3. The area for the upper extremity. 4. The area for the trunk. 5. The area for the leg. The area for the movements of the face, in which we include movements of the tongue, lips, larynx, angle of the mouth, jaws, and eyelids, is a comparatively large one, extending from below upward to or just above the genu of the central fissure. The area for the arm next above this is a little more extensive vertically; next above comes a narrow



trunk area, and above this the leg area, or at least that portion of it which is on the lateral aspect of the hemisphere. So far as the results obtained by faradization of the human brain go, these four areas would appear to be exclusively confined to the precentral gyre. The best vertical separation of these areas would probably be brought about by regarding the precentral gyre as subdivided vertically, or at least along the central fissure, into fourths; three of these fourths from below upward are occupied by the face and arm areas, the latter being somewhat larger vertically than the former; in the upper fourth are, situated from below upward, the areas for the trunk and leg, the former occupying only a narrow strip. The area for movements of the eyes and head is, as has already been indicated, on a level with a lower strip of the arm area and an upper strip of the face area. The area for the upper extremity is undoubtedly the largest of the main subdivisions of the motor zone, but is not as much in excess of that for the face as has been sometimes represented in diagrammatic schemes. The lower extremity is only represented on the lateral surface of the hemicerebrum by a comparatively narrow strip of the precentral convolution, but it has a considerable representation on the mesal aspect. In the diagram (Fig. 1) these main subdivisions are represented as nearly as possible in accordance with the above description.

As our present consideration of the subject of cerebral localization is particularly in connection with the surgical procedure, we shall not discuss the question of the extent and subdivisions of the motor zone on the mesal aspect of the hemisphere, simply saying that the leg area and probably centres for the anus and vagina are present in the paracentral lobule in front of the line of the central fissure.

#### SUBDIVISIONS OF THE FACE AREA.

The face area is probably subdivided in the human cortex, as represented in the diagram (Fig 1). The centres for the tongue, lips, larynx, and platysma have not been indicated

as the result by us of a study of human cortical faradization, but have been adopted tentatively from other observations. All the other centres indicated, namely, those for the angle of the mouth, the eyelids, and the jaw, have been located from a study of the observation analyzed in this article. A centre for movements of the angle of the mouth has been several times determined in about the position shown in Fig. 1, namely, in the precentral convolution about the junction of

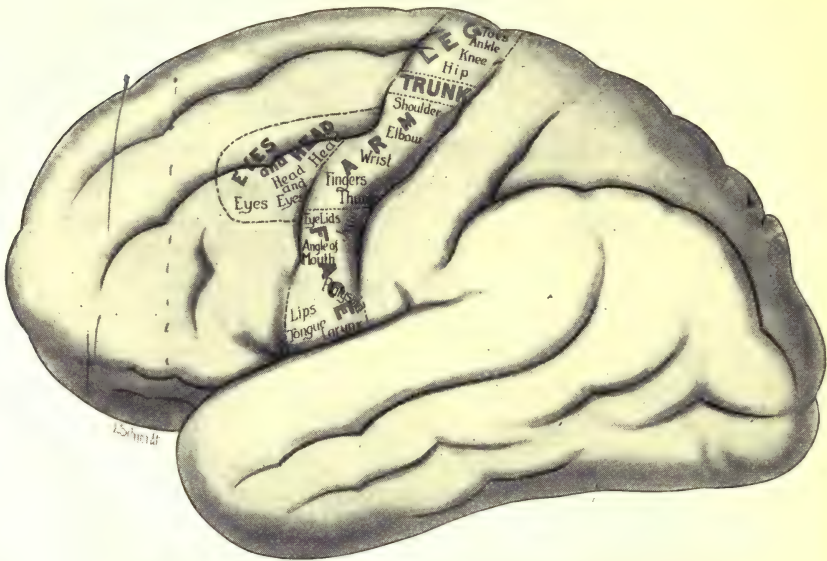


FIG. 1—Scheme of the motor zone and its subdivisions.

the middle and upper thirds of the face area. Above this and perhaps a little forward is a centre for the eyelids. The centre for the alæ of the nose is probably near the same level, but has not been indicated in the diagram. The movements of the jaw would seem, from a study of the observations here recorded, to have a rather wide representation, but as nearly as could be determined primary movements of the jaw are elicited at a point above and somewhat behind the centre for the angle of the mouth.

With regard to the subdivisions of the face area given, a study of the new observations (1, 2, and 3) will show that these have been confirmed or indicated by them. The positions are also in accord with the previously recorded observations of Keen, Mills and Hearn, and others.

#### SUBDIVISIONS OF THE AREA FOR THE EYES AND HEAD.

The centre for movements of the head to one side is probably situated at about the position where the second, third, and precentral gyres come together, as indicated in the scheme. A centre for conjoint movements of the head and eyes is probably situated just anterior to this position, and one for movements of the eyes alone still more forward. Objection has been made to giving distinct centres of representation for movements of the head and of the eyes. It seems to us quite clear, however, that such separate centres should be recognized. The simplest experiment shows that one can move the head to the left or to the right without moving the eyes, that the head and eyes may be moved together, or that movements of the eyes in different directions may be made independently of those of the head. Each separable voluntary movement has separate cortical representation. Forward movements of the head were produced in the case recorded as Observation 1 by excitation of a point about two and one-half inches from the mesal line, at about the position where the centre for head movements is indicated.

An interesting practical matter in connection with the question of a centre for movements of the head and eyes is that which is brought up by the fact that several observers have noted, as the result of human cortical faradization, that movements of the head sometimes take place toward the side on which the application is made. We recently had under observation a case of Jacksonian epilepsy in which the spasm began in the upper extremity of one side, the head turning during the convulsive attack toward the other side. We

have observed other such cases, but have also had cases in which movements of the head and eyes were toward the side on which the spasm in the face or extremity occurred. The problem involved in these apparently contradictory observations as to the movements of the head and eyes is one which should receive further careful consideration.

#### SUBDIVISIONS OF THE ARM AREA.

The centres for movements of special parts of the upper extremities are situated in the precentral convolution, and counting from below upward are those for the thumb, fingers, wrist, elbow, and shoulder. The centre for the thumb movements is one which has received much attention in cortical faradization of the human brain, as from Horsley, Keen, Nancrede, Buchanan and Diller, and Parker and Gotch. The weight of the evidence is in favor of its being located in the most inferior portion of the arm area, close to and probably extending into the anterior slope of the central fissure. It has been placed by some observers in the postcentral convolution, but close reading of the reports of observations which indicate this position shows that the centre stimulated was either within the central fissure or so close to it that the stimulation of the posterior lip of the fissure may have been transmitted to its anterior slope.

The centres for the movements of the fingers are situated just above the thumb area, and, for the most part, somewhat anterior to the latter. To a considerable extent the representation of different movements of the fingers has been determined. The index-finger movements are usually differentiated. Horsley obtained isolated flexion of this finger, its centre being in the precentral gyre, just above the thumb centre. One movement isolated by Keen was that of extension of the index finger, flexion of the other fingers, and rotation of the hand, this being the exact movement often made in pointing forward and from one side to the other. Extension of the index, middle, and little finger was also produced

by Keen from a centre in the precentral convolution. Some of his observations would seem to show that each finger has its separate centre. Mills and Hearn were successful in separating the centres for extension and flexion of the fingers. They found them above the centre for the angle of the mouth, the centre for flexion being behind and a little above that for extension. Keen obtained flexion of the fingers and of the wrist in the precentral gyre, near its anterior border. Ransom separated extension and flexion of the fingers by 12 mm. Horsley found the centre for the fingers in the precentral gyre, between the centres for movements of the index fingers and those for elbow movements. Bechterew found the finger centre between those for movements of the shoulder and thumb. Even lateral movements of the fingers have been isolated by human cortical faradization.

Movements of the wrist have been somewhat frequently observed in the human subject as the result of cortical faradization, usually however in connection with the movements of the finger or of the elbow. Horsley made a unique observation in one case, that of extension of the wrist with flexion of the fingers. The centre is located between the centres for the fingers and that for the elbow. In the case of Mills and Hearn there was first extension of the wrist and fingers, and at a point more posterior flexion of the same.

In several instances simple elbow movements have been produced by excitation of that portion of the precentral convolution which is situated just above the level of the representation of movements of the fingers. In one or two cases the same responses have been elicited by excitation apparently applied directly in the central fissure, and in one or two others when the application was behind or close to the fissure.

Elevation and other shoulder movements would appear to be represented in the most superior portion of the arm area, although it is difficult by cortical stimulation to get isolated

movements of this portion of the upper extremity. In one or two instances the writers found movements of the shoulder elicited from a considerable portion of the arm area, and with a strong current, even from the postcentral gyre.

#### AREA FOR TRUNK MOVEMENTS.

We have not had any personal experience with regard to the situation of the centres for movements of the trunk, nor, so far as we know, have any such observations on the human subject been put on record. The experiments of Grünbaum and Sherrington indicate that the representation of trunk movements in the anthropoids is in a narrow strip just above the arm area, and therefore between it and the leg area, a localization in opposition to that of Horsley, who placed the centres for trunk movements on the lateral and mesal edges of the hemisphere in front of the leg area. M. Allen Starr, in one case of cortical faradization during an operation, observed movements of the trunk as the result of excitation of a centre just above the level of the arm area; this observation is corroborative of the results obtained by Grünbaum and Sherrington.<sup>1</sup>

#### SUBDIVISIONS OF THE LEG AREA.

The centres for movements of different segments of the lower limb have not been isolated as well as those for separate movements of the upper limb and of the face. Lamacq observes correctly that the movements of the lower extremity are little differentiated, and that the area for these movements is quite small, a view which has been confirmed by the experiments of Grünbaum and Sherrington, and recently by our own observations. On the lateral surface of the hemisphere the leg area in the human subject probably does

---

<sup>1</sup> Starr referred to this observation, which has not before been put on record, in the discussion of this paper at the meeting of the American Neurological Association in June, 1905.

not extend more than one-half or three-fourths of an inch from the longitudinal fissure. Movements of special parts of the upper extremity have additional and probably larger representation on the mesal aspect of the hemisphere. For the present we have adopted the order of representation of separate movements of the lower extremity as they have been long held, namely, counting from below upward, those for the hip, knee, ankle, and toes. A portion of this representation is on the mesal surface of the hemisphere.

#### THE TECHNIQUE OF CORTICAL FARADIZATION.

Certain difficulties in determining precisely what portion of the cortex is exposed to view are often realized by the surgeon and neurologist. This is especially true when but a limited area of the cortex is exposed and the pia mater is still intact. It seemed desirable that some plan should be adopted whereby the observations on faradic excitation of the cortex could be made and recorded with such accuracy that the results would be accepted as a contribution to our knowledge of the physiology of the motor cortex. The plan which we have recently adopted consists essentially in applying the electrode at certain fixed distances from the superior and posterior margins of the opening. Several studies were made upon the cadaver.

In outlining the flap for the exposure of the motor area, we have localized the Sylvian and central fissures by the Anderson-Makins method shown in Fig. 2. The flap is usually so mapped out as to have two-thirds of it in front and one-third behind the central fissure. Its posterior margin is made parallel and one inch behind the central fissure, and the superior margin one-half inch from the mesal line. The base of the flap is usually nearly on a level with the Sylvian fissure. If the flap as outlined on the skull commonly measures two inches at its base and four inches along the superior margin and sides, the opening in the bone is usually one-quarter to one-half inch narrower. A flap of about these

dimensions is made in all cases in which the symptoms are strictly referable to the motor region.

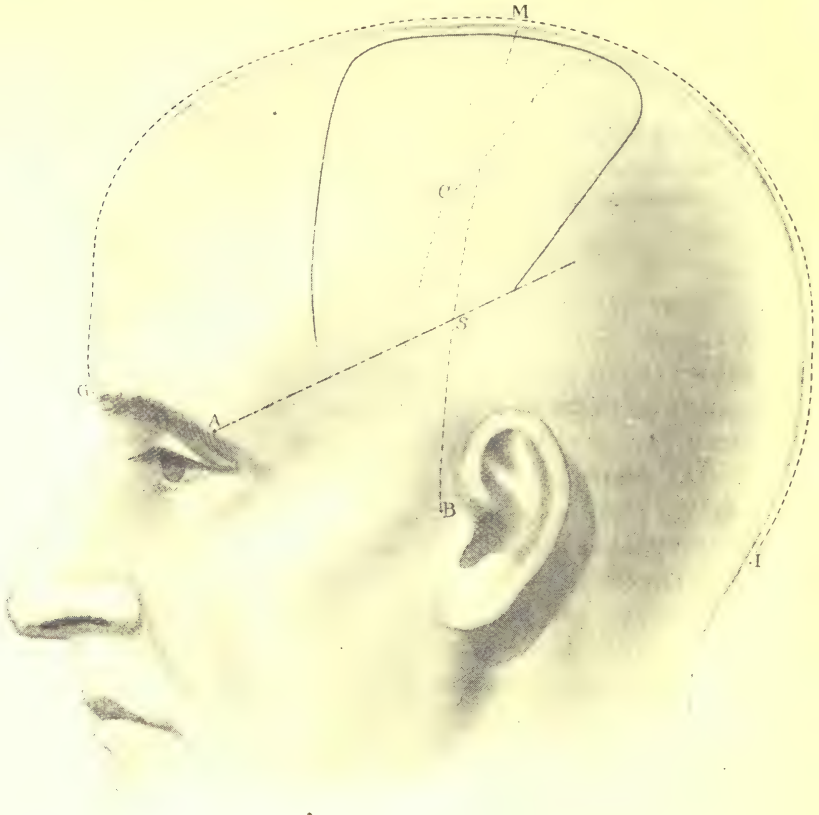


FIG. 2.—The Anderson-Makins lines and the usual osteoplastic flap for exposing the motor region: *G*, glabella; *I*, inion; *M*, midsagittal point, midway between *G* and *I*; *A*, external angular point; *S*, squamosal point, intersection of oblique and frontal lines at junction of middle and lower thirds; *B*, preauricular point; *C*, central fissure. Flap designed to be two-thirds anterior and one-third posterior to the central fissure.

In faradizing the cortex the electrode, according to a previously arranged scheme, is applied first to six different points, or to any of these; three of these should be about one-half or



three-fourths of an inch in front of the posterior margin of the flap, presumably behind the central fissure; and three at one and one-fourth to one and one-half inches in front of the posterior margin, at levels corresponding to the selected points of post-central excitation (Fig. 3 at points 1, 2, 3, 4, 5, and 6). Subsequent applications can, if desirable, be made to points intermediate and slightly anterior to and between the points

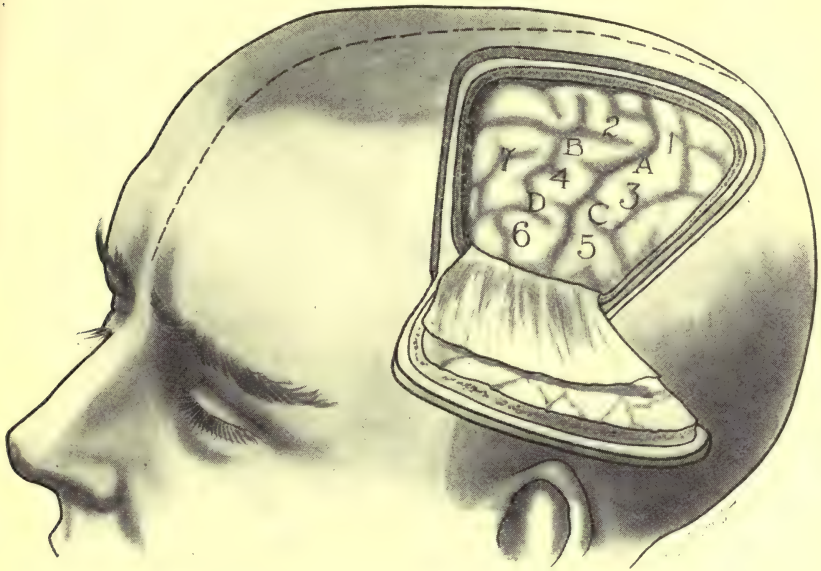


FIG. 3.—Bony and dural flaps reflected so as to show the convolutions of the motor area. The numbers 1, 2, 3, 4, 5, 6, and 7, and the letters *A*, *B*, *C*, and *D* indicate the points of selection for cortical faradization.

first selected, as at *A*, *B*, *C*, and *D*. If the position of the centre for movements of the head and eyes should be in question, the exploration should always be made well forward in or near the position 7. Of course other points than those here given can be used at the judgment of the operator and according to the exigencies of the case. These should be designated in the description of the procedure according to their distance

from the superior and posterior margins of the opening in the bone. As the superior border of the opening is at a fixed distance from the mesal line, by indicating the distance of the points of excitation from the superior margins, the distance from the mesal line is also at once obtainable. It will be seen that we do not depend at all upon any attempt to recognize by the sense of sight the fissures and convolutions.

In order to assure ourselves of the correctness of the positions of the points of excitation usually selected by us with reference to the central fissure, an osteoplastic operation was made on the cadaver after the plan employed in operation on the living. Our standard motor flap, bony and dural, was reflected and pins were first inserted into the brain around the margin of the opening, and also others at points presumably corresponding to those usually first selected by us for faradic applications; in other words, at the spots indicated at 1, 2, 3, 4, 5, and 6 in the illustration (Fig. 3). The calvarium was then removed, as well as the pia, and the positions of the electrodes relative to the Rolandic fissure definitely determined. The illustration (Fig. 4), which is made from a photograph of the cadaver operation, shows that the points of excitation usually employed by us are sufficiently accurate as regards their relations to the central fissure. In Fig. 5 these points are represented diagrammatically on the exposed brain surface.

If observations upon the effect of faradization of the cortex are to be of any immediate value to the observer or of any subsequent value as a contribution to our knowledge of the distribution of the motor centres, they should be made with as much care and accuracy as one would employ in the performance of any delicate physiological investigation. In the first place, in order that no time be wasted, the whole matter should be prearranged. In our observations, for example, a scheme as above outlined is employed. Each point to be faradized is given a number or a letter; a blank form is pro-

vided containing these, so that at the operation the surgeon in dictating to the recorder the results of faradization does this with a number or letter which corresponds to a definite position with regard to the superior and posterior margins of the opening.

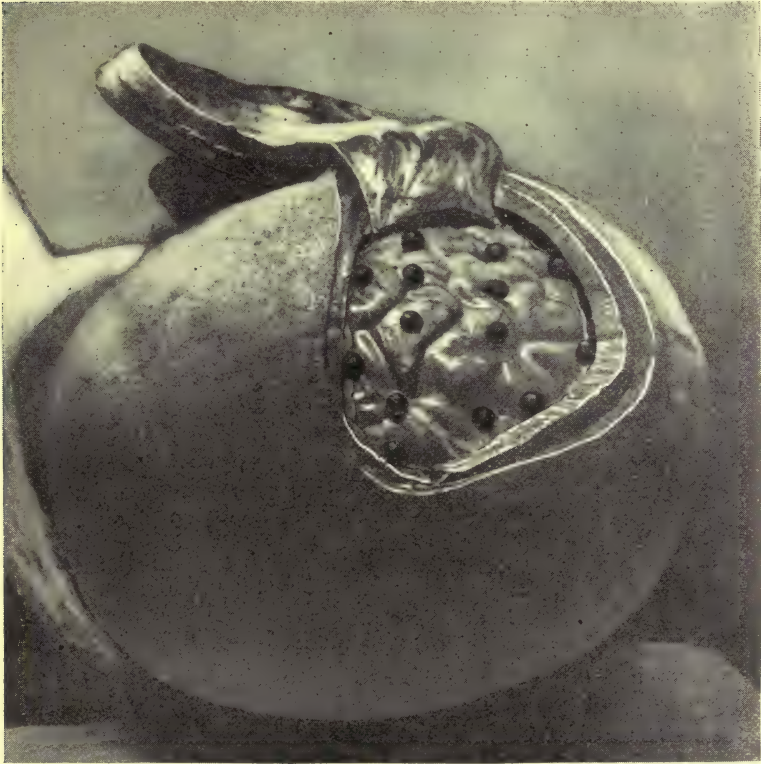

FIG. 4.—Reflected osteoplastic flap in cadaver operation showing the places of insertion of pins at points of selection for precentral and postcentral faradization.

If these points are decided upon before the operation, a series of observations can be made in less than five minutes, and usually in half this time.

It is important, furthermore, to observe certain details in

other particulars. One, for example, should test carefully the strength of the current before each application; one should begin always with a weak current, preferably rapidly interrupted. He should apply the current first to point No. 1 behind the central fissure, then without increase to point No. 2 in front of the fissure; if now at this second appli-

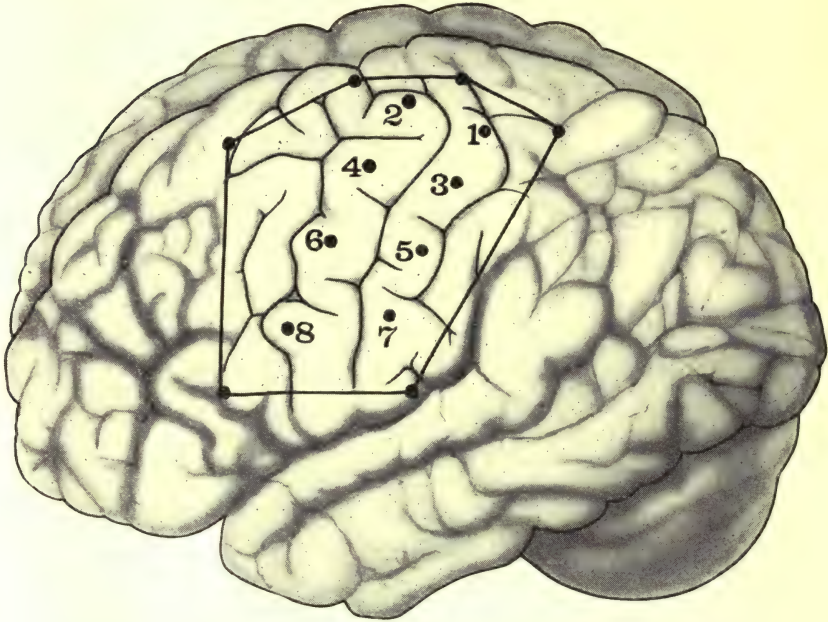


FIG. 5.—Drawing of the brain after calvarium and membranes were removed, showing the position of osteoplastic opening with reference to the fissures and gyres of the motor region. The numbers 1, 2, 3, 4, 5, 6, 7, and 8 indicate the preferable points for faradization of the cortex during the operation.

cation no response occurs, the current should be carefully increased before applying it to points Nos. 3 and 4. If no response is obtained, it should then be again increased and applied to points Nos. 5 and 6. As soon as a response in movement is obtained this strength of current should be used as a standard for the succeeding applications.

If too strong a current is employed it may be so diffused as to stimulate centres situated some distance from the point at which the electrode is applied. If too strong a current is applied to the postcentral fissure, the response may be due to diffusion of the current to the precentral region. If the observations of Grünbaum and Sherrington upon the ape are correct for man, a weaker current might give no response in the postcentral and a positive response in the precentral convolution.

The question of the diffusion of the electric current is one of great importance in deciding the situation of separate or isolated centres. It is well known to electricians that a galvanic or faradic current applied to one nerve distribution, as for instance that to the extensors of the forearm, in a case in which the muscles supplied by this nerve are paralyzed, will fail, owing to conditions of disease, to cause response in the muscles being investigated, whereas, the current diffused to the nerve supplying the flexors gives a very decided response; in other words, it is simply the question of extrapolar diffusion of currents more or less strong.

It was apparently evident that in some of the cases in which response was produced by applications behind the central fissure, as for instance Observation 5, this was the result of diffusion of the current.

A study of the records of the older cases of bipolar faradization which have been collected by Lamacq and the writers shows with but little doubt that in many of these cases the current was of such strength as to make it impossible to decide from its use the question of the precentral or postcentral position of the motor region.

It is important that the electrode should be applied always first behind the fissure before attempting to stimulate the region in front of it. If this order should be reversed and the precentral convolutions stimulated first with a current sufficiently strong to excite a response, and the postcentral afterward, it is quite possible that, though using a current

of the same strength, one might get a response from the post-central convolution, when no response would have been obtained had the electrode been applied first to this convolution. This we have noted in our own cases and have attributed it to the fact that a centre once stimulated to the point of reaction becomes so much more sensitive that it is affected by stimulation in regions adjacent to it.

Attention has been called recently by Sherrington, and Krause particularly, to the advantages of the unipolar over the bipolar method of faradization. With regard to this question of unipolar and bipolar faradization, it is of course well known that the earlier experiments in this country were nearly all bipolar, making use of Keen's bipolar electrode. These observations in some instances gave very satisfactory results. At the same time, on general principles, in the isolation of centres the unipolar application, if made under certain strict regulations, should give the more accurate results. Grünbaum and Sherrington and Krause used these unipolar applications in their well-known experiments on the brains of the anthropoids, the chimpanzee, orang-outang, gorilla, etc. In order that the best results can be obtained from unipolar faradization of the cortex, several matters should be kept clearly in view. In the first place, the electrode should be small. In our investigations a unipolar electrode, designed by one of us, Dr. Frazier, was used. This has been modified as the result of experience. In order that the pia and brain substance should not be punctured, the electrode should not be sharp. It should not be larger than the head of a pin. The instrument should be so handled that none of its conducting parts should come in contact with the dura.

The indifferent electrode should be at least four to six inches square. It should always be applied very carefully, so that all parts of it remain in contact with the skin during the entire application. It should be kept thoroughly saturated during the application with warm water or a hot salt solution. It should be placed carefully on one side of the mesal line,

and preferably on the side of the operation. Perhaps as convenient position as any with regard to the surgical procedures and etherization is on the buttock or thigh of the same side. It may be held by the weight of the patient, but, owing to the possible changes in position of the patient, it is preferable that an assistant should be directed to keep it in place.

If these precautions are observed and the rules which have been given above with regard to the method of successive applications to get a standard current are employed, we believe that it will be found that the unipolar will have advantages over the bipolar method. If carried out systematically and expeditiously, the applications are absolutely harmless and in no way detrimental to the interests of the patient.

#### CRANIOMETRIC LINES AND CRANIOCEREBRAL RELATIONS.

Reference has been made to the shape and size of the opening used for the exposure of the motor area. In outlining this flap, one must first determine the topical relations between the Rolandic and Sylvian fissures and the skull cap. For this purpose, one or the other of the methods of cranio-cerebral topography may be used. According to the age of the patient and to the sex and race, there may be some variation in the relation of the cerebral convolutions to the calvarium; so that no individual method has been found which is invariably accurate. In our experience, as already stated, the Anderson-Makins lines have given satisfaction. Of the relative merits of these lines with those of Krönlein, we are not prepared to speak, since with the latter we have had as yet no experience. Krönlein's topographical lines are constructed on the same fundamental principles as those of Anderson-Makins, in that the rules for their application eliminate "absolute values and replace them with relative values, which are in proportion to the size of the skull and

of the brain, and which vary accordingly in the individual case."

The Krönlein craniometer, a mechanical device constructed for the purpose of facilitating the application of the Krönlein method, has been spoken of so highly by those who have had experience with it that Dr. Frazier is importing one for his own use and he hopes to have an early opportunity to test its accuracy.

Horsley, Keen, and other surgeons, especially in this country and in Great Britain, have used chiefly the methods of Thane and Hare, with the cyrtometer of Wilson, or the fissure meter of Horsley, in fixing the position of the central fissure, and therefore of the motor region. While the results with these methods seem, from the recorded cases, to have been accurate, we have not resorted to them because the Anderson-Makins method, with its modification, has proved satisfactory in the cases in which we have applied it.

Having established and marked upon the scalp lines corresponding to the central fissure and Sylvian fissure, we map out the flap for exposure of the motor cortex, so that at least two-thirds of the opening will lie in front and only one-third posterior to the Rolandic fissure, the flap extending from the Sylvian fissure to within one-half inch of the median line. In addition to this, prior to the operation, a forward central extension of the opening should be outlined on the scalp to cover what is believed to be the most anterior portion of the area for the eyes and head. If the centres for the eyes and head are found not to be completely exposed, the overlying bone can be removed in this forward direction, as outlined, with the rongeur. The usual flap of three and one-half or four inches will, in most cases, however, be sufficient to uncover all that is necessary of the region for movements of the eyes and head. If the opening in the skull, which is outlined with the view of making its superior border one-half inch from the mesal line, is found not to uncover the centres for the trunk and upper extremity, the rongeur forceps can



be used to extend the opening to the longitudinal fissure, care being taken, of course, with regard to the longitudinal sinus.

In looking over the results of our earlier operations, we found that when the flap was equally divided by the central fissure it was necessary occasionally to enlarge the opening forward, in order to fully expose the lesion. Since the more recent plan of making the opening two-thirds in front and one-third behind the fissure has been adopted, it has never been necessary to enlarge the opening backward. The clinical data, taken together with such evidence as we have accumulated from faradization of the cortex, lead us to believe that not only have we been justified in advancing the position of the flap so far forward, but that in the future, in all probability, it will be unnecessary to uncover even one-third of the cortex behind the central fissure for the exposure of motor cortical lesions. Probably a relation of three-fourths to one-fourth will be found to be a suitable proportion.

Presuming, as we believe, that the motor region is entirely or almost entirely precentral, one-third or one-fourth of the osteoplastic opening should be posterior not only for purposes of freer exploration, but also because of the fact that the central fissure at about the junction of its middle and lower thirds bends backward slightly, constituting the genu of the fissure. Unless one-third or one-fourth of the opening is designed to be behind the fissure, the posterior margin of the flap might encroach upon the lower third of the fissure.







81329  
Mills et al  
Tumors of the Cerebrum.

med.  
Lett. New

Author

Title

UNIVERSITY OF TORONTO  
LIBRARY

Do not  
remove  
the card  
from this  
Pocket.

Acme Library Card Pocket  
Under Pat. "Ref. Index File."  
Made by LIBRARY BUREAU

